

PATIENT

Penelope Filliter

SPECIES

Feline

BREED

DSH

SEX

Spayed Female

AGE

5 Years

WEIGHT

~2.5 kg

INTERPRETED BY

Greg Kuhlman, DVM,
 DACVIM (SAIM)

IMAGING PERFORMED BY

Crystal Hill

HOSPITAL NAME

Hawkins Animal
 Hospital

REFERRING VET

Dr. Hawkins

INVOICE

16453

DATE

06/08/26

PRESENTING CLINICAL SIGNS

Supplemental images only - no charge. Assess bladder now that not empty.

Abnormal PE/Chem/CBC/UA Results: Please see attached previous report

ULTRASONOGRAPHIC EXAMINATION OF THE ABDOMEN

Urinary System

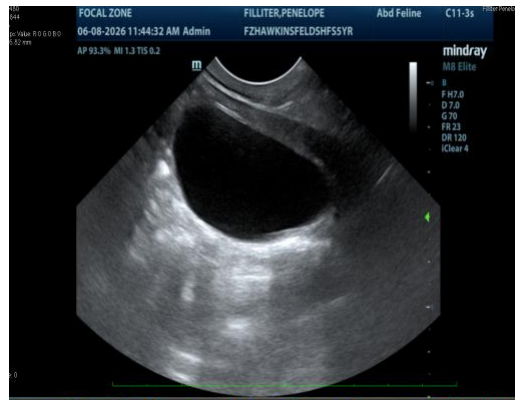
Urinary bladder is adequately distended. It has a normal uniform wall thickness. Contents include primarily anechoic fluid with occasional echogenic non-shadowing debris, most consistent with incidental suspended lipid in a cat, possibly combined with exfoliated cells, mucous and/or small blood clots. Both sterile inflammation as well as urinary tract infection can also present with echogenic debris. No masses or definitive cystoliths are observed. The trigone and visible pelvic urethra are normal in thickness with a smooth mucosal surface.

ULTRASONOGRAPHIC FINDINGS

- Mild urinary bladder debris.

INTERPRETATION OF THE FINDINGS & FURTHER RECOMMENDATIONS

The bladder overall appears normal.



The information and recommendations provided are based on the images presented by the referring veterinarian/sonographer. No evaluation can be communicated regarding pathology that was not visible in the image/video clips provided.

Thank you for this referral. If the clinical or image interpretation does not parallel your findings or if I can be of any further assistance, please contact me.

Greg Kuhlman, DVM, DACVIM (SAIM)
 Veterinary Internal Medicine Specialist
info@SonoPath.com