



**PATIENT**

Nala Gonzalez

**SPECIES**

Feline

**BREED**

DSH

**SEX**

Spayed Female

**AGE**

9 Years 9 Months

**WEIGHT**

9.6 lbs

**INTERPRETED BY**

Greg Kuhlman, DVM,  
DACVIM (SAIM)

**IMAGING PERFORMED BY**

Kerri Becker

**HOSPITAL NAME**

Packanack Animal  
Hospital

**REFERRING VET**

Dr. Mahoney

**INVOICE**

75726

**DATE**

6/5/26

**PRESENTING CLINICAL SIGNS**

Pre anesthetic work up/ staging after cutaneous lymphoma dx w/ dermatitis L lateral thorax

**ULTRASONOGRAPHIC EXAMINATION OF THE ABDOMEN**

**Urinary System**

The bladder is moderately distended with anechoic urine. No uroliths are seen. The bladder wall is normal in appearance and thickness. No masses are seen.

The right kidney presents normal size (3.6 cm) with normal shape and architecture. Normal corticomedullary distinction. No pyelectasia, ureteral dilation or nephrolithiasis.

The left kidney presents normal size (3.3 cm) with normal shape and architecture. Normal corticomedullary distinction. No pyelectasia, ureteral dilation or nephrolithiasis.

**Adrenal Glands**

The right adrenal gland presents normal shape and homogenous parenchyma. The phrenic vasculature is unremarkable. The right adrenal gland measured 2.9 mm in width.

The left adrenal gland presents normal shape and homogenous parenchyma. The phrenic vasculature is unremarkable. The left adrenal gland measured 3.4 mm in width.

**Spleen**

The spleen is normal in size, shape, margination and echogenicity. No masses are seen.

**Liver**

The liver presents normal size and shape with smooth lobar margins. The parenchyma has normal echogenicity with normal echotexture. No focal lesions are seen. Intrahepatic bile ducts are normal. Normal vascular pattern.

Gallbladder is moderately distended with anechoic bile as well as suspended and gravity dependent echogenic debris. The wall is smooth without visible thickening. There is no evidence of cystic or CBD dilation. There is no evidence of effusion or inflammation. The debris is likely incidental.

**Gastrointestinal**

The stomach and intestines have normal wall layering and thickness. Colon contains normal contents with normal wall thickness.

**Pancreas**

The visible pancreas is normal in size with normal echogenic parenchyma and surrounded by normal peri-pancreatic mesentery.

**Free Abdomen**

There are no enlarged abdominal lymph nodes seen on this exam. No free abdominal fluid is seen.



**PATIENT**

Nala Gonzalez

**SPECIES**

Feline

**BREED**

DSH

**SEX**

Spayed Female

**AGE**

9 Years 9 Months

**WEIGHT**

9.6 lbs

**INTERPRETED BY**

Greg Kuhlman, DVM,  
DACVIM (SAIM)

**IMAGING PERFORMED BY**

Kerri Becker

**HOSPITAL NAME**

Packanack Animal  
Hospital

**REFERRING VET**

Dr. Mahoney

**INVOICE**

75726

**DATE**

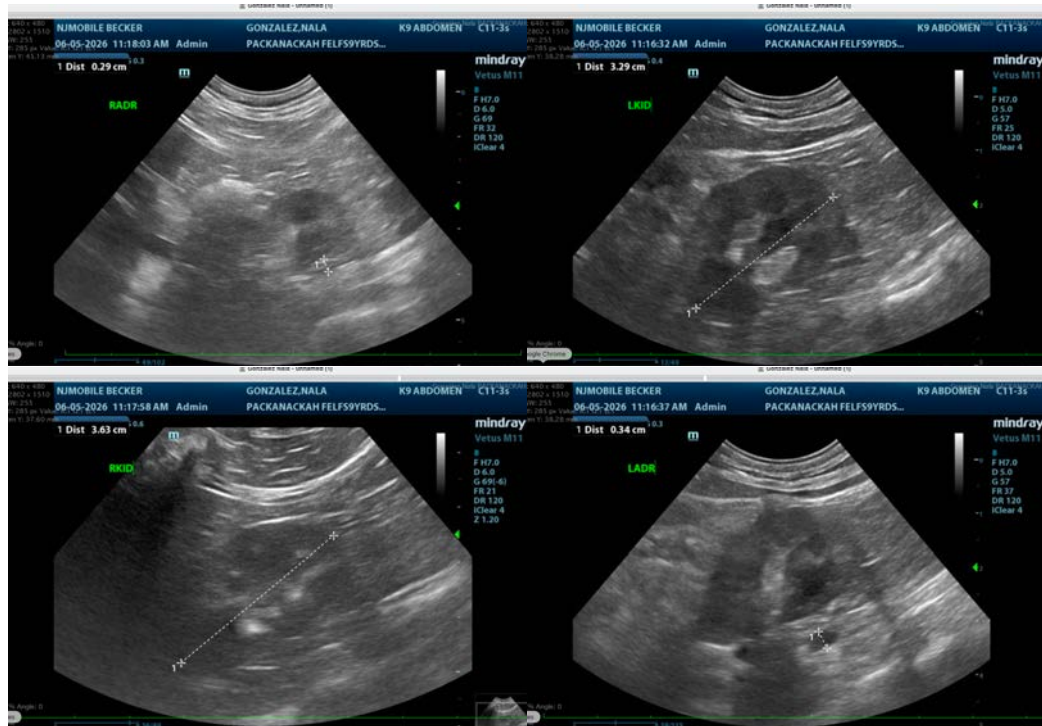
6/5/26

**ULTRASONOGRAPHIC FINDINGS**

- Gallbladder debris, likely incidental.

**INTERPRETATION OF THE FINDINGS & FURTHER RECOMMENDATIONS**

This is an apparently normal abdominal ultrasound. No evidence of metastatic lymphoma seen on this exam.



The information and recommendations provided are based on the images presented by the referring veterinarian/sonographer. No evaluation can be communicated regarding pathology that was not visible in the image/video clips provided.

Thank you for this referral. If the clinical or image interpretation does not parallel your findings or if I can be of any further assistance please contact me.

**Greg Kuhlman, DVM, DACVIM (SAIM)**

Veterinary Internal Medicine Specialist  
[info@SonoPath.com](mailto:info@SonoPath.com)