



## PATIENT

Charlie Moski

## SPECIES

Canine

## BREED

Maltese x

## SEX

Neutered Male

## AGE

10.5 Years

## WEIGHT

5.8 kg

## INTERPRETED BY

Greg Kuhlman, DVM,  
DACVIM (SAIM)

## IMAGING PERFORMED BY

Carlie Koltek, RVT

## HOSPITAL NAME

Tuxedo Animal  
Hospital

## REFERRING VET

Dr. Fredette

## INVOICE

75738

## DATE

6/5/26

## PRESENTING CLINICAL SIGNS

On routine physical exam noted significant suspect organomegaly suspecting spleen, on radiographs also noted significant distension of the spleen, brief scan in clinic did not show obvious mass like effect on the spleen.

## ULTRASONOGRAPHIC EXAMINATION OF THE ABDOMEN

### *Urinary System*

The bladder is moderately distended with anechoic urine. No uroliths are seen. The bladder wall is normal in appearance and thickness. No masses are seen.

The prostate appears normal and measures 8.8 mm in width.

The right kidney presents normal size (3.6 cm) with normal shape and architecture. Normal corticomedullary distinction. No pyelectasia, ureteral dilation or nephrolithiasis.

The left kidney presents normal size (4.0 cm) with normal shape and architecture. Normal corticomedullary distinction. No pyelectasia, ureteral dilation or nephrolithiasis.

### *Adrenal Glands*

The right adrenal gland presents normal shape and homogenous parenchyma. The phrenic vasculature is unremarkable. The caudal pole measures 6.1 mm.

The left adrenal gland presents normal shape and homogenous parenchyma. The phrenic vasculature is unremarkable. The cranial pole measures 5.4 mm and the caudal pole measures 6.0 mm.

### *Spleen*

Diffusely, the spleen is enlarged, measuring 1.2 cm in width, with normal echogenicity and a normal echotexture. In the body of the spleen there is a non-capsule displacing hypoechoic lesion that measures 5.0 mm x 2.1 mm in size.

### *Liver*

The liver presents normal size and shape with smooth lobar margins. The parenchyma has normal echogenicity with normal echotexture. No focal lesions are seen. Intrahepatic bile ducts are normal. Normal vascular pattern.

Gallbladder is moderately distended with anechoic bile as well as suspended and gravity dependent echogenic debris. The wall is smooth without visible thickening. There is no evidence of cystic or CBD dilation. There is no evidence of effusion or inflammation.

### *Gastrointestinal*

The stomach and intestines have normal wall layering and thickness. Colon contains normal contents with normal wall thickness.

### *Pancreas*

The visible pancreas is normal in size with normal echogenic parenchyma and surrounded by normal peri-pancreatic mesentery.



**PATIENT**

Charlie Moski

**SPECIES**

Canine

**BREED**

Maltese x

**SEX**

Neutered Male

**AGE**

10.5 Years

**WEIGHT**

5.8 kg

**INTERPRETED BY**

Greg Kuhlman, DVM,  
DACVIM (SAIM)

**IMAGING PERFORMED BY**

Carlie Koltek, RVT

**HOSPITAL NAME**

Tuxedo Animal  
Hospital

**REFERRING VET**

Dr. Fredette

**INVOICE**

75738

**DATE**

6/5/26

**Free Abdomen**

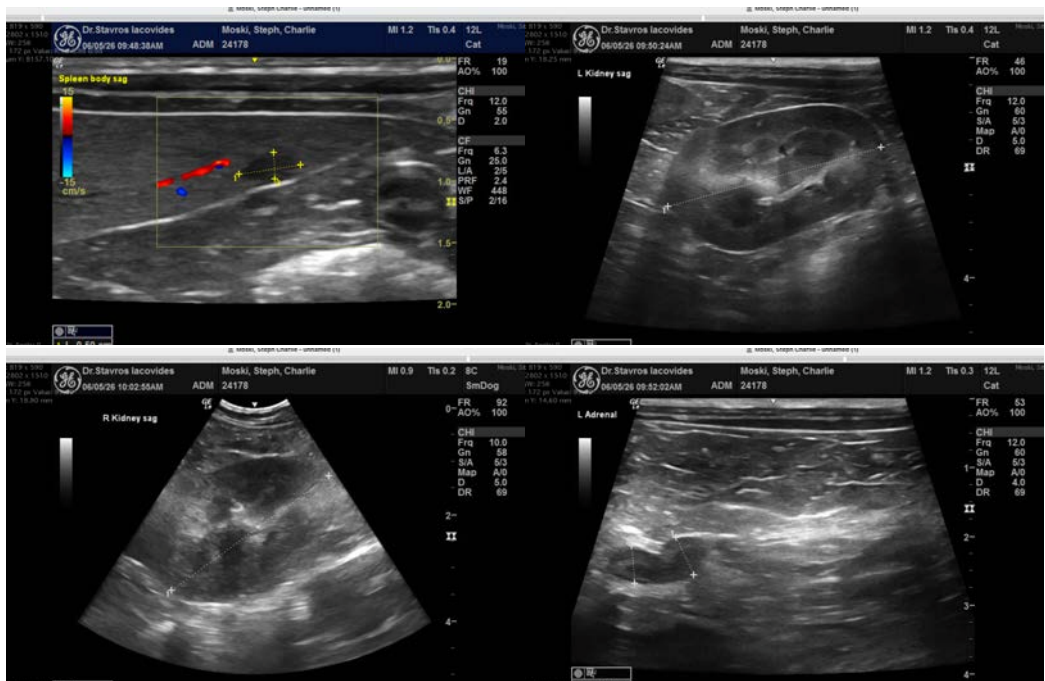
There are no enlarged abdominal lymph nodes seen on this exam. No free abdominal fluid is seen.

**ULTRASONOGRAPHIC FINDINGS**

- Enlarged spleen with hypoechoic splenic lesion.
- Gallbladder debris, clinically incidental.

**INTERPRETATION OF THE FINDINGS & FURTHER RECOMMENDATIONS**

The hypoechoic splenic lesion most likely represents benign extramedullary hematopoiesis. The splenic enlargement may be a normal variation. However, there is a possibility of infiltrative disease such as lymphoma or mast cell disease, or less likely infectious disease such as bartonellosis. Recommend fine needle aspirate of the spleen with submission for cytology to characterize splenic changes further.





## PATIENT

Charlie Moski

## SPECIES

Canine

## BREED

Maltese x

## SEX

Neutered Male

## AGE

10.5 Years

## WEIGHT

5.8 kg

## INTERPRETED BY

Greg Kuhlman, DVM,  
DACVIM (SAIM)

## IMAGING PERFORMED BY

Carlie Koltek, RVT

## HOSPITAL NAME

Tuxedo Animal  
Hospital

## REFERRING VET

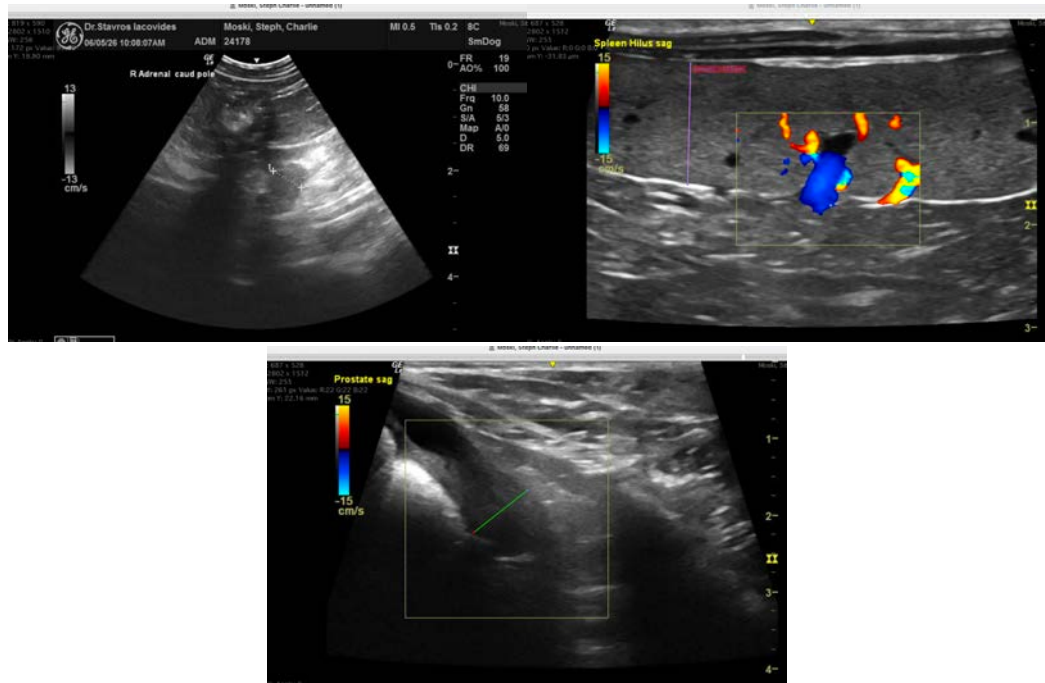
Dr. Fredette

## INVOICE

75738

## DATE

6/5/26



The information and recommendations provided are based on the images presented by the referring veterinarian/sonographer. No evaluation can be communicated regarding pathology that was not visible in the image/video clips provided.

Thank you for this referral. If the clinical or image interpretation does not parallel your findings or if I can be of any further assistance please contact me.

Greg Kuhlman, DVM, DACVIM (SAIM)

Veterinary Internal Medicine Specialist

[info@SonoPath.com](mailto:info@SonoPath.com)