



**PATIENT PRESENTING CLINICAL SIGNS**

Delilah Lister Vocal , weight loss, +/- vomiting.

**SPECIES** Abnormal PE/Chem/CBC/UA Results: ABNORMAL Labwork Values May 9/26 Lymphocytes 7.94 (0.65 - 6.86 x10<sup>9</sup>/L) Platelets 455 (100 - 440 x10<sup>9</sup>/L) Calcium 2.9 (2.2 - 2.7 mmol/L) May 28th Ionized Calcium 1.54 (1.00 - 1.40 mmol/L) Parathyroid Hormone a <0.50 (0.70 - 3.40 pmol/L)

Feline

**BREED ULTRASONOGRAPHIC EXAMINATION OF THE ABDOMEN**

DSH **Urinary System**

**SEX** The bladder is moderately distended with anechoic urine. No uroliths are seen. The bladder wall is normal in appearance and thickness. No masses are seen.

Spayed Female

The right kidney presents normal size (3.3 cm) with normal shape and architecture. Normal corticomedullary distinction. No pyelectasia, ureteral dilation or nephrolithiasis.

**AGE**

5 Years

The left kidney presents normal size (3.4 cm) with normal shape and architecture. Normal corticomedullary distinction. No pyelectasia, ureteral dilation or nephrolithiasis.

**WEIGHT**

9.81 lbs

**Adrenal Glands**

The right adrenal gland presents normal shape and homogenous parenchyma. The phrenic vasculature is unremarkable. The right adrenal gland measures 3.0 mm in width.

**INTERPRETED BY**

Greg Kuhlman, DVM, DACVIM (SAIM)

The left adrenal gland presents normal shape and homogenous parenchyma. The phrenic vasculature is unremarkable. The left adrenal gland measures 2.7 mm in width.

**Spleen**

The spleen is normal in size, shape, margination and echogenicity. No masses are seen.

**IMAGING PERFORMED BY**

Kelly Reschny

**Liver**

The liver presents normal size and shape with smooth lobar margins. The parenchyma has normal echogenicity with normal echotexture. No focal lesions are seen. Intrahepatic bile ducts are normal. Normal vascular pattern.

**HOSPITAL NAME**

Hillview Veterinary Clinic

The gallbladder presents normal size with anechoic contents. Normal gallbladder wall. No evidence of bile duct distention or obstruction.

**REFERRING VET**

Dr. E. Stevenson

**Gastrointestinal**

**INVOICE**

75682

The stomach and intestines have normal wall layering and thickness. Small bowel wall measures 2.2 mm in width. Colon contains normal contents with normal wall thickness.

**DATE**

6/4/26

**Pancreas**

The visible pancreas is normal in size with normal echogenic parenchyma and surrounded by normal peripancreatic mesentery.



**PATIENT**

**Free Abdomen**

Delilah Lister

There are no enlarged abdominal lymph nodes seen on this exam. No free abdominal fluid is seen.

**SPECIES**

**ULTRASONOGRAPHIC FINDINGS**

Feline

- Normal abdomen.

**BREED**

**INTERPRETATION OF THE FINDINGS & FURTHER RECOMMENDATIONS**

DSH

No obvious cause for the patient's weight loss and vomiting seen on this exam. Recommend submitting a GI panel including a cPLI, TLI, cobalamin and folate to screen the patient for possible occult pancreatic disease or chronic enteropathy. If either of these diseases are identified, then recommend a diet trial with even a novel protein diet or a hydrolyzed diet. If a chronic enteropathy is determined to be present and the patient fails a diet trial, recommend GI biopsies either surgically or endoscopically.

**SEX**

Spayed Female

No cause for the patient's lymphocytosis seen on this exam, nor the mild hypercalcemia. I suspect the hypercalcemia is most likely idiopathic hypercalcemia, as that is the most common cause in a feline. In terms of the elevated lymphocytes, recommend additional screening. If not recently performed, recommend FELV/FIV testing. 3-view chest radiographs are recommended to determine if any possible disease process in the chest may be responsible for the lymphocytosis. Also recommend submitting bartonella testing to North Carolina State University to rule out this infectious disease. Also consider toxoplasmosis IFA testing, measuring both IGG and IGM.

**AGE**

5 Years

**WEIGHT**

9.81 lbs

**INTERPRETED BY**

Greg Kuhlman, DVM,  
DACVIM (SAIM)

**IMAGING PERFORMED BY**

Kelly Reschny

**HOSPITAL NAME**

Hillview Veterinary  
Clinic

**REFERRING VET**

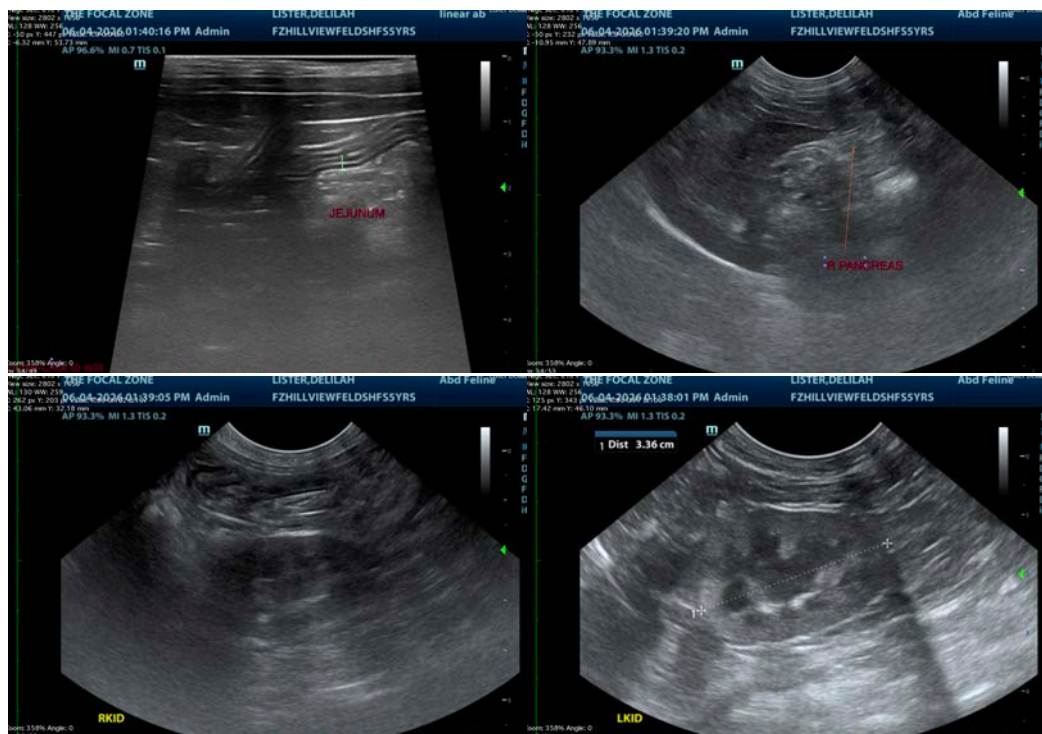
Dr. E. Stevenson

**INVOICE**

75682

**DATE**

6/4/26





**PATIENT**

Delilah Lister

**SPECIES**

Feline

**BREED**

DSH

**SEX**

Spayed Female

**AGE**

5 Years

**WEIGHT**

9.81 lbs

**INTERPRETED BY**

Greg Kuhlman, DVM,  
 DACVIM (SAIM)

**IMAGING PERFORMED BY**

Kelly Reschny

**HOSPITAL NAME**

Hillview Veterinary  
 Clinic

**REFERRING VET**

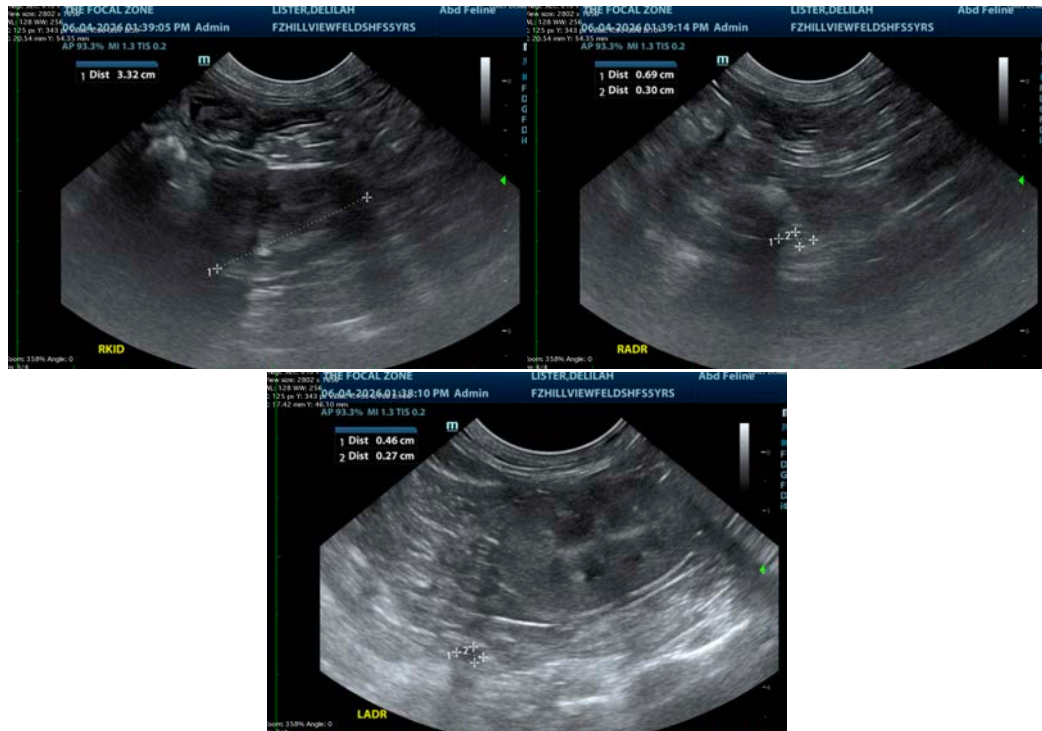
Dr. E. Stevenson

**INVOICE**

75682

**DATE**

6/4/26



The information and recommendations provided are based on the images presented by the referring veterinarian/sonographer. No evaluation can be communicated regarding pathology that was not visible in the image/video clips provided.

Thank you for this referral. If the clinical or image interpretation does not parallel your findings or if I can be of any further assistance please contact me.

**Greg Kuhlman, DVM, DACVIM (SAIM)**

Veterinary Internal Medicine Specialist  
[info@SonoPath.com](mailto:info@SonoPath.com)