



PATIENT

Clove Sanchez

SPECIES

Feline

BREED

Siamese

SEX

Spayed Female

AGE

10 Years

WEIGHT

11.18

INTERPRETED BY

Greg Kuhlman, DVM,
DACVIM (SAIM)

IMAGING PERFORMED BY

Sativa Romero

HOSPITAL NAME

Petroglyph Animal
Hospital

REFERRING VET

Dr. Cassidy Stone

INVOICE

75684

DATE

6/4/26

PRESENTING CLINICAL SIGNS

Waxing and waning vomiting -- when P vomits, has 4-5 bouts with each episode of vomiting. Still interested in eating. Mildly more lethargic. Abnormal PE/Chem/CBC/UA Results: WNL

ULTRASONOGRAPHIC EXAMINATION OF THE ABDOMEN

Urinary System

The bladder is moderately distended with anechoic urine. No uroliths are seen. The bladder wall is normal in appearance and thickness. No masses are seen.

The right kidney presents normal size (3.3 cm) with normal shape and architecture. Normal corticomedullary distinction. No pyelectasia, ureteral dilation or nephrolithiasis.

The left kidney measured at the low end of normal for size, measuring 2.9 cm. Normal corticomedullary distinction. No pyelectasia, ureteral dilation or nephrolithiasis.

Adrenal Glands

The adrenal glands were not clearly visualized on this exam.

Spleen

The spleen is normal in size, shape, margination and echogenicity. No masses are seen.

Liver

The liver presents normal size and shape with smooth lobar margins. The parenchyma has normal echogenicity with normal echotexture. No focal lesions are seen. Intrahepatic bile ducts are normal. Normal vascular pattern.

The gallbladder presents normal size with anechoic contents. Normal gallbladder wall. No evidence of bile duct distention or obstruction.

Gastrointestinal

Diffusely, the gastric wall is thickened at 5.8 mm in width. There is a mild amount of retained fluid within the stomach.

The small intestines have normal wall layering and thickness. Colon contains normal contents with normal wall thickness.

Pancreas

The area of the pancreas is seen, no pathology noted.

Free Abdomen

There are no enlarged abdominal lymph nodes seen on this exam. No free abdominal fluid is seen.

ULTRASONOGRAPHIC FINDINGS

- Thickened gastric wall, unremarkable abdomen otherwise.



PATIENT

Clove Sanchez

SPECIES

Feline

BREED

Siamese

SEX

Spayed Female

AGE

10 Years

WEIGHT

11.18

INTERPRETED BY

Greg Kuhlman, DVM,
DACVIM (SAIM)

IMAGING PERFORMED BY

Sativa Romero

HOSPITAL NAME

Petroglyph Animal
Hospital

REFERRING VET

Dr. Cassidy Stone

INVOICE

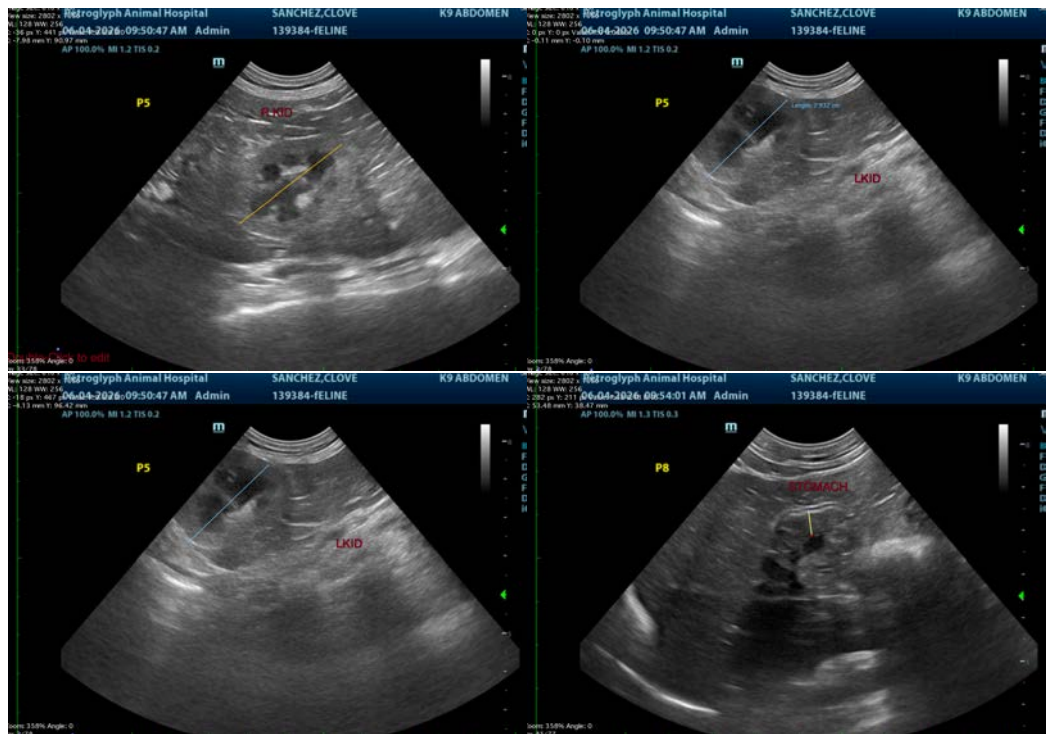
75684

DATE

6/4/26

INTERPRETATION OF THE FINDINGS & FURTHER RECOMMENDATIONS

It appears the patient has mild diffuse gastritis of unknown cause. Consider inflammatory disease as a possibility such as inflammatory bowel disease, less likely small cell lymphoma or mast cell disease. Infectious etiology is unlikely. Metabolic etiology is also unlikely given the reported normal lab work. Recommend treating patient supportively with antiemetic and prokinetic medications. If patient fails supportive care and continues to have episodes of vomiting, then recommend diet trial with either a novel protein diet or hydrolyzed diet for 2-4 weeks. If patient fails diet trial, then gastric biopsies either surgically or endoscopically (endoscopically preferred as they are minimally invasive).



The information and recommendations provided are based on the images presented by the referring veterinarian/sonographer. No evaluation can be communicated regarding pathology that was not visible in the image/video clips provided.

Thank you for this referral. If the clinical or image interpretation does not parallel your findings or if I can be of any further assistance please contact me.

Greg Kuhlman, DVM, DACVIM (SAIM)

Veterinary Internal Medicine Specialist
info@SonoPath.com