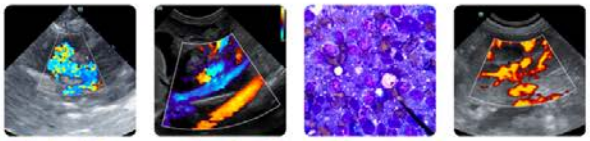

PATIENT
Bobo McMaster

SPECIES
Canine

BREED
Mixed

SEX
Neutered Male

AGE
14 Years

WEIGHT
14.5 lbs

INTERPRETED BY
Greg Kuhlman, DVM, DACVIM (SAIM)

IMAGING PERFORMED BY
Joan Kula Gramazio

HOSPITAL NAME
Narrowsburg Veterinary

REFERRING VET
Dr. Joan Kula Gramazio

INVOICE
75694

DATE
6/4/26

PRESENTING CLINICAL SIGNS

Blood work is indicating an increase in liver values, no other issues noted
Abnormal PE/Chem/CBC/UA Results: ALT (SGPT) 188 12-118 IU/L ALK PHOS 1089 5-131 IU/L

ULTRASONOGRAPHIC EXAMINATION OF THE ABDOMEN

Urinary System

The bladder is moderately distended with anechoic urine. No uroliths are seen. The bladder wall is normal in appearance and thickness. No masses are seen.

Kidneys are overall normal in size and shape with smooth peripheral margination. A normal 1:3 cortex to medulla ratio is maintained. The medulla and cortices are uniform in texture with some mild increased cortical echogenicity and mild loss of corticomedullary distinction, expected in this age patient. There is no evidence of pyelectasia, mineral or infarcts observed. Left kidney measured 4.0 cm. Right kidney measured 3.9 cm.

Adrenal Glands

The right adrenal gland presents normal shape and homogenous parenchyma. The phrenic vasculature is unremarkable. The cranial pole measures 6.0 mm and the caudal pole measures 3.4 mm.

The left adrenal gland presents normal shape and homogenous parenchyma. The phrenic vasculature is unremarkable. The cranial pole measures 4.5 mm and the caudal pole measures 4.1 mm.

Spleen

The spleen is normal in size, shape, margination and echogenicity. No masses are seen.

Liver

Liver is subjectively enlarged (swollen contour) without disruption of architecture. It has a normal homogenous echotexture. Parenchyma is diffusely hyperechoic characterized by less prominent than normal portal vein walls and increased echogenicity relative to the spleen and falciform fat. No focal lesions are observed. Visible vasculature and biliary tree appear normal without distension or congestion.

The gallbladder contains a moderate amount of aggregated debris. No mucocele seen. Normal gallbladder wall. No evidence of bile duct distention or obstruction.

Gastrointestinal

The stomach and intestines have normal wall layering and thickness. Colon contains normal contents with normal wall thickness.

Pancreas

The visible pancreas is normal in size with normal echogenic parenchyma and surrounded by normal peri-pancreatic mesentery.

Free Abdomen

There are no enlarged abdominal lymph nodes seen on this exam. No free abdominal fluid is seen.

PATIENT

Bobo McMaster

SPECIES

Canine

BREED

Mixed

SEX

Neutered Male

AGE

14 Years

WEIGHT

14.5 lbs

INTERPRETED BY

Greg Kuhlman, DVM, DACVIM (SAIM)

IMAGING PERFORMED BY

Joan Kula Gramazio

HOSPITAL NAME

Narrowsburg Veterinary

REFERRING VET

Dr. Joan Kula Gramazio

INVOICE

75694

DATE

6/4/26

ULTRASONOGRAPHIC FINDINGS

- Age related renal changes.
- Hyperechoic hepatomegaly.
- Moderate amount of aggregated gallbladder debris.

INTERPRETATION OF THE FINDINGS & FURTHER RECOMMENDATIONS

The patient appears to have a benign vacuolar hepatopathy. Recommend screening for secondary causes for liver enzyme elevations and appearance of the liver, including screening for hyperadrenocorticism with a urine cortisol to creatinine ratio. If elevated, a low-dose Dexamethasone suppression test would be indicated. If hyperadrenocorticism is ruled out, screen for hypertriglyceridemia, hypothyroidism, and occult pancreatic or occult GI disease. If a secondary cause is ruled out as a cause of the liver enzyme elevations and the appearance of the liver, recommend serial monitoring. If enzyme elevations increase over time, consider a liver biopsy.

The debris within the gallbladder may be causing mild cholestasis, contributing to elevated liver values and appearance of liver. Recommend starting Ursodiol at 15 mg/kg by mouth split into two daily doses, rechecking the appearance of the gallbladder in approximately two months via ultrasound, and recheck liver values.

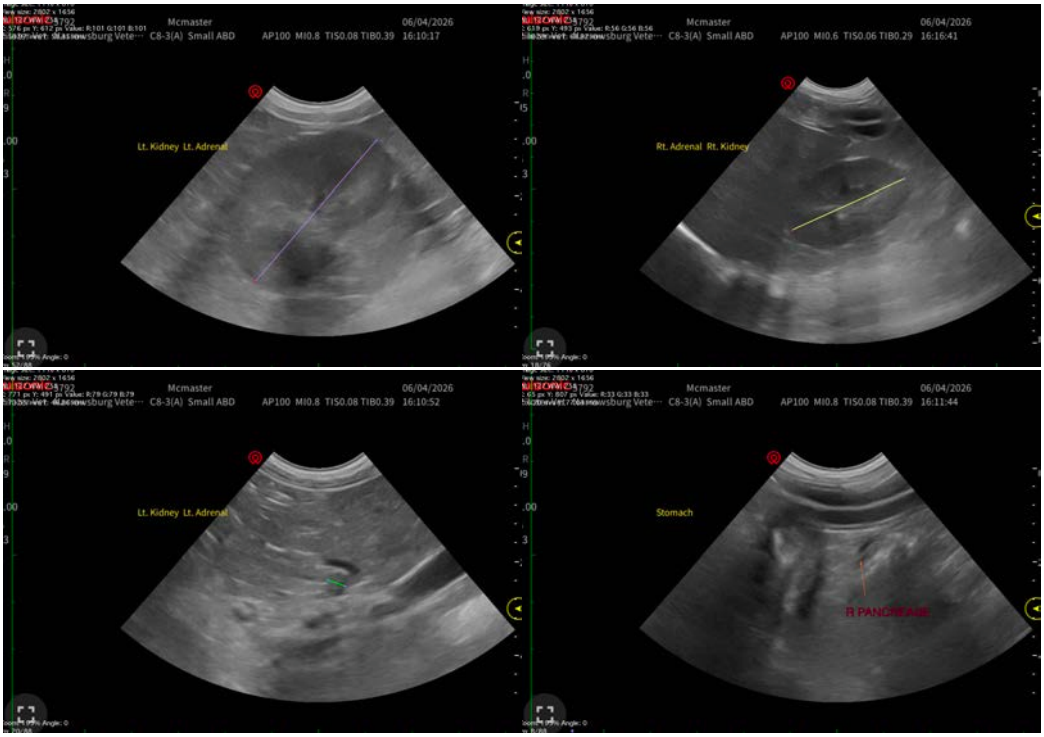

SonoPath
FOSTERING THE ART OF VETERINARY MEDICINE™

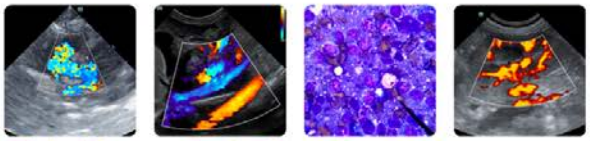

Clinical Sonography & Telecytology
Educational Teleconsultation Services™

SonoPath.com info@sonopath.com 1.800.838.4268

PATIENT

Bobo McMaster

SPECIES

Canine

BREED

Mixed

SEX

Neutered Male

AGE

14 Years

WEIGHT

14.5 lbs

INTERPRETED BY

Greg Kuhlman, DVM, DACVIM (SAIM)

IMAGING PERFORMED BY

Joan Kula Gramazio

HOSPITAL NAME

Narrowsburg Veterinary

REFERRING VET

Dr. Joan Kula Gramazio

INVOICE

75694

DATE

6/4/26

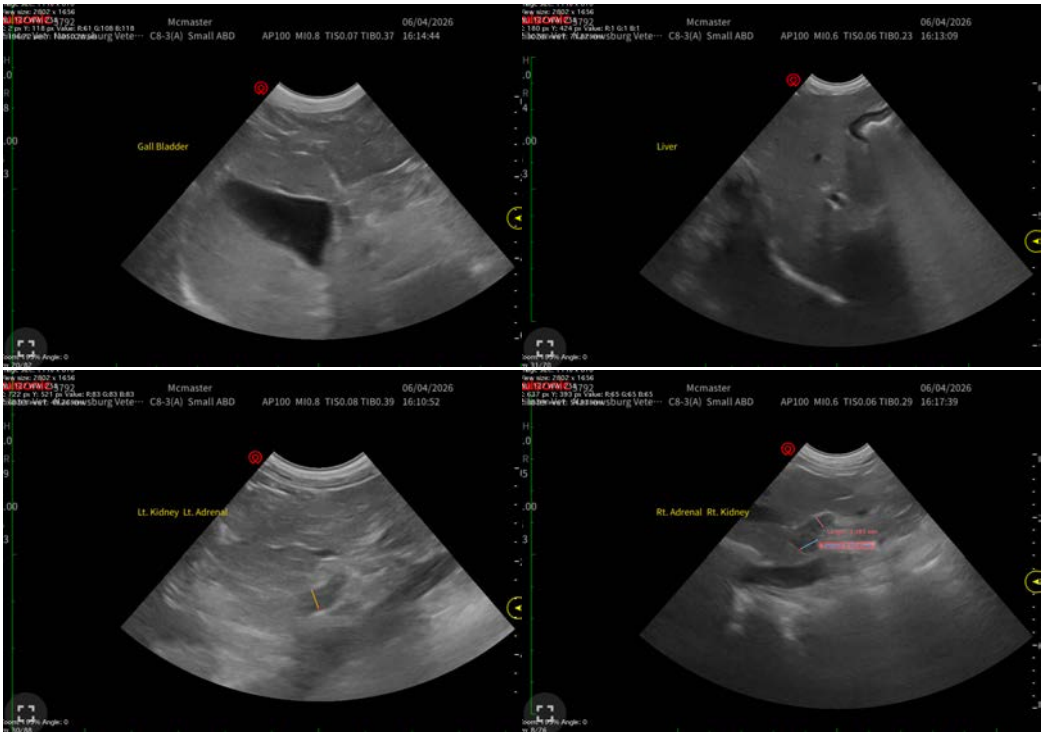

The information and recommendations provided are based on the images presented by the referring veterinarian/sonographer. No evaluation can be communicated regarding pathology that was not visible in the image/video clips provided.

Thank you for this referral. If the clinical or image interpretation does not parallel your findings or if I can be of any further assistance please contact me.

Greg Kuhlman, DVM, DACVIM (SAIM)

Veterinary Internal Medicine Specialist
info@SonoPath.com