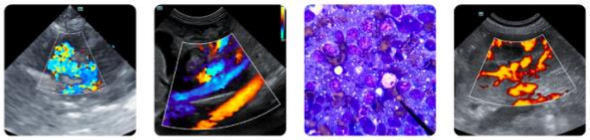

PATIENT
Sadie Deurbrouck

SPECIES
Canine

BREED
Dachshund

SEX
Spayed Female

AGE
16 Years

WEIGHT
5.5 kg

INTERPRETED BY
Greg Kuhlman, DVM, DACVIM (SAIM)

IMAGING PERFORMED BY
Carlie Koltek, RVT

HOSPITAL NAME
Tuxedo Animal Hospital

REFERRING VET
Dr. Gemriff Capao

INVOICE
16594

DATE
05/29/26

PRESENTING CLINICAL SIGNS

Diagnosed with Diabetes mellitus and mammary tumors. February 2026 Hypoglycemia and seizures. March 2025: Right caudal mastectomy and OHE performed. Problem list: Seizures and uncontrolled diabetes. Blood glucose results of the Freestyle Libre showed wide swings in blood glucose. Current meds: Caninsulin 2 units BID. Rec Abdominal U/S to see if there is any tumor in the pancreas? adrenal? abdominal tumor?

Thoracic Ausc: Mild murmur (2/6) Abdominal palpation: NSF PE: Eyes: Mature cataracts Multiple mammary tumors on the contralateral side of the mastectomy site March 2025 Histopathology results: Mammary glands: Extraskeletal osteosarcoma and multiple benign mixed mammary tumors. Thoracic rads 2026: Cardiac silhouette appears to be normal in size. An alveolo-interstitial pattern that is suspicious of a pulmonary tumor.

ULTRASONOGRAPHIC EXAMINATION OF THE ABDOMEN

Urinary System

The bladder is moderately distended with anechoic urine. No uroliths are seen. The bladder wall is normal in appearance and thickness. No masses are seen.

The left kidney presents normal size with normal shape and architecture. Normal corticomedullary distinction. No pyelectasia, ureteral dilation or nephrolithiasis. The left kidney measured 4.3 cm in length.

The right kidney presents mildly irregular in shape with normal corticomedullary distinction. No pyelectasia, ureteral dilation or nephrolithiasis. The right kidney measured approximately 3.8 cm in length.

Adrenal Glands

The left adrenal gland presents normal shape and homogenous parenchyma. The phrenic vasculature is unremarkable. The left adrenal gland measures 5.3 mm at the caudal pole and 5.2 mm at the cranial pole.

The right adrenal gland presents normal shape and homogenous parenchyma. The phrenic vasculature is unremarkable. The cranial pole measures 5.5 mm and the caudal pole measures 5.5 mm.

Spleen

The spleen is normal in size, shape, margination and echogenicity. No masses are seen.

Liver

The liver presents normal size and shape with smooth lobar margins. The parenchyma has normal echogenicity with normal echotexture. No focal lesions are seen. Intrahepatic bile ducts are normal. Normal vascular pattern. No evidence of metastatic disease is clearly identified.

The gallbladder presents normal size with anechoic contents. Normal gallbladder wall. No evidence of bile duct distention or obstruction.

Gastrointestinal

PATIENT

Sadie Deurbrouck

SPECIES

Canine

BREED

Dachshund

SEX

Spayed Female

AGE

16 Years

WEIGHT

5.5 kg

INTERPRETED BY

Greg Kuhlman, DVM, DACVIM (SAIM)

IMAGING PERFORMED BY

Carlie Koltek, RVT

HOSPITAL NAME

Tuxedo Animal Hospital

REFERRING VET

Dr. Gemriff Capao

INVOICE

16594

DATE

05/29/26

The stomach and intestines have normal wall layering and thickness. Colon contains normal contents with normal wall thickness.

Pancreas

The visible left pancreas is normal in size with normal echogenic parenchyma and surrounded by normal peri-pancreatic mesentery.

Free Abdomen

There are no enlarged abdominal lymph nodes seen on this exam. No free abdominal fluid is seen.

ULTRASONOGRAPHIC FINDINGS

- Mildly irregularly shaped right kidney- may be age-related change may indicate early chronic kidney disease.

INTERPRETATION OF THE FINDINGS & FURTHER RECOMMENDATIONS

No cause for the patient's hypoglycemia is seen on this exam. No evidence of metastatic or neoplasia is seen on this ultrasound exam. Recommend full staging, monitoring, and managing per IRIS guidelines.

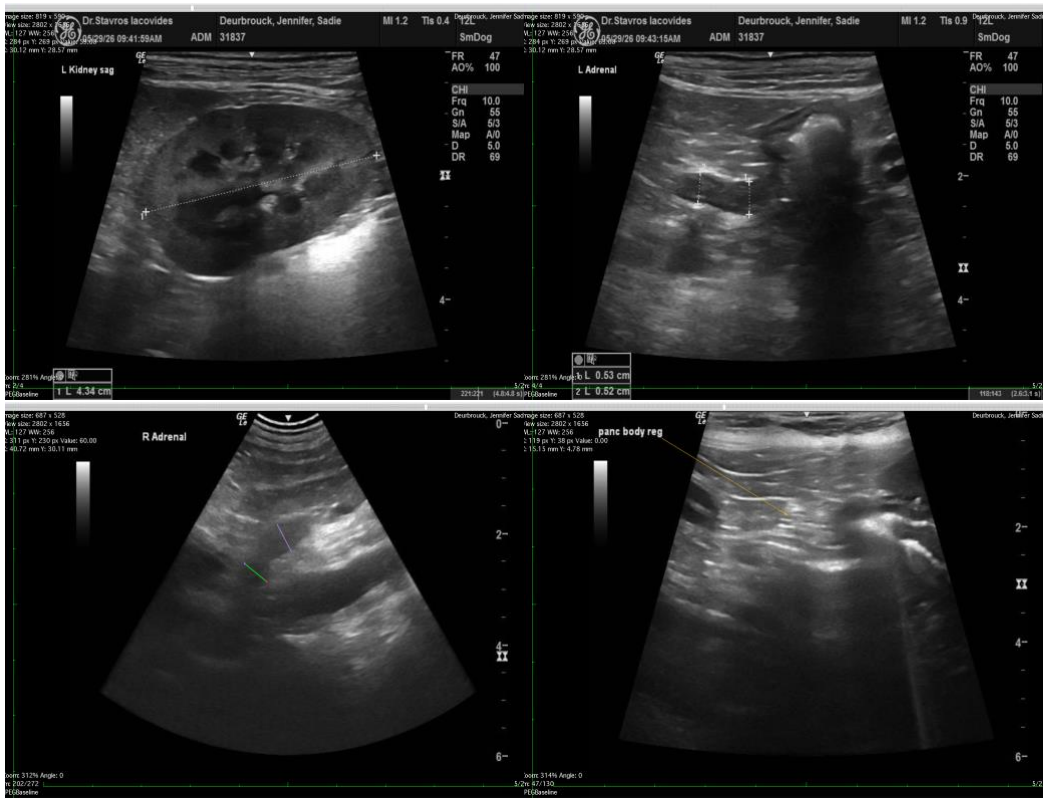

SonoPath
FOSTERING THE ART OF VETERINARY MEDICINE™

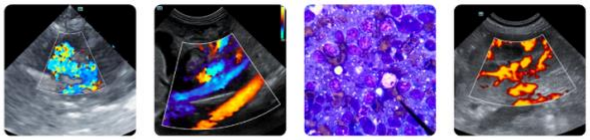

Clinical Sonography & Telecytology
Educational Teleconsultation Services™

SonoPath.com info@sonopath.com 1.800.838.4268

PATIENT

Sadie Deurbrouck

SPECIES

Canine

BREED

Dachshund

SEX

Spayed Female

AGE

16 Years

WEIGHT

5.5 kg

INTERPRETED BY

Greg Kuhlman, DVM, DACVIM (SAIM)

IMAGING PERFORMED BY

Carlie Koltek, RVT

HOSPITAL NAME

Tuxedo Animal Hospital

REFERRING VET

Dr. Gemriff Capao

INVOICE

16594

DATE

05/29/26

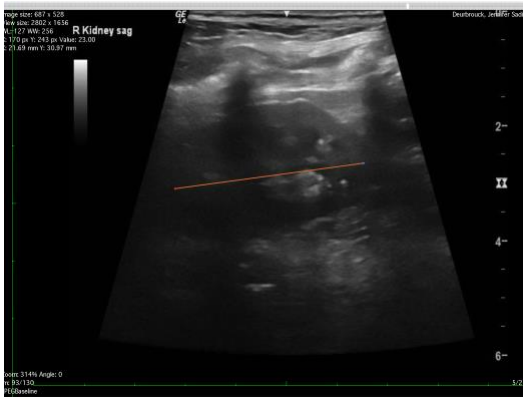

The information and recommendations provided are based on the images presented by the referring veterinarian/sonographer. No evaluation can be communicated regarding pathology that was not visible in the image/video clips provided.

Thank you for this referral. If the clinical or image interpretation does not parallel your findings or if I can be of any further assistance, please contact me.

Greg Kuhlman, DVM, DACVIM (SAIM)
Veterinary Internal Medicine Specialist
info@SonoPath.com