



PATIENT

Titus Horridge

SPECIES

Canine

BREED

Mixed

SEX

Neutered Male

AGE

14 Years

WEIGHT

70 lbs

INTERPRETED BY

Greg Kuhlman, DVM,
 DACVIM (SAIM)

IMAGING PERFORMED BY

Dr. Ken Leal

HOSPITAL NAME

Dr. T Vetcare

REFERRING VET

Dr. Turk

INVOICE

16323

DATE

05/18/26

PRESENTING CLINICAL SIGNS

Albumin, Globulin, Alk Phos, Changed increased. Suspected liver mass on radiographs.
 Medications: carprofen 75 mg BID.

Urinalysis: Protein 1 + Urine Specific gravity: 1.35 PCV = 34 %

ULTRASONOGRAPHIC EXAMINATION OF THE ABDOMEN

Urinary System

The bladder is moderately distended with anechoic urine. No uroliths are seen. The bladder wall is normal in appearance and thickness. No masses are seen.

The prostate appears normal.

The left kidney presents normal size with normal shape and architecture. Normal corticomedullary distinction. No pyelectasia, ureteral dilation or nephrolithiasis. The left kidney measured 7.0 cm in length.

The right kidney presents normal size with normal shape and architecture. Normal corticomedullary distinction. No pyelectasia, ureteral dilation or nephrolithiasis. The right kidney measured 7.4 cm in length.

Adrenal Glands

The left adrenal gland presents normal shape and homogenous parenchyma. The phrenic vasculature is unremarkable. The cranial pole measures 7.0 mm and the caudal pole measures 7.4 mm.

The right adrenal gland presents normal shape and homogenous parenchyma. The phrenic vasculature is unremarkable. The cranial pole measures 7.6 mm and the caudal pole measures 6.5 mm.

Spleen

The spleen was not visualized owing to previous splenectomy in 2025.

Liver

The liver presents diffusely enlarged. There are multifocal to coalescing hypoechoic lesions throughout the liver, some of which are displacing the capsule. A representative lesion measures 3 mm in width. These lesions are most likely metastatic neoplasia. The appearance of the liver is concerning for metastatic neoplasia, especially the hypoechoic to coalescing lesions are most likely consistent with metastatic neoplasia. In the mid liver at the caudal aspect, there is a 6.4 cm isoechoic mass lesion present that also has multifocal to coalescing hypoechoic lesions throughout which are similar to the lesions seen through the rest of the liver. This mass is most likely due to possible primary hepatobiliary neoplasia such as hepatocellular carcinoma, less likely cholangiocarcinoma.

The gallbladder presents normal size with anechoic contents. Normal gallbladder wall. No evidence of bile duct distention or obstruction.

Gastrointestinal



PATIENT

Titus Horridge

SPECIES

Canine

BREED

Mixed

SEX

Neutered Male

AGE

14 Years

WEIGHT

70 lbs

INTERPRETED BY

Greg Kuhlman, DVM,
 DACVIM (SAIM)

IMAGING PERFORMED BY

Dr. Ken Leal

HOSPITAL NAME

Dr. T Vetcare

REFERRING VET

Dr. Turk

INVOICE

16323

DATE

05/18/26

The stomach and intestines have normal wall layering and thickness. Colon contains normal contents with normal wall thickness.

Pancreas

The pancreas is not clearly visualized on this exam.

Free Abdomen

There are no enlarged abdominal lymph nodes seen on this exam. There is a moderate amount of free fluid present within the abdomen. This fluid is hypoechoic and does not appear to have significant echogenic debris present throughout the fluid.

Cardiac image is provided and no obvious cardiac mass is seen. No pericardial effusion.

ULTRASONOGRAPHIC FINDINGS

- Hepatic mass and lesions.
- Free abdominal fluid.

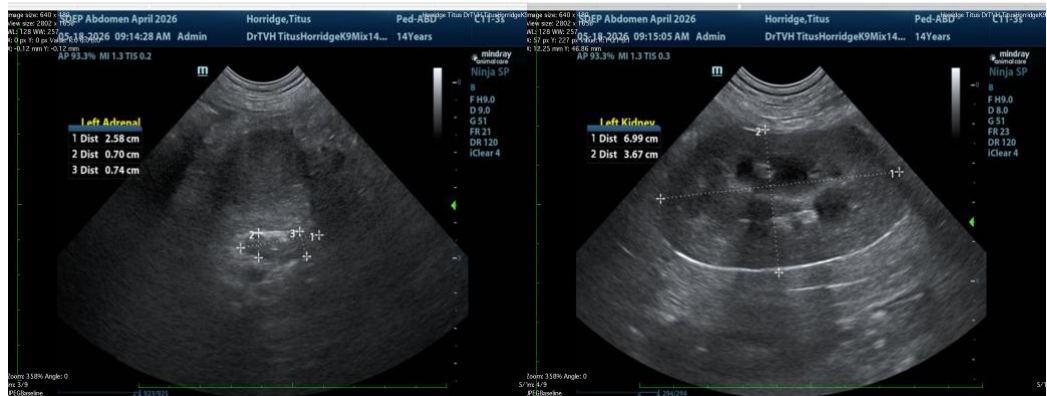
INTERPRETATION OF THE FINDINGS & FURTHER RECOMMENDATIONS

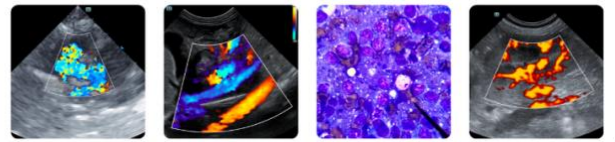
I recommend fluid aspirate via ultrasound guidance to determine fluid type present. Given that the patient had a splenectomy last year, it was unknown as to the etiology of the splenic mass that was in the spleen when splenectomy was performed, as histopathology was not performed.

Given the lesions throughout the liver at this time, there is strong concern for possible metastatic hemangiosarcoma, and so the free fluid in the abdomen is concerning for a possible hemoabdomen. Recommend aspirate for fluid analysis.

In conclusion, the changes or the appearance of the liver is most certainly due to metastatic neoplasia, most likely metastatic hemangiosarcoma. Consider fine needle aspirate of liver for cytology to determine if there could be another etiology for the appearance of the liver.

Also, if three-view chest radiographs have not been performed, consider three-view chest radiographs to screen for pulmonary metastatic disease.





PATIENT

Titus Horridge

SPECIES

Canine

BREED

Mixed

SEX

Neutered Male

AGE

14 Years

WEIGHT

70 lbs

INTERPRETED BY

Greg Kuhlman, DVM,
 DACVIM (SAIM)

IMAGING PERFORMED BY

Dr. Ken Leal

HOSPITAL NAME

Dr. T Vetcare

REFERRING VET

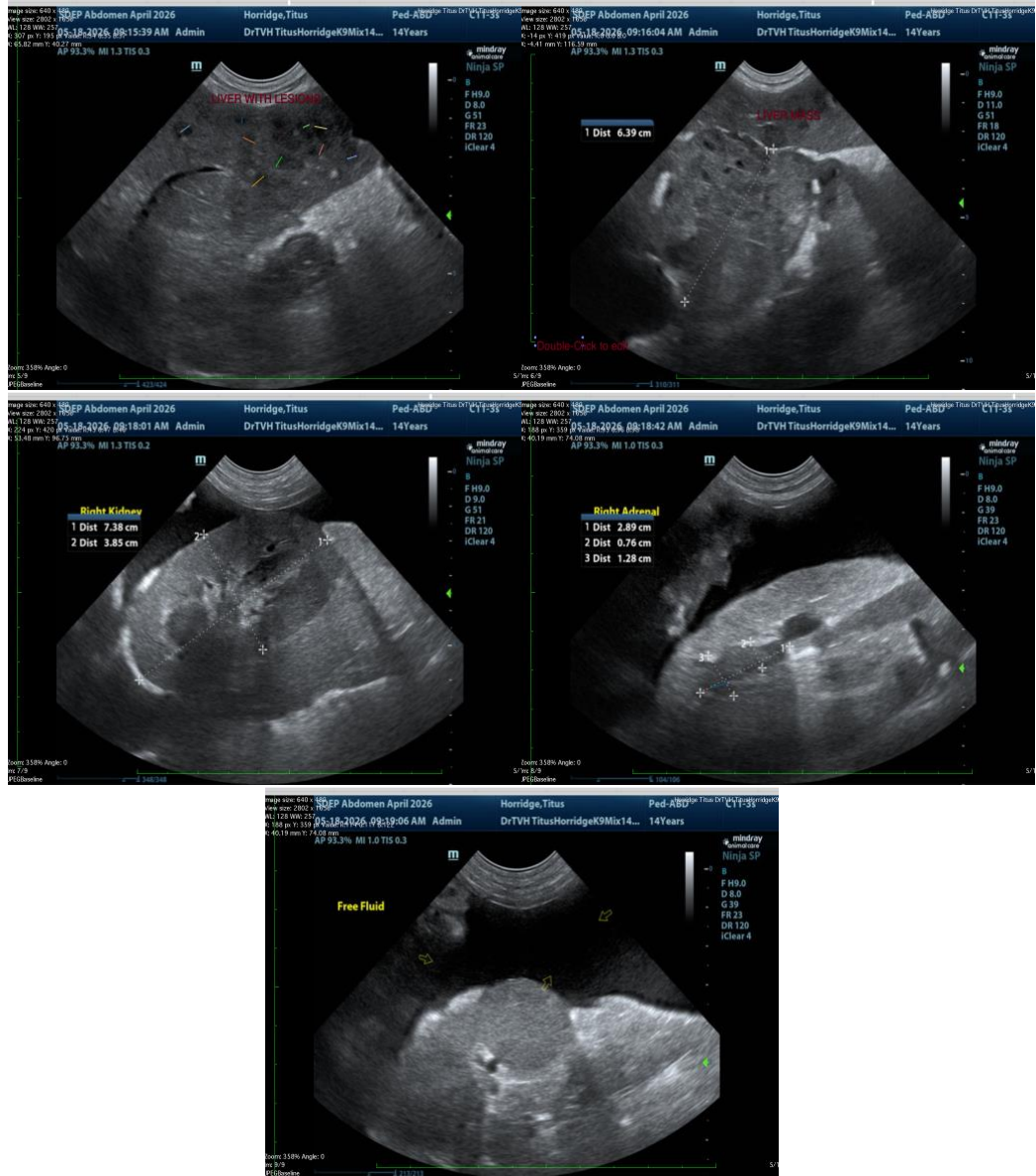
Dr. Turk

INVOICE

16323

DATE

05/18/26



The information and recommendations provided are based on the images presented by the referring veterinarian/sonographer. No evaluation can be communicated regarding pathology that was not visible in the image/video clips provided.

Thank you for this referral. If the clinical or image interpretation does not parallel your findings or if I can be of any further assistance, please contact me.

Greg Kuhlman, DVM, DACVIM (SAIM)
 Veterinary Internal Medicine Specialist
info@SonoPath.com