



## PATIENT

T'Challa Anderson

## SPECIES

Canine

## BREED

Basenji

## SEX

Spayed Female

## AGE

5 Years 3 Months

## WEIGHT

26 pounds

## INTERPRETED BY

Greg Kuhlman, DVM,  
DACVIM (SAIM)

## IMAGING PERFORMED BY

Dr. Celia Galanti

## HOSPITAL NAME

Craig Road Animal  
Hospital

## REFERRING VET

Dr. Celia Galanti

## INVOICE

15472

## DATE

04/26/26

## PRESENTING CLINICAL SIGNS

P presenting for routine dental. Pre-op bloodwork revealed ALT elevation. P clinically doing well at home. History of chronic allergies year round and sensitive stomach. P currently receiving hydroxyzine and trazodone as needed for separation anxiety.

Abnormal PE/Chem/CBC/UA Results: ALT 348

## ULTRASONOGRAPHIC EXAMINATION OF THE ABDOMEN

### *Urinary System*

Urinary bladder is adequately distended. It has a normal uniform wall thickness. Contents include primarily anechoic fluid with echogenic non-shadowing debris, most consistent with exfoliated cells, mucous and/or small blood clots. Both sterile inflammation as well as urinary tract infection can present with echogenic debris. No masses or cystoliths are observed. The trigone and visible pelvic urethra are normal in thickness with a smooth mucosal surface.

The left kidney presents normal size with normal shape and architecture. Normal corticomedullary distinction. No pyelectasia, ureteral dilation or nephrolithiasis. The left kidney measured 4.6 cm in length.

The right kidney presents normal size with normal shape and architecture. Normal corticomedullary distinction. No pyelectasia, ureteral dilation or nephrolithiasis. The right kidney measured 4.7 cm in length.

### *Adrenal Glands*

The left adrenal gland presents normal shape and homogenous parenchyma. The phrenic vasculature is unremarkable. The cranial pole measures 4.0 mm and the caudal pole measures 5.4 mm.

The right adrenal gland presents normal shape and homogenous parenchyma. The phrenic vasculature is unremarkable. The cranial pole measures 4.9 mm and the caudal pole measures 5.0 mm.

### *Spleen*

The spleen is normal in size, shape, margination and echogenicity. No masses are seen.

### *Liver*

Liver is subjectively enlarged with mildly irregular margins. Parenchyma is heterogenous characterized by multiple poorly defined hypoechoic nodules within otherwise hyperechoic liver parenchyma. Visible vasculature and biliary tree appear normal without distension or congestion.

Gallbladder is moderately distended with anechoic bile as well as mild suspended and gravity dependent echogenic debris. The wall is smooth without visible thickening. There is no evidence of cystic or CBD dilation. There is no evidence of effusion or inflammation.

### *Gastrointestinal*

The stomach and intestines have normal wall layering and thickness. Colon contains normal contents with normal wall thickness.



## PATIENT

T'Challa Anderson

## SPECIES

Canine

## BREED

Basenji

## SEX

Spayed Female

## AGE

5 Years 3 Months

## WEIGHT

26 pounds

## INTERPRETED BY

Greg Kuhlman, DVM,  
DACVIM (SAIM)

## IMAGING PERFORMED BY

Dr. Celia Galanti

## HOSPITAL NAME

Craig Road Animal  
Hospital

## REFERRING VET

Dr. Celia Galanti

## INVOICE

15472

## DATE

04/26/26

## *Pancreas*

The visible pancreas is normal in size with normal echogenic parenchyma and surrounded by normal peri-pancreatic mesentery.

## *Free Abdomen*

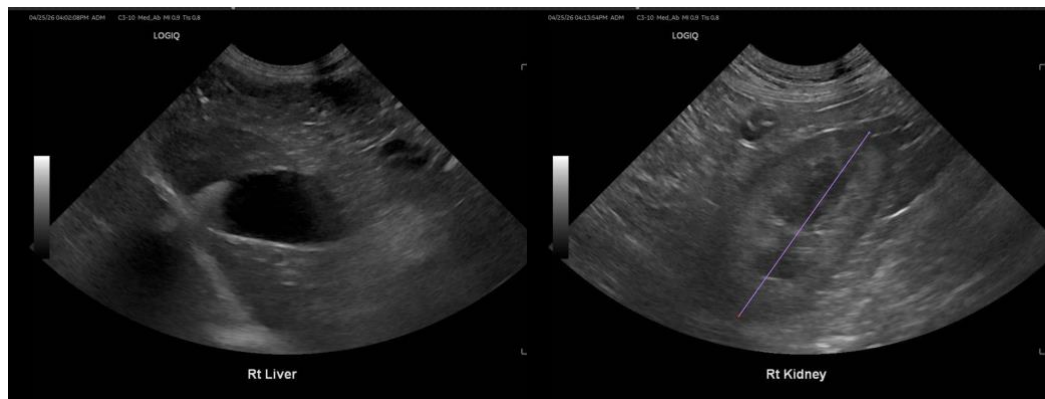
Mild diffuse mesenteric lymphadenopathy is present with two representative nodes measuring 3.6 mm x 9.4 mm and 2.6 mm x 13.3 mm. These nodes are most likely reactive as the cause of the enlargement is much less likely a neoplastic cause.

## ULTRASONOGRAPHIC FINDINGS

- Mild urinary bladder debris.
- Mild gallbladder debris.
- Heterogenous liver.
- Enlarged mesenteric lymphadenopathy.

## INTERPRETATION OF THE FINDINGS & FURTHER RECOMMENDATIONS

Recommend urinalysis if not performed. If active urine sediment, recommend urine culture. Given the patient's breed, the most likely cause for the elevated ALT and appearance of the liver is a chronic hepatopathy, specifically copper storage disease, however, other diseases such as chronic active hepatitis or sterile pyogranulomatous hepatitis cannot be ruled out based on this ultrasound. Unlikely the patient has an infiltrative disease such as lymphoma or mast cell as the cause of the appearance of the liver and elevated ALT given that they are not feeling unwell. Consider fine needle aspirate of liver prior to liver biopsy to rule these diseases out. If patient is not vaccinated for leptospirosis, consider leptospirosis testing prior to surgical procedure. If patient's ALT remains persistently elevated over the next one to two months, it is recommended to perform a liver biopsy and submit samples from at least three different liver lobes for histopathology to a pathology group that specializes in liver pathology such as the Antech super liver group. Also recommend submitting a liver biopsy sample to Colorado state university for copper quantitation. Recommend submitting liver sample for aerobic/anaerobic bacterial culture. Prognosis is open pending results of liver diagnostics.





## PATIENT

T'Challa Anderson

## SPECIES

Canine

## BREED

Basenji

## SEX

Spayed Female

## AGE

5 Years 3 Months

## WEIGHT

26 pounds

## INTERPRETED BY

Greg Kuhlman, DVM,  
DACVIM (SAIM)

## IMAGING PERFORMED BY

Dr. Celia Galanti

## HOSPITAL NAME

Craig Road Animal  
Hospital

## REFERRING VET

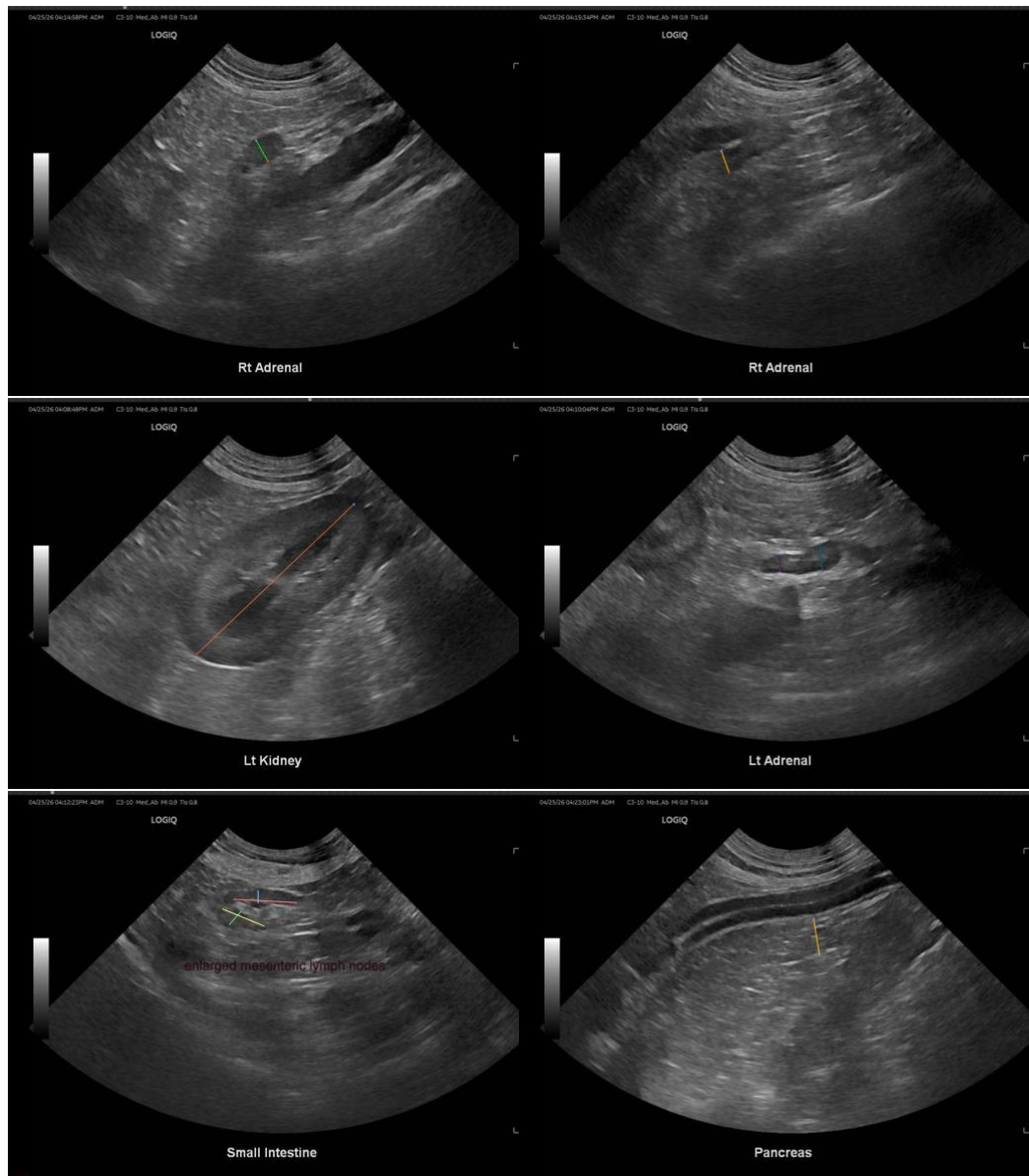
Dr. Celia Galanti

## INVOICE

15472

## DATE

04/26/26



The information and recommendations provided are based on the images presented by the referring veterinarian/sonographer. No evaluation can be communicated regarding pathology that was not visible in the image/video clips provided.

Thank you for this referral. If the clinical or image interpretation does not parallel your findings or if I can be of any further assistance, please contact me.

Greg Kuhlman, DVM, DACVIM (SAIM)  
Veterinary Internal Medicine Specialist  
[info@SonoPath.com](mailto:info@SonoPath.com)