



PATIENT

Zoey Amaral

SPECIES

Canine

BREED

Labradoodle

SEX

Spayed Female

AGE

13 Years 10 Months

WEIGHT

19.4 kg

INTERPRETED BY

Greg Kuhlman, DVM,
DACVIM (SAIM)

IMAGING PERFORMED BY

Dr. Renee Trionfetti
VMD

HOSPITAL NAME

Brandywine Valley
Veterinary Hospital

REFERRING VET

Dr. Robert Cafaro
VMD

INVOICE

15067

DATE

04/13/26

PRESENTING CLINICAL SIGNS

AUS to further evaluate progressive elevation of liver enzymes and creatinine. No clinical signs reported.

Meds: Denamarin advanced, gabapentin, carprofen

Abnormal PE/Chem/CBC/UA Results: 4/3/26: - CBC: Hct 49.3%, Plts 290-n, NSF - Chem: Alb 3.4-n, ALP 164 H (5-160), ALT 449 H (18-121), AST 121 H (16-55), BUN 29-n, Cr 2.9 H, SDMA 11-n - T4: 1.7-n - 4Dx: Neg x 4 - Fecal: NPS

ULTRASONOGRAPHIC EXAMINATION OF THE ABDOMEN

Urinary System

The apical aspect of the urinary bladder luminal margin is mildly irregular in contour and subjectively mildly thickened at 2.7 mm width. The bladder does contain a moderate amount of anechoic urine that does contain a small amount of suspended echogenic debris. The urinary bladder wall is of normal thickness and has normal luminal margins in the caudal aspect of the bladder. The caudal aspect of the bladder wall measures 1.6 mm in width. The proximal urethral wall is mildly thickened at 2.5 mm width. Suspect possibly chronic cystitis as cause. Neoplasia not suspected as cause at this time.

The left kidney presents normal size with normal shape and architecture. Mild loss of corticomedullary distinction. No pyelectasia, ureteral dilation or nephrolithiasis. The left kidney measured 5.7 cm in length.

The right kidney presents normal size with normal shape and architecture. Moderate loss of corticomedullary distinction. Non-obstructive linear multifocal hyperechoic diverticular foci with acoustic shadowing are noted. The right kidney measured 5.8 cm in length.

Adrenal Glands

The left adrenal gland presents normal shape and homogenous parenchyma. The phrenic vasculature is unremarkable. The cranial pole measures 4.6 mm and the caudal pole measures 5.2 mm.

The right adrenal gland presents normal shape and homogenous parenchyma. The phrenic vasculature is unremarkable. The cranial pole measures 4.6 mm and the caudal pole measures 6.2 mm.

Spleen

The spleen is normal in size and echogenicity and has normal echogenicity. Mildly heteroechoic echotexture, most likely an age-related change.

Liver

Liver is subjectively enlarged with mildly irregular margins. Parenchyma is (mildly, moderately or markedly) heterogenous characterized by multiple poorly defined hypoechoic nodules within otherwise hyperechoic liver parenchyma. Visible vasculature and biliary tree appear normal without distension or congestion.

The gallbladder presents normal size with anechoic contents. Normal gallbladder wall. No evidence of bile duct distention or obstruction.



PATIENT

Zoey Amaral

SPECIES

Canine

BREED

Labradoodle

SEX

Spayed Female

AGE

13 Years 10 Months

WEIGHT

19.4 kg

INTERPRETED BY

Greg Kuhlman, DVM,
DACVIM (SAIM)

IMAGING PERFORMED BY

Dr. Renee Trionfetti
VMD

HOSPITAL NAME

Brandywine Valley
Veterinary Hospital

REFERRING VET

Dr. Robert Cafaro
VMD

INVOICE

15067

DATE

04/13/26

Gastrointestinal

The stomach and intestines have normal wall layering and thickness. Colon contains normal contents with normal wall thickness.

Pancreas

The visible pancreas is normal in size with normal echogenic parenchyma and surrounded by normal peri-pancreatic mesentery.

Free Abdomen

There are no enlarged abdominal lymph nodes seen on this exam. No free abdominal fluid is seen.

ULTRASONOGRAPHIC FINDINGS

- Bilateral loss of corticomedullary detail in kidneys.
- Bladder wall thickening.
- Heterogenous liver.

INTERPRETATION OF THE FINDINGS & FURTHER RECOMMENDATIONS

Given that the patient has bilateral loss of corticomedullary detail of each kidney and that reportedly the patient's creatinine has been progressively elevating at this time, recommend full staging, monitoring and managing the patient for suspected chronic kidney disease per the International Renal Interest Society guidelines. The normal SDMA is most likely a false negative and it appears more important to pursue the elevated creatinine and appearance of the kidneys on this ultrasound in suspecting the patient has chronic kidney disease.

If a urine culture has not been performed, recommend performing urine culture to rule out bacterial cystitis. A neoplastic cause for the appearance of the urinary bladder is not suspected at this time.

The liver differentials include possible infiltrative neoplasia such as lymphoma/mast cell disease. Recommend fine needle aspirate to rule these diseases out. If round cell neoplasia is ruled out, consider possible primary hepatic disease such as copper storage disease, chronic active hepatitis, granulomatous hepatitis. If round cell neoplasia is ruled out and ALT and AST remain elevated, consider liver biopsy and submit samples for histopathology, copper connotation and aerobic/anaerobic bacterial culture. If patient is not vaccinated for leptospirosis, recommend submitting leptospirosis testing as possible cause of patients chronic hepatopathy.



PATIENT

Zoey Amaral

SPECIES

Canine

BREED

Labradoodle

SEX

Spayed Female

AGE

13 Years 10 Months

WEIGHT

19.4 kg

INTERPRETED BY

Greg Kuhlman, DVM,
DACVIM (SAIM)

IMAGING PERFORMED BY

Dr. Renee Trionfetti
VMD

HOSPITAL NAME

Brandywine Valley
Veterinary Hospital

REFERRING VET

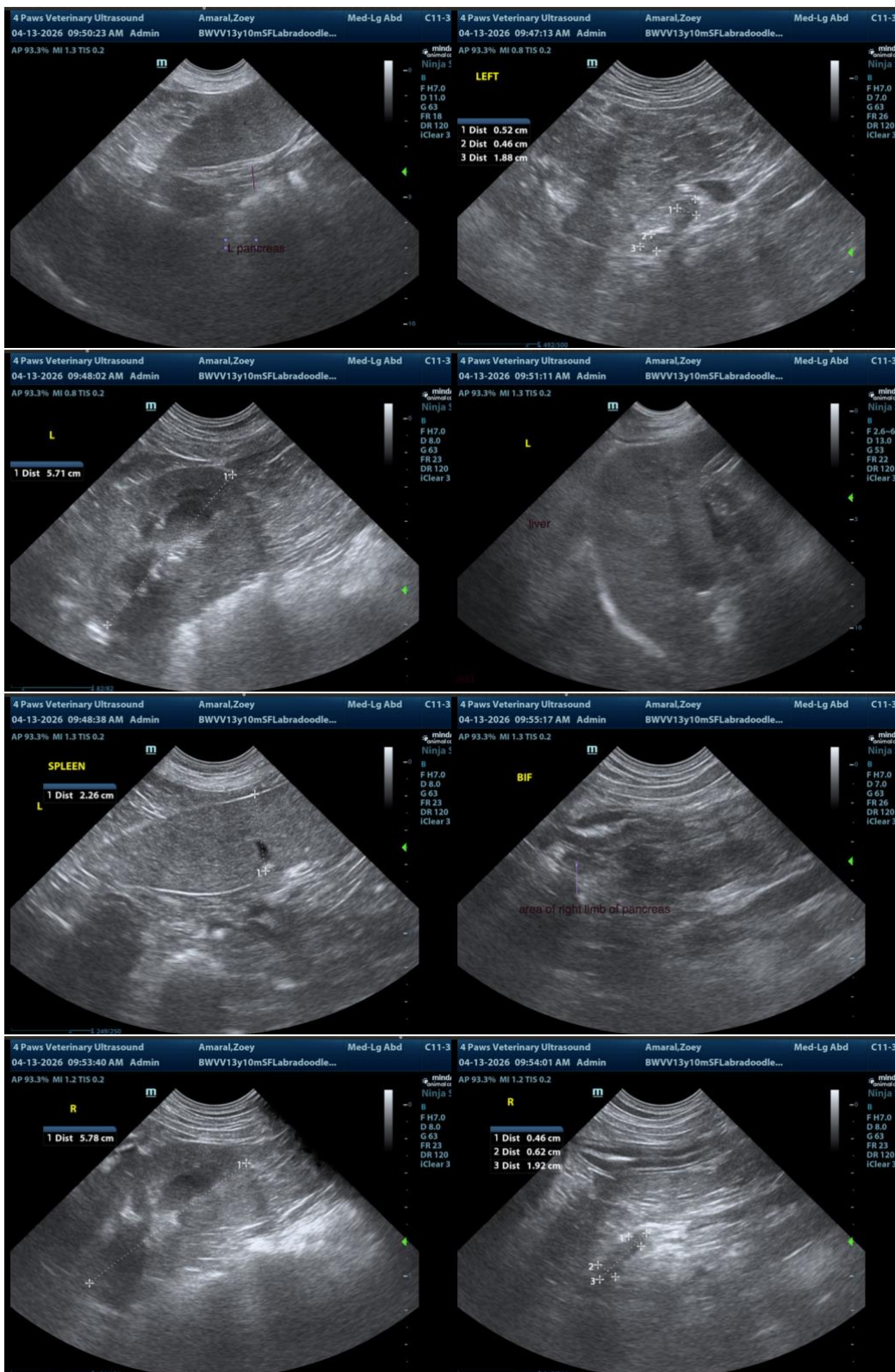
Dr. Robert Cafaro
VMD

INVOICE

15067

DATE

04/13/26





PATIENT

Zoey Amaral

SPECIES

Canine

BREED

Labradoodle

SEX

Spayed Female

AGE

13 Years 10 Months

WEIGHT

19.4 kg

INTERPRETED BY

Greg Kuhlman, DVM,
DACVIM (SAIM)

IMAGING PERFORMED BY

Dr. Renee Trionfetti
VMD

HOSPITAL NAME

Brandywine Valley
Veterinary Hospital

REFERRING VET

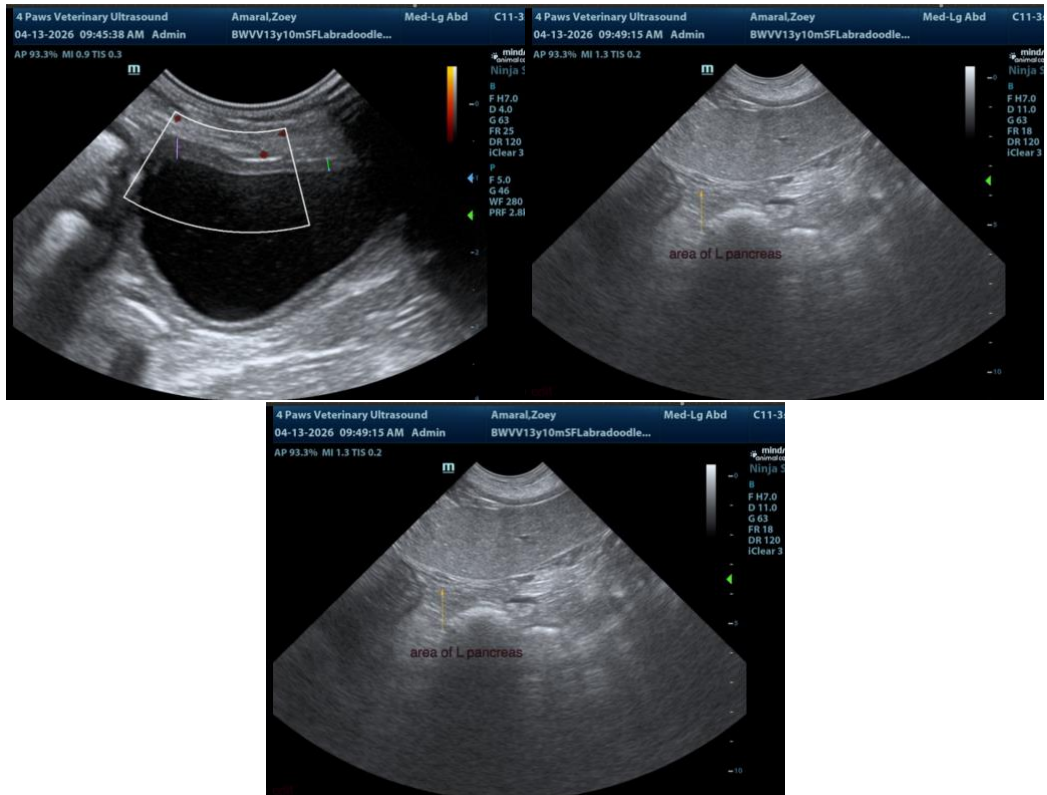
Dr. Robert Cafaro
VMD

INVOICE

15067

DATE

04/13/26



The information and recommendations provided are based on the images presented by the referring veterinarian/sonographer. No evaluation can be communicated regarding pathology that was not visible in the image/video clips provided.

Thank you for this referral. If the clinical or image interpretation does not parallel your findings or if I can be of any further assistance, please contact me.

Greg Kuhlman, DVM, DACVIM (SAIM)
Veterinary Internal Medicine Specialist
info@SonoPath.com