



## PATIENT

Olive Lawson

## SPECIES

Canine

## BREED

Irish Wolfhound

## SEX

Spayed Female

## AGE

5 years

## WEIGHT

118 lbs

## INTERPRETED BY

Greg Kuhlman, DVM,  
DACVIM (SAIM)

## IMAGING PERFORMED BY

Dr. Kristen Velasco

## HOSPITAL NAME

Bethany Family Pet  
Clinic

## REFERRING VET

Dr. Kristen Velasco

## INVOICE

11437

## DATE

3/9/2026

## PRESENTING CLINICAL SIGNS

- THE LATERAL ASPECT OF THE RIGHT CARPUS HAS A 1-2 CM
- SOFT SWELLING, CONSISTENT WITH SWELLING OF THE JOINT.
- Bone lesion present on radiograph today.
- Pending: cytology and culture

## ULTRASONOGRAPHIC EXAMINATION OF THE ABDOMEN

### Urinary System

The bladder is moderately distended with anechoic urine. No uroliths are seen. The bladder wall is normal in appearance and thickness. No masses are seen.

The left kidney presents normal size with normal shape and architecture. Normal corticomedullary distinction. No pyelectasia, ureteral dilation or nephrolithiasis. The left kidney measured 3.4 cm in length.

The right kidney presents normal size with normal shape and architecture. Normal corticomedullary distinction. No pyelectasia, ureteral dilation or nephrolithiasis. The right kidney measured 7.2 cm in length.

### Adrenal Glands

The adrenal glands are not visualized on this exam.

### Spleen

The spleen is folded upon itself but over appearance normal in size and echogenicity. No masses are seen.

### Liver

The liver presents normal size and shape with smooth lobar margins. The parenchyma has normal echogenicity with normal echotexture. No focal lesions are seen. Intrahepatic bile ducts are normal. Normal vascular pattern.

The gallbladder presents normal size with anechoic contents. Normal gallbladder wall. No evidence of bile duct distention or obstruction.

### Gastrointestinal

The stomach contains a moderate amount of retained ingesta, There is no pyloric outflow tract obstruction observed. Appears patient may not be fully fasted for this exam. Small intestines have normal wall layering and thickness. Colon contains normal contents with normal wall thickness.

### Pancreas

The visible pancreas is normal in size with normal echogenic parenchyma and surrounded by normal peri-pancreatic mesentery.

### Free Abdomen



## PATIENT

Olive Lawson

## SPECIES

Canine

## BREED

Irish Wolfhound

## SEX

Spayed Female

## AGE

5 years

## WEIGHT

118 lbs

## INTERPRETED BY

Greg Kuhlman, DVM,  
DACVIM (SAIM)

## IMAGING PERFORMED BY

Dr. Kristen Velasco

## HOSPITAL NAME

Bethany Family Pet  
Clinic

## REFERRING VET

Dr. Kristen Velasco

## INVOICE

11437

## DATE

3/9/2026

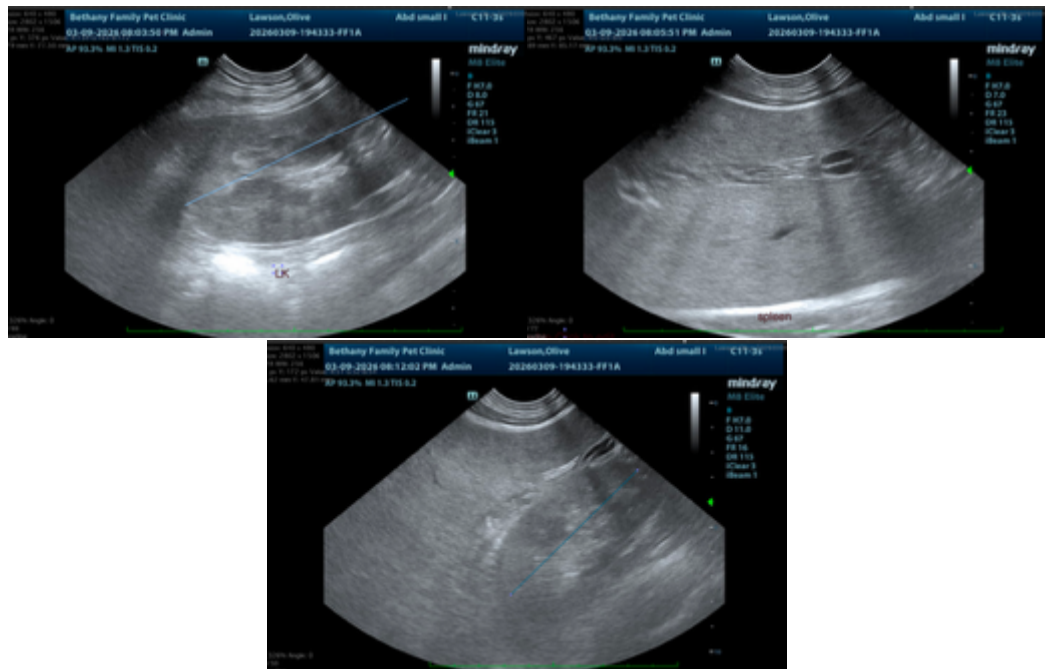
There are no enlarged abdominal lymph nodes seen on this exam. No free abdominal fluid is seen.

## ULTRASONOGRAPHIC FINDINGS

- This appears to be a normal abdominal ultrasound.

## INTERPRETATION OF THE FINDINGS & FURTHER RECOMMENDATIONS

No significant abnormalities are visualized on this exam. There is no obvious evidence of primary neoplastic disease, or metastatic neoplastic disease is seen on this exam.



The information and recommendations provided are based on the images presented by the referring veterinarian/sonographer. No evaluation can be communicated regarding pathology that was not visible in the image/video clips provided.

Thank you for this referral. If the clinical or image interpretation does not parallel your findings or if I can be of any further assistance, please contact me.

Greg Kuhlman, DVM, DACVIM (SAIM)

Veterinary Internal Medicine Specialist  
[info@SonoPath.com](mailto:info@SonoPath.com)