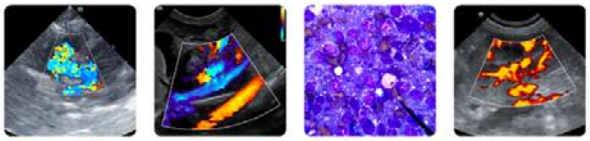

PATIENT
Rosie Wilder

SPECIES
Canine

BREED
Lab x

SEX
Spayed Female

AGE
13 Years

WEIGHT
95 lbs

INTERPRETED BY
Greg Kuhlman, DVM, DACVIM (SAIM)

IMAGING PERFORMED BY
Laura Klaassen

HOSPITAL NAME
Animal Care Group of Lake Oswego

REFERRING VET
Dr. Allie Wisniewski

INVOICE
73404

DATE
3/4/26

PRESENTING CLINICAL SIGNS

Presented for pu/pd. No weight loss, otherwise fine.

Abnormal PE/Chem/CBC/UA Results: ALT 138 - ALP 1067 - GGT 14 - triglycerides 389 - amylase 278 - precision PSL 194 - monocytes 1408 high USG - 1.018 quiet

ULTRASONOGRAPHIC EXAMINATION OF THE ABDOMEN

Urinary System

The bladder is moderately distended with anechoic urine. No uroliths are seen. The bladder wall is normal in appearance and thickness. No masses are seen. No ureteral papillae seen.

The right kidney presents normal size (6.5 cm) with normal shape and architecture. Normal corticomedullary distinction. No pyelectasia, ureteral dilation or nephrolithiasis.

The left kidney presents normal size (6.3 cm) with normal shape and architecture. Normal corticomedullary distinction. No pyelectasia, ureteral dilation or nephrolithiasis.

Adrenal Glands

The adrenal glands were not visualized on this exam.

Spleen

The spleen is normal in size and echogenicity with a normal echotexture. There are multifocal hyperechoic variably sized lesions throughout the spleen, suspected to be benign myelolipomas. One of the larger lesions measures 7.1 mm in width.

Liver

The liver is diffusely enlarged and hyperechoic with rounded margins. There are multifocal, variably sized, ill-defined hypoechoic lesions throughout the liver, consistent with possible regenerative nodules or possibly due to metastatic neoplasia. One of the larger lesions measures 1.3 mm x 9.3 mm. Several of the lesions have a targetoid appearance. In the right liver there is a 9.5 mm in diameter cystic lesion. There is no mass associated with this cyst. It is most likely benign and is in the caudal aspect of the liver.

The gallbladder presents normal size and contains a moderate amount of echogenic debris, which appears to be aggregating at this time. There is a hypoechoic rim around the debris. Normal gallbladder wall. No evidence of bile duct distention or obstruction.

Gastrointestinal

The stomach and intestines have normal wall layering and thickness. Colon contains normal contents with normal wall thickness.

Pancreas

The visible pancreas is normal in size with normal echogenic parenchyma and surrounded by normal peri-pancreatic mesentery.

PATIENT
Rosie Wilder

SPECIES
Canine

BREED
Lab x

SEX
Spayed Female

AGE
13 Years

WEIGHT
95 lbs

INTERPRETED BY
Greg Kuhlman, DVM, DACVIM (SAIM)

IMAGING PERFORMED BY
Laura Klaassen

HOSPITAL NAME
Animal Care Group of Lake Oswego

REFERRING VET
Dr. Allie Wisniewski

INVOICE
73404

DATE
3/4/26

Free Abdomen

There are no enlarged abdominal lymph nodes seen on this exam. No free abdominal fluid is seen.

ULTRASONOGRAPHIC FINDINGS

- Enlarged, heterochoic liver with multifocal variably sized hypoechoic lesions – These lesions are concerning for possible metastatic neoplasia.
- Early immature gallbladder mucocele.
- Hyperechoic splenic lesions, likely benign myelolipomas.

INTERPRETATION OF THE FINDINGS & FURTHER RECOMMENDATIONS

The referring veterinarian reportedly performed a fine needle aspirate of the superficial liver lobes. Recommend submitting for cytology. If cytology is inconclusive as to the cause of the appearance of the liver, then recommend attempting fine needle aspirate of one of the larger hyperechoic lesions within the liver. Ultimately, if fine needle aspirates of the liver itself (pending) or aspirates of liver lesions are inconclusive as to the cause of the liver's appearance and the elevated liver enzymes, a liver biopsy would be recommended.

Recommend starting Ursodiol at 15mg/kg given by mouth split into two daily doses and treating with antibiotics such as Amoxicillin for approximately 6 weeks, at which point recheck of the liver values and appearance of the gallbladder would be recommended to determine if improvement is seen with the treatment plan. Ultimately, cholecystectomy may be necessary. However, given that the patient's bilirubin is not currently elevated, surgery is not necessary at this time unless there is failure of medical management.

Consider a fine needle aspirate of a hyperechoic splenic lesion to rule out a neoplastic process, although neoplasia is not highly suspected.

Recommend performing 3-view chest radiographs if not already performed to rule out pulmonary neoplasia as a possible site for a primary tumor.

Prognosis is open pending results of further recommended diagnostics.

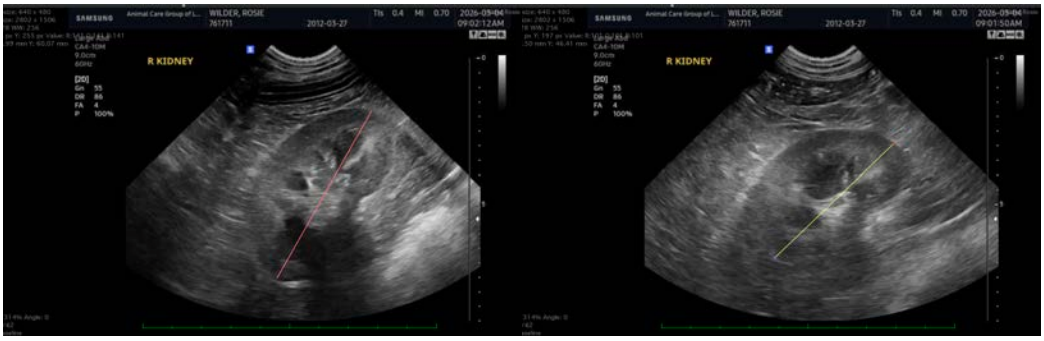

SonoPath
FOSTERING THE ART OF VETERINARY MEDICINE™

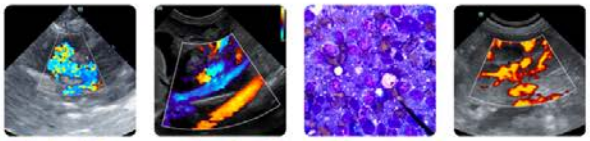

Clinical Sonography & Telecytology
Educational Teleconsultation Services™

SonoPath.com info@sonopath.com 1.800.838.4268

PATIENT

Rosie Wilder

SPECIES

Canine

BREED

Lab x

SEX

Spayed Female

AGE

13 Years

WEIGHT

95 lbs

INTERPRETED BY

Greg Kuhlman, DVM, DACVIM (SAIM)

IMAGING PERFORMED BY

Laura Klaassen

HOSPITAL NAME

Animal Care Group of Lake Oswego

REFERRING VET

Dr. Allie Wisniewski

INVOICE

73404

DATE

3/4/26

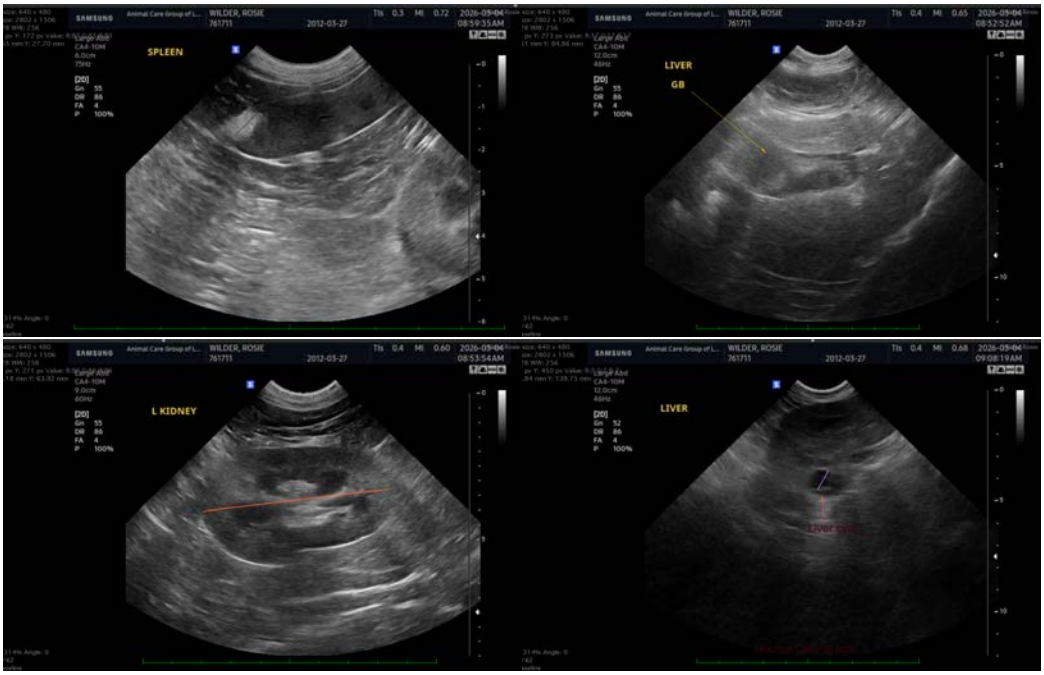

The information and recommendations provided are based on the images presented by the referring veterinarian/sonographer. No evaluation can be communicated regarding pathology that was not visible in the image/video clips provided.

Thank you for this referral. If the clinical or image interpretation does not parallel your findings or if I can be of any further assistance please contact me.

Greg Kuhlman, DVM, DACVIM (SAIM)

Veterinary Internal Medicine Specialist
info@SonoPath.com