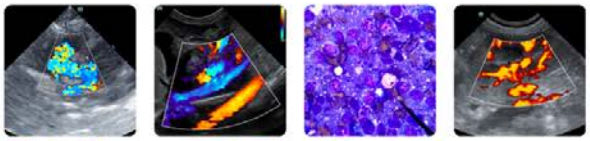

PATIENT
Neptune Elvin

SPECIES
Feline

BREED
Domestic Shorthair

SEX
Neutered Male

AGE
12 Years

WEIGHT
15.9 lbs

INTERPRETED BY
Greg Kuhlman, DVM, DACVIM (SAIM)

IMAGING PERFORMED BY
Dr. Varujan Belekdanian

HOSPITAL NAME
Overpeck Creek Animal Hospital

REFERRING VET
Dr. Varujan Belekdanian

INVOICE
73402

DATE
3/4/26

PRESENTING CLINICAL SIGNS

Neptune is a 12 year old MN DSH who presented for inappetence and lethargy for approximately 1 week. Upon presentation, patient was QAR, had acute abdominal pain upon palpation, as well as a 104.4 fever (repeatable). CBC/Chemistry/UA was run to show no major lab abnormalities aside from a cystatin B of 1,200 and mild neutrophilia. PLI came back normal. Patient's abdominal x rays did not show any major abnormalities either. An FUO PCR came back all negative, including FeLV/FIV.

Abnormal PE/Chem/CBC/UA Results: Cystatin B of 1,200 and mild neutrophilia

ULTRASONOGRAPHIC EXAMINATION OF THE ABDOMEN

Urinary System

The urinary blader contains a small amount of urine. The urine contains a small amount of hyperechoic debris. The bladder wall is normal in appearance and thickness. No masses are seen. Ureteral papillae are not seen.

The right kidney presents normal size (3.7 cm) with normal shape and architecture. Normal corticomedullary distinction. No pyelectasia, ureteral dilation or nephrolithiasis.

The left kidney presents normal size (3.95 cm) with normal shape and architecture. Normal corticomedullary distinction. No pyelectasia, ureteral dilation or nephrolithiasis.

Adrenal Glands

The right adrenal gland is not seen on this exam.

The left adrenal gland presents normal shape and homogenous parenchyma. The phrenic vasculature is unremarkable. The left adrenal gland measures 3.4 mm.

Spleen

The spleen is diffusely mildly enlarged, measuring 1.5 cm in width and has scalloped margins.

Liver

The liver presents normal size and shape with smooth lobar margins. The parenchyma has normal echogenicity with normal echotexture. No focal lesions are seen. Intrahepatic bile ducts are normal. Normal vascular pattern.

The gallbladder presents normal size with anechoic contents. Normal gallbladder wall. No evidence of bile duct distention or obstruction.

Gastrointestinal

The stomach and intestines have normal wall layering and thickness. Colon contains normal contents with normal wall thickness.

Pancreas

The pancreas is diffusely hypoechoic with dilated pancreatic ducts. No significant surrounding steatitis present.

PATIENT
Neptune Elvin

SPECIES
Feline

BREED
Domestic Shorthair

SEX
Neutered Male

AGE
12 Years

WEIGHT
15.9 lbs

INTERPRETED BY
Greg Kuhlman, DVM, DACVIM (SAIM)

IMAGING PERFORMED BY
Dr. Varujan Belekdanian

HOSPITAL NAME
Overpeck Creek Animal Hospital

REFERRING VET
Dr. Varujan Belekdanian

INVOICE
73402

DATE
3/4/26

Free Abdomen

No free abdominal fluid is seen.

There is an abdominal mass present that measures 2.9 cm x 2.5 cm. It is hypoechoic and irregularly shaped with areas that appear to be cavitated. There is a moderate amount of surrounding hyperechoic fat. Exact tissue of origin of this mass is not determined. The mass is in the area of the ileocolic junction.

In proximity of the abdominal mass there is an 8.6 mm x 14.2 mm hypoechoic, rounded lymph node present.

ULTRASONOGRAPHIC FINDINGS

- Abdominal mass – Differentials include most likely lymph node origin, possibly GI mass or pancreatic mass.
- Hypoechoic, rounded lymph node in the region of the abdominal mass – Most likely enlarged due to neoplasia. Round cell neoplasia or possibly metastatic neoplasia.
- Mildly enlarged, scalloped spleen – This may be consistent with infiltrative neoplasia such as lymphoma or mast cell disease.
- Mild reactive pancreatitis.

INTERPRETATION OF THE FINDINGS & FURTHER RECOMMENDATIONS

Recommend aspiration of the abdominal mass and submit for cytology. Also, if possible, attempt to perform ultrasound guided aspirate of the enlarged lymph node in the region of the abdominal mass and submit for cytology to rule out metastatic neoplasia.

Recommend a fine needle aspirate of the spleen, and submission for cytology to rule out round cell neoplasia.

If urinalysis has not been performed, recommend urinalysis. If active urine sediment, then recommend submitting a urine culture.

Recommend 3-view chest x-rays to rule out pulmonary metastatic disease.

No obvious cause for this patient's hyperthermia is seen on this exam. It is possible there are necrotic areas to the abdominal mass that may be leading to hyperthermia.

Prognosis is currently guarded pending results of cytology of the abdominal mass and lymph node.

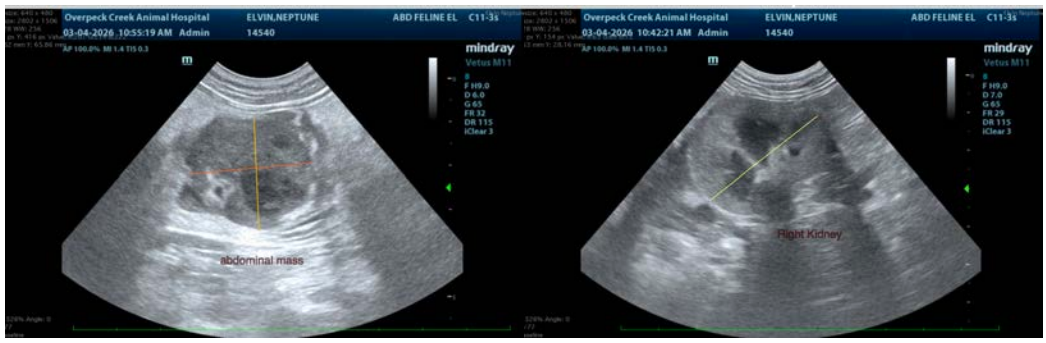

SonoPath
FOSTERING THE ART OF VETERINARY MEDICINE™



Clinical Sonography & Telecytology
Educational Teleconsultation Services™

SonoPath.com info@sonopath.com 1.800.838.4268

PATIENT

Neptune Elvin

SPECIES

Feline

BREED

Domestic Shorthair

SEX

Neutered Male

AGE

12 Years

WEIGHT

15.9 lbs

INTERPRETED BY

Greg Kuhlman, DVM, DACVIM (SAIM)

IMAGING PERFORMED BY

Dr. Varujan Belekdanian

HOSPITAL NAME

Overpeck Creek Animal Hospital

REFERRING VET

Dr. Varujan Belekdanian

INVOICE

73402

DATE

3/4/26

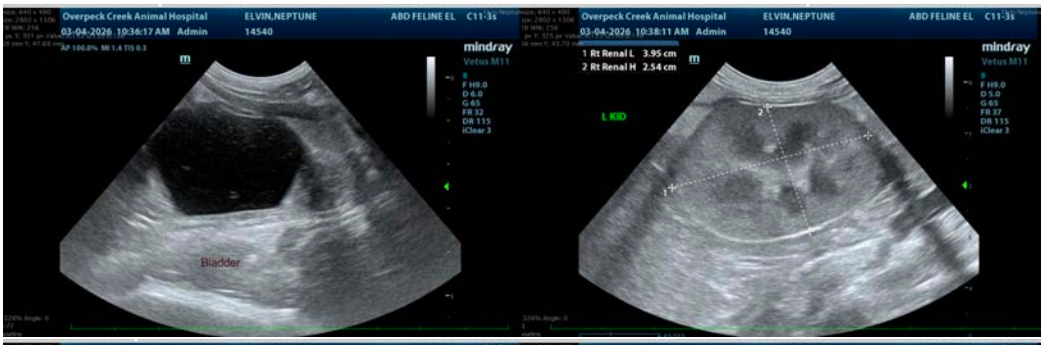

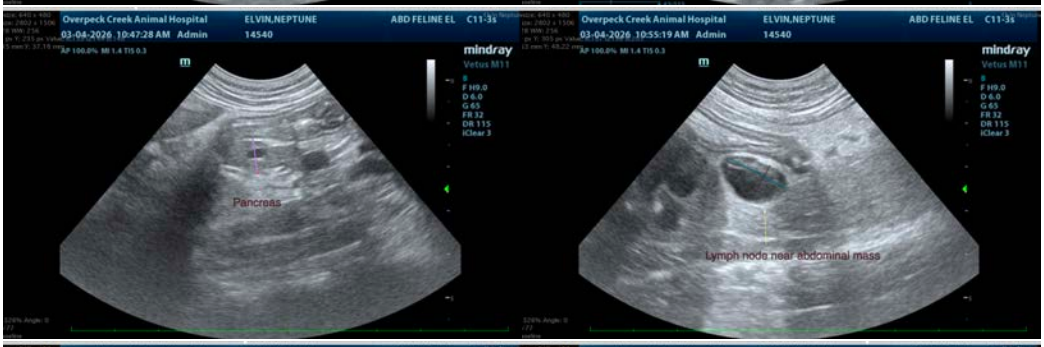

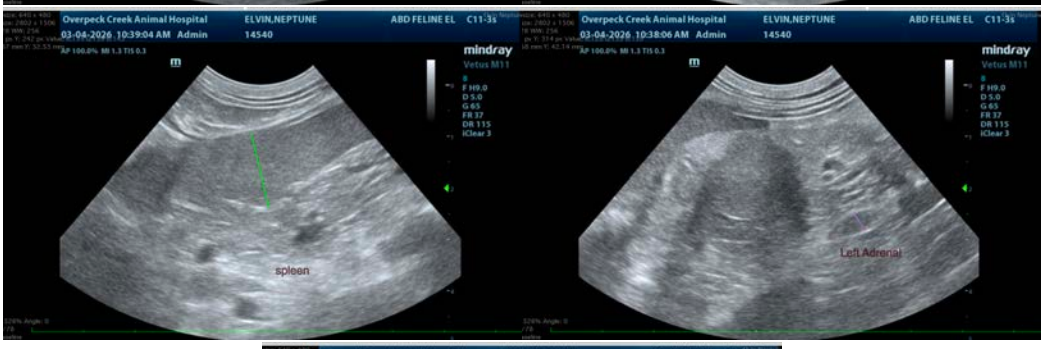



PATIENT

Neptune Elvin

SPECIES

Feline

BREED

Domestic Shorthair

SEX

Neutered Male

AGE

12 Years

WEIGHT

15.9 lbs

INTERPRETED BY

Greg Kuhlman, DVM, DACVIM (SAIM)

IMAGING PERFORMED BY

Dr. Varujan Belekdanian

HOSPITAL NAME

Overpeck Creek Animal Hospital

REFERRING VET

Dr. Varujan Belekdanian

INVOICE

73402

DATE

3/4/26

The information and recommendations provided are based on the images presented by the referring veterinarian/sonographer. No evaluation can be communicated regarding pathology that was not visible in the image/video clips provided.

Thank you for this referral. If the clinical or image interpretation does not parallel your findings or if I can be of any further assistance please contact me.

Greg Kuhlman, DVM, DACVIM (SAIM)

Veterinary Internal Medicine Specialist
info@SonoPath.com