



## PATIENT

Gizmo Acton

## SPECIES

Feline

## BREED

DSH

## SEX

MN

## AGE

8 years

## WEIGHT

15 lbs

## INTERPRETED BY

Greg Kuhlman, DVM,  
DACVIM (SAIM)

## IMAGING PERFORMED BY

Dr. Julia Bakker

## HOSPITAL NAME

Orange Blossom  
Veterinary Imaging

## REFERRING VET

Dr. Madison Wilson

## INVOICE

11575

## DATE

3/27/2026

## PRESENTING CLINICAL SIGNS

- Persistent vomiting despite symptomatic care.
- Unremarkable labwork and radiographs, FPL neg.
- Patient difficult to medicate orally.
- Reduced appetite and still vomiting.

## ULTRASONOGRAPHIC EXAMINATION OF THE ABDOMEN

### Urinary System

The bladder is moderately distended with anechoic urine. No uroliths are seen. The bladder wall is normal in appearance and thickness. No masses are seen. Ureteral papillae is not visualized.

The left kidney presents normal size with normal shape and architecture. Normal corticomedullary distinction. No pyelectasia, ureteral dilation or nephrolithiasis. The left kidney measured 4.1 cm in length.

The right kidney presents normal size with normal shape and architecture. Normal corticomedullary distinction. No pyelectasia, ureteral dilation or nephrolithiasis. The right kidney measured 4.3 cm in length.

### Adrenal Glands

The left adrenal gland presents normal shape and homogenous parenchyma. The phrenic vasculature is unremarkable. The left adrenal measures 4.3 mm in width.

The right adrenal gland presents normal shape and homogenous parenchyma. The phrenic vasculature is unremarkable. The right adrenal measures up to 5.4 mm in width at the cranial pole, and 3.3 mm at the caudal pole.

### Spleen

The spleen is normal in size, shape, margination and echogenicity. Multifocal hyperechoic non-capsular displacing lesions throughout the spleen, suspected to be benign myelolipomas. Normal splenic blood flow.

### Liver

The liver presents normal size and shape with smooth lobar margins. The parenchyma has normal echogenicity with normal echotexture. No focal lesions are seen. Intrahepatic bile ducts are normal. Normal vascular pattern.

The gallbladder presents normal size with anechoic contents. Normal gallbladder wall. No evidence of bile duct distention or obstruction.

### Gastrointestinal

The stomach has normal wall layering and thickness.

The visible small intestine demonstrates areas of prominently thick muscularis layer relative to mucosa (disruption of the normal 1:3 muscularis:mucosa ratio). Small intestinal submucosa is slightly irregular,



## PATIENT

Gizmo Acton

## SPECIES

Feline

## BREED

DSH

## SEX

MN

## AGE

8 years

## WEIGHT

15 lbs

## INTERPRETED BY

Greg Kuhlman, DVM,  
DACVIM (SAIM)

## IMAGING PERFORMED BY

Dr. Julia Bakker

## HOSPITAL NAME

Orange Blossom  
Veterinary Imaging

## REFERRING VET

Dr. Madison Wilson

## INVOICE

11575

## DATE

3/27/2026

thick and hyperechoic, without evident loss of layering appreciated. The lumen of the small intestine is with no evidence of obstruction or foreign material. Jejunum measures up to 4.2 mm in width, normal feline intestines should measure less than 2.8 mm in width.

Colon contains normal contents with normal wall thickness.

### **Pancreas**

The visible pancreas is normal in size with normal echogenic parenchyma and surrounded by normal peri-pancreatic mesentery.

### **Free Abdomen**

There are no enlarged abdominal lymph nodes seen on this exam. No free abdominal fluid is seen.

## ULTRASONOGRAPHIC FINDINGS

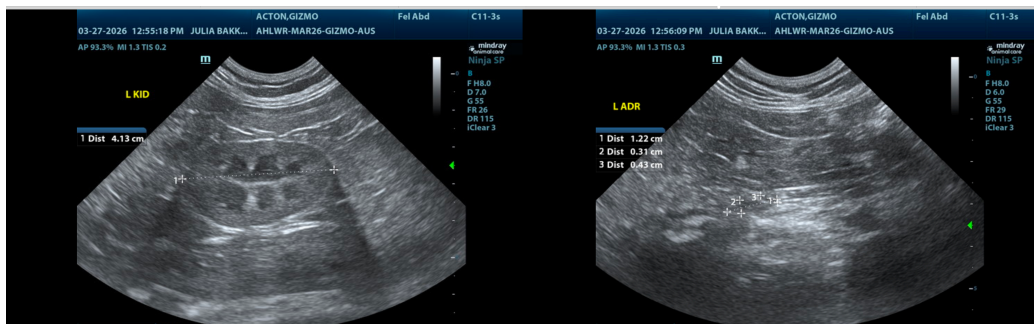
- Multifocal hyperechoic non-capsular displacing lesions throughout the spleen – Suspect benign myelolipomas.
- Moderate inflammatory bowel disease (IBD) pattern – Thick muscularis has been reported with infiltrative bowel disease including both benign inflammatory disease as well as infiltrative neoplasia such as lymphoma. No loss of layering or distinct characteristics of malignancy are present. Therefore, differentials cannot be further ranked without tissue sampling.

## INTERPRETATION OF THE FINDINGS & FURTHER RECOMMENDATIONS

Patient's vomiting most likely caused by primary GI disease, either small cell lymphoma, mast cell disease, possibly a benign process such as inflammatory bowel disease or an infectious disease such as histoplasmosis (if geographically relevant.) Consider a GI panel to Texas A&M for a qualitative fPLI/TLI, cobalamin, and folate to determine if supplementation is necessary, and to determine chronic enteropathy. Also recommend GI biopsies, either surgically or endoscopically.

If histoplasmosis is geographically relevant than I recommend a urine antigen testing to rule out histoplasmosis prior to considering GI biopsies.

Recommend treatment supportively pending further diagnostics.





## PATIENT

Gizmo Acton

## SPECIES

Feline

## BREED

DSH

## SEX

MN

## AGE

8 years

## WEIGHT

15 lbs

## INTERPRETED BY

Greg Kuhlman, DVM,  
DACVIM (SAIM)

## IMAGING PERFORMED BY

Dr. Julia Bakker

## HOSPITAL NAME

Orange Blossom  
Veterinary Imaging

## REFERRING VET

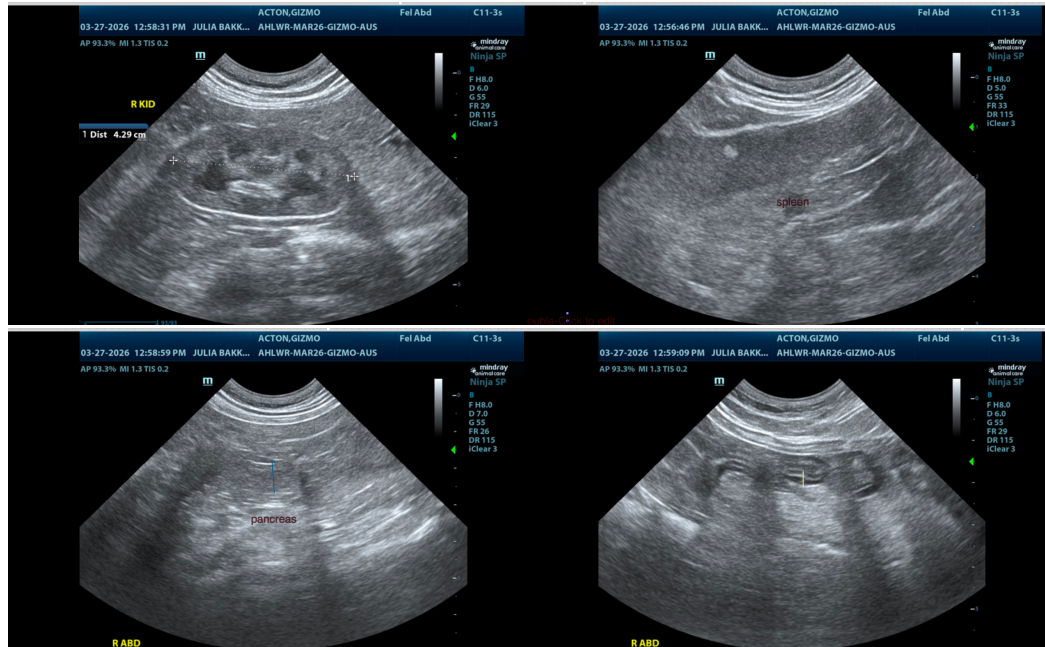
Dr. Madison Wilson

## INVOICE

11575

## DATE

3/27/2026



The information and recommendations provided are based on the images presented by the referring veterinarian/sonographer. No evaluation can be communicated regarding pathology that was not visible in the image/video clips provided.

Thank you for this referral. If the clinical or image interpretation does not parallel your findings or if I can be of any further assistance, please contact me.

Greg Kuhlman, DVM, DACVIM (SAIM)

Veterinary Internal Medicine Specialist  
[info@SonoPath.com](mailto:info@SonoPath.com)