

**PATIENT**

Scooter Bond

SPECIES

Canine

BREED

Maltese

SEX

Neutered Male

AGE

14 Years 3 Months

WEIGHT

5.7 kg

INTERPRETED BYGreg Kuhlman, DVM,
DACVIM (SAIM)**IMAGING
PERFORMED BY**

Dr. Jill Rankin

HOSPITAL NAMEWoodlands Veterinary
Hospital**REFERRING VET**

Tom DeBoldus, DVM

INVOICE

73803

DATE

3/18/26

PRESENTING CLINICAL SIGNS

Scooter presents for an ultrasound evaluation to investigate a history of mild hypercalcemia and a perianal mass. The primary goals are to assess for metastatic disease from the suspected tumor and hypercalcemia.

The patient has a firm, irregular mass measuring less than a centimeter on the right side of the anus, which is suspected (but not confirmed) to be an anal sac adenocarcinoma (FNA samples have not yet been collected). This mass is believed to have caused a recent anal sac rupture by obstructing the gland. An abdominal ultrasound was requested to check for evidence of metastasis to the sublumbar lymph nodes, which would impact the decision to proceed with surgical removal of the mass.

For approximately two years, the patient has had mild, stable hypercalcemia with levels around 3.0. Lab work has shown no evidence of kidney disease.

ULTRASONOGRAPHIC EXAMINATION OF THE ABDOMEN**Urinary System**

The urinary bladder contains a small amount of urine at this time. The bladder wall is diffusely variably thickened. The cranioventral aspect measures 3.8 mm in width. The dorsal mid aspect measures 2.0 mm in width. The luminal margin of the urinary bladder is mildly irregular in texture.

The prostate appears symmetrical and has uniform echogenicity. Within the prostatic urethra there are approximately hyperechoic suspected ureteroliths present that measure approximately 0.90-1.0 mm in diameter. No obstruction of the urethra apparent at this time. The urinary bladder does not appear obstructed.

The right kidney is diffusely hyperechoic with moderate to marked loss of corticomedullary distinction, measuring 4.3 cm in length. Renal pelvic dilation noted at 3.1 mm in width.

The left kidney is diffusely hyperechoic with several benign cortical cysts present. The left kidney measures 4.1 cm in length. Renal pelvis is dilated at 6.9 mm in width.

Adrenal Glands

In the area of the right adrenal gland there is a 1.56 cm x 3.0 cm hypoechoic mass lesion present. There is also a hypoechoic structure present that appears to be the cranial pole of the right adrenal gland measuring 4.3 mm in width. The cranial pole has a hyperechoic nodule that measures 4.7 mm in width, most likely an incidental finding. The caudal pole is not clearly seen.

The left adrenal gland presents normal shape and homogenous parenchyma. The phrenic vasculature is unremarkable. The cranial pole measures 6.0 mm and the caudal pole measures 4.2 mm.

Spleen

The spleen is normal in size and echogenicity with diffuse hyperechoic foci noted throughout the spleen, suspected to be benign myelolipomas. In the body of the spleen there is a 2.9 mm non-capsule displacing hypoechoic cyst that appears benign and not clinically significant.



PATIENT

Scooter Bond

SPECIES

Canine

BREED

Maltese

SEX

Neutered Male

AGE

14 Years 3 Months

WEIGHT

5.7 kg

INTERPRETED BY

Greg Kuhlman, DVM,
DACVIM (SAIM)

IMAGING PERFORMED BY

Dr. Jill Rankin

HOSPITAL NAME

Woodlands Veterinary
Hospital

REFERRING VET

Tom DeBoldus, DVM

INVOICE

73803

DATE

3/18/26

Liver

The liver is enlarged with rounded margins and a hyperechoic echogenicity. Diffusely throughout the liver there are multiple benign appearing cystic lesions. A representative cyst near the gallbladder measures 1.1 cm x 0.60 cm. No mass lesions are associated with these cystic lesions.

The gallbladder contains a marked amount of suspended echogenic debris.

Gastrointestinal

The stomach and intestines have normal wall layering and thickness. Colon contains normal contents with normal wall thickness.

Pancreas

The pancreas is mildly hypoechoic with no surrounding hyperechoic fat. Throughout the parenchyma there are hyperechoic striations present, consistent with possible fibrosis.

Free Abdomen

Prominent sublumbar lymph nodes are present. A representative node measures 3.8 mm x 10 mm. No free abdominal fluid is seen.

ULTRASONOGRAPHIC FINDINGS

- Mass in the area of the right adrenal gland – Tissue of origin cannot be clearly determined on this ultrasound. Differentials include either enlarged abdominal lymph node or right adrenal gland mass. The right adrenal gland itself is not definitively identified on this scan.
- Bilateral decreased corticomedullary distinction and renal pelvic dilation.
- Ureteroliths in the prostatic urethra.
- Thickened areas and irregular luminal margin of the urinary bladder – These findings do not appear to be due to neoplasia. Most likely possible chronic urinary tract infection. Recommend submitting urine culture to rule out UTI.

INTERPRETATION OF THE FINDINGS & FURTHER RECOMMENDATIONS

Given that the mass in the area of the right adrenal gland could potentially be adrenal in origin, it is not recommended to perform a fine needle aspirate. Recommend CT scan of the abdomen to better characterize the tissue of origin of this mass. If it is a right adrenal gland mass, then right adrenalectomy would be recommended. If it does appear to be an enlarged lymph node, then fine needle aspirate at that time would be recommended to determine cause of enlargement.

The patient appears to have chronic kidney disease based on this ultrasound. Recommend full staging, monitoring and management per IRIS guidelines.

Regarding the ureteroliths, recommend starting strict dissolution diet and rechecking ultrasound in 2-3 months to determine if stones have resolved. If they remain present, consider cystotomy to remove stones and submit for urolith analysis.



PATIENT

Scooter Bond

SPECIES

Canine

BREED

Maltese

SEX

Neutered Male

AGE

14 Years 3 Months

WEIGHT

5.7 kg

INTERPRETED BY

Greg Kuhlman, DVM,
DACVIM (SAIM)

IMAGING PERFORMED BY

Dr. Jill Rankin

HOSPITAL NAME

Woodlands Veterinary
Hospital

REFERRING VET

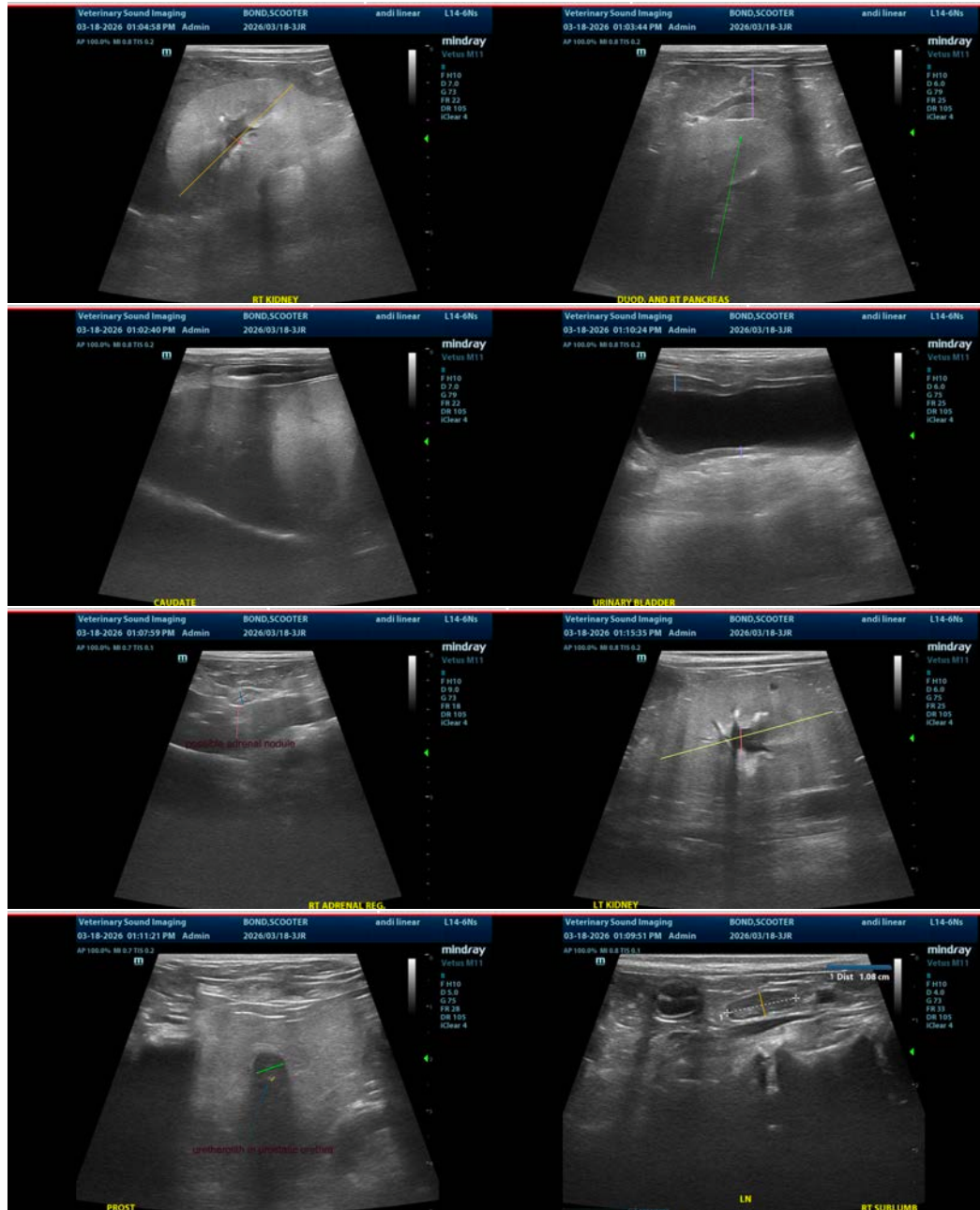
Tom DeBoldus, DVM

INVOICE

73803

DATE

3/18/26





PATIENT

Scooter Bond

SPECIES

Canine

BREED

Maltese

SEX

Neutered Male

AGE

14 Years 3 Months

WEIGHT

5.7 kg

INTERPRETED BY

Greg Kuhlman, DVM,
DACVIM (SAIM)

IMAGING PERFORMED BY

Dr. Jill Rankin

HOSPITAL NAME

Woodlands Veterinary
Hospital

REFERRING VET

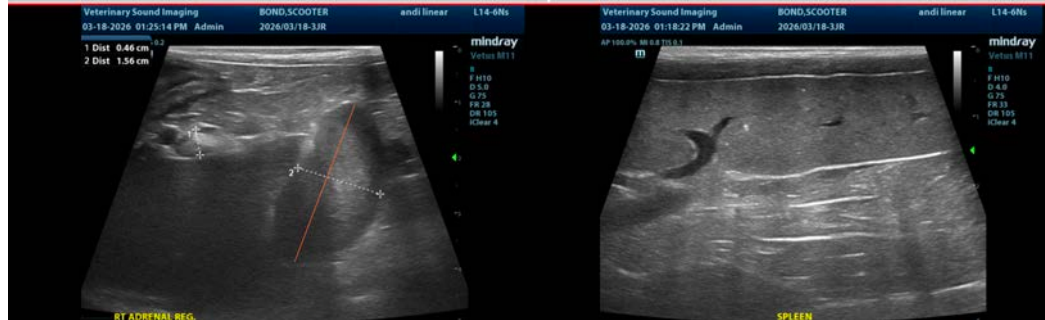Tom DeBoldus, DVM

INVOICE

73803

DATE

3/18/26



The information and recommendations provided are based on the images presented by the referring veterinarian/sonographer. No evaluation can be communicated regarding pathology that was not visible in the image/video clips provided.

Thank you for this referral. If the clinical or image interpretation does not parallel your findings or if I can be of any further assistance please contact me.

Greg Kuhlman, DVM, DACVIM (SAIM)

Veterinary Internal Medicine Specialist
info@SonoPath.com