



PATIENT

Apollo Gonzalez

SPECIES

Canine

BREED

Bulldog x

SEX

Neutered Male

AGE

9

WEIGHT

46.2

INTERPRETED BY

Greg Kuhlman, DVM,
DACVIM (SAIM)

IMAGING PERFORMED BY

Dr. Cecilia Fisher

HOSPITAL NAME

Cape Coral Pet Vet

REFERRING VET

Dr. Cecilia Fisher

INVOICE

72828

DATE

2/10/26

PRESENTING CLINICAL SIGNS

Senior Screening.

ULTRASONOGRAPHIC EXAMINATION OF THE ABDOMEN

Urinary System

The bladder is moderately distended with anechoic urine. No uroliths are seen. The bladder wall is normal in appearance and thickness. No masses are seen.

The right kidney presents normal size (5.9 cm) with normal shape and architecture. Normal corticomedullary distinction. No pyelectasia, ureteral dilation or nephrolithiasis.

The left kidney presents normal size (6.5 cm) with normal shape and architecture. Normal corticomedullary distinction. No pyelectasia, ureteral dilation or nephrolithiasis.

Adrenal Glands

The right adrenal gland presents normal shape and homogenous parenchyma. The phrenic vasculature is unremarkable. The cranial pole measures 5.9 mm and the caudal pole measures 6.0 mm.

The left adrenal gland presents normal shape and homogenous parenchyma. The phrenic vasculature is unremarkable. The cranial pole measures 7.1 mm and the caudal pole measures 6.5 mm.

Spleen

The spleen is normal in size, shape, margination and echogenicity. No masses are seen.

Liver

The liver presents normal size and shape with smooth lobar margins. The parenchyma has normal echogenicity with normal echotexture. No focal lesions are seen. Intrahepatic bile ducts are normal. Normal vascular pattern.

The gallbladder presents normal size with anechoic contents. Normal gallbladder wall. No evidence of bile duct distention or obstruction.

Gastrointestinal

The stomach and intestines have normal wall layering and thickness. Colon contains normal contents with normal wall thickness.

Pancreas

The visible pancreas is normal in size with normal echogenic parenchyma and surrounded by normal peri-pancreatic mesentery.

Free Abdomen

There are no enlarged abdominal lymph nodes seen on this exam. No free abdominal fluid is seen.

ULTRASONOGRAPHIC FINDINGS

- This is an apparently normal abdominal ultrasound with no pathologic findings.



PATIENT

Apollo Gonzalez

SPECIES

Canine

BREED

Bulldog x

SEX

Neutered Male

AGE

9

WEIGHT

46.2

INTERPRETED BY

Greg Kuhlman, DVM,
DACVIM (SAIM)

IMAGING PERFORMED BY

Dr. Cecilia Fisher

HOSPITAL NAME

Cape Coral Pet Vet

REFERRING VET

Dr. Cecilia Fisher

INVOICE

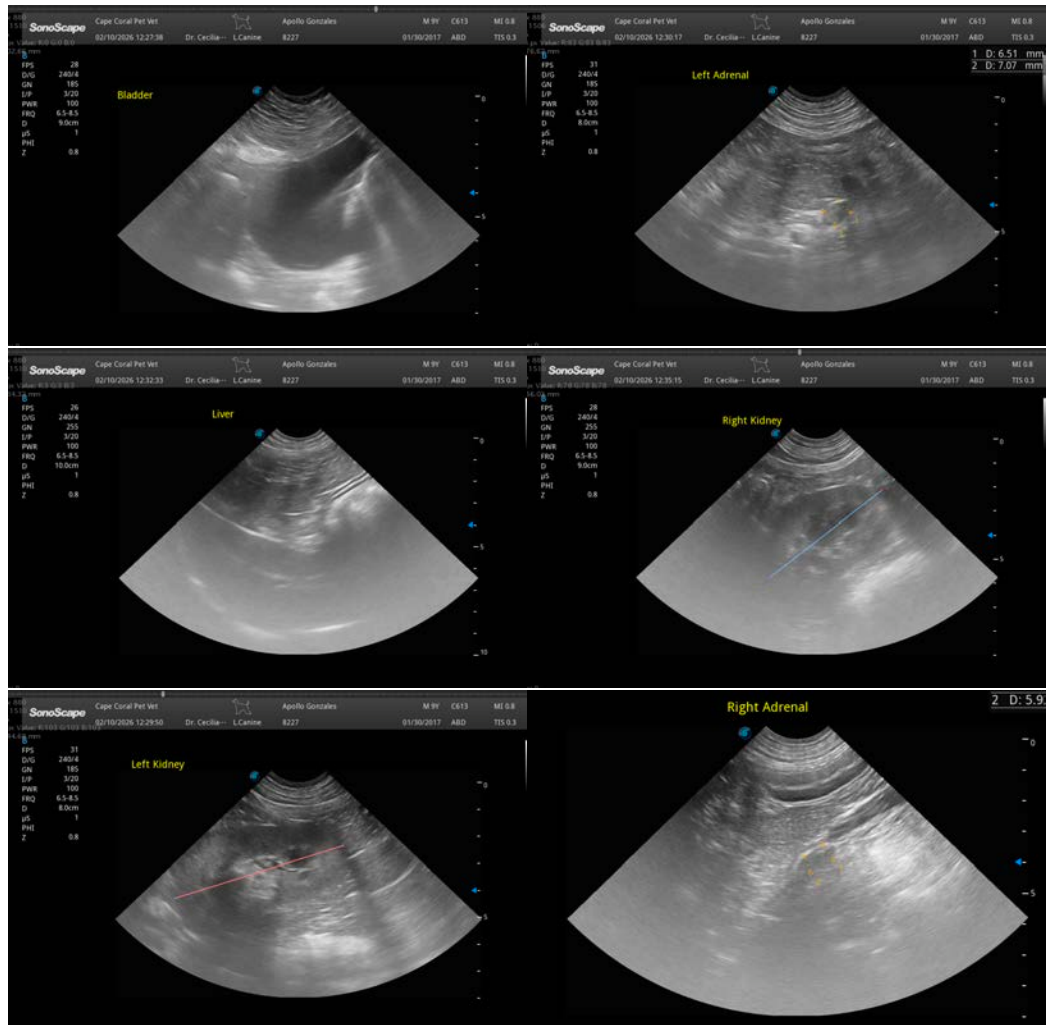
72828

DATE

2/10/26

INTERPRETATION OF THE FINDINGS & FURTHER RECOMMENDATIONS

No specific recommendations are made at this time unless clinical signs of disease are present.



The information and recommendations provided are based on the images presented by the referring veterinarian/sonographer. No evaluation can be communicated regarding pathology that was not visible in the image/video clips provided.

Thank you for this referral. If the clinical or image interpretation does not parallel your findings or if I can be of any further assistance please contact me.

Greg Kuhlman, DVM, DACVIM (SAIM)
Veterinary Internal Medicine Specialist
info@SonoPath.com