

DATE PRESENTING CLINICAL SIGNS

8/14/21 Articular swelling of carpi

INTERPRETED BY CYTOLOGY SUBMISSION

L.D. McGill, DVM, Ph.D, DACVP U/S Guided FNA: Bilateral carpal joints

OBSERVATIONS

PATIENT

Fenway Sullivan

Right carpus: Submitted are 2 videos of minimal numbers of cells collected from the right carpus on Fenway. The cellularity is consistent with scattered synovial cells and mononuclear cells. The collection is very clean with very few RBCs. Other cells such as neutrophils are not identified.
Left carpus: Submitted are 3 videos of minimal numbers of cells collected from the left carpus on Fenway. The cellularity is very similar to the cells collected from the right carpus: synovial cells and mononuclear cells.

SPECIES

Canine

INTERPRETATION OF THE FINDINGS & FURTHER RECOMMENDATIONS

Right and Left carpal joint collections - Nonsuppurative synovitis.

BREED

Retriever mix

COMMENTS

The cellularity is characteristic of degenerative or traumatic synovial injury. It is not immune mediated. This type of cellularity supports trauma with synovial cell proliferation and a few lymphocytes. In the dog, lymphocytic stimulation occurs with degeneration or trauma. There is no suggestion of sepsis in this collection either. Both joints show the same cellularity with very few cells. The collections are very clean with very few RBCs.

AGE

9y

WEIGHT

61lbs

HOSPITAL NAME

Rockaway Animal Hospital

REFERRING VET

Kahn

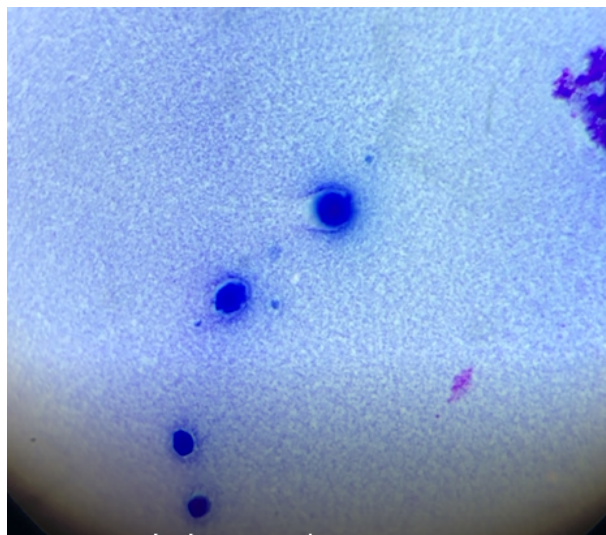
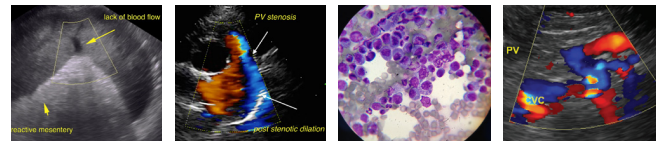


Image shows cells from the right carpus with synovial cells and lymphocytes and normal surrounding synovial fluid.

INVOICE NUMBER

9074



DATE

8/14/21

INTERPRETED BY

L.D. McGill, DVM,
Ph.D., DACVP

PATIENT

Fenway Sullivan

SPECIES

Canine

BREED

Retriever mix

SEX

Male Neutered

AGE

9y

WEIGHT

61lbs

HOSPITAL NAME

Rockaway Animal
Hospital

REFERRING VET

Kahn

INVOICE NUMBER

9074

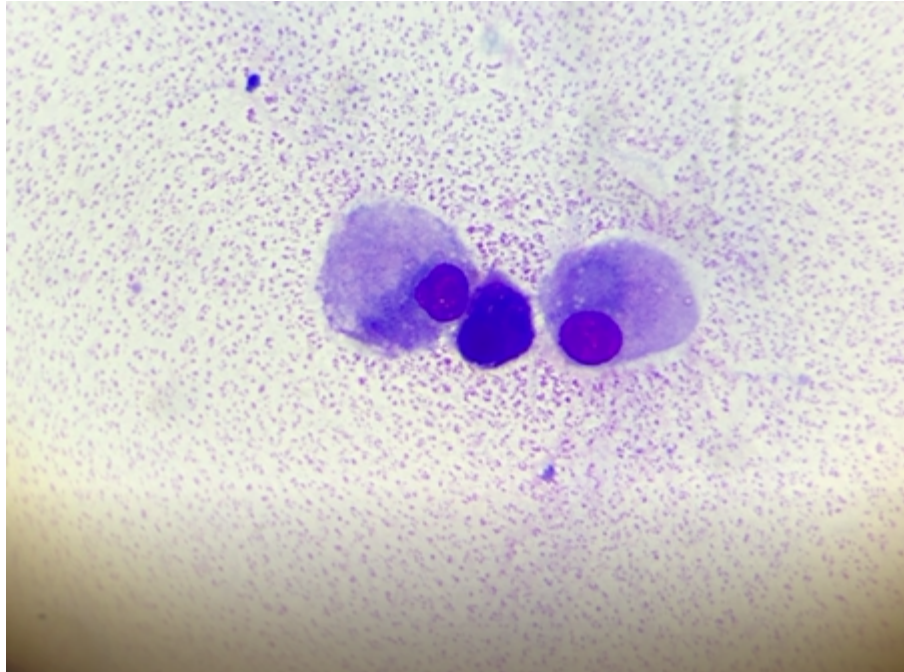


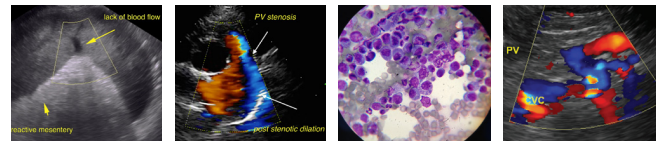
Image shows synovial cells and a lymphocyte with clear surrounding synovial fluid.

The information and recommendations provided are based on the images presented by the referring veterinarian. No evaluation can be communicated regarding pathology that was not visible in the image/video clips provided.

Thank you for this referral. If the clinical or image interpretation does not parallel your findings or if I can be of any further assistance please contact me.

L.D. McGill, DVM, Ph.D., DACVP

8288 Top of the World Drive
Cottonwood Heights, UT 84121
ldmcgill.vetpath@gmail.com
cell: 801-865-1220



DATE

8/14/21

INTERPRETED BY

L.D. McGill, DVM,
Ph.D, DACVP

PATIENT

Fenway Sullivan

SPECIES

Canine

BREED

Retriever mix

SEX

Male Neutered

AGE

9y

WEIGHT

61lbs

HOSPITAL NAME

Rockaway Animal
Hospital

REFERRING VET

Kahn

INVOICE NUMBER

9074