



PATIENT

Grace Wyczynski

SPECIES

Canine

BREED

Mixed

SEX

Spayed Female

AGE

8

WEIGHT

73.4

INTERPRETED BY

Eric Lindquist, DMV,
DABVP (CFM), Cert.
IVUSS

IMAGING PERFORMED BY

Chelsea Pastor

HOSPITAL NAME

Fredon AH

REFERRING VET

Dr. Michelle Roche

INVOICE

35034

DATE

12/22/25

PRESENTING CLINICAL SIGNS

History: MCT removed last year, grade 2. Has many new growths, weight loss, decreased appetite
Abnormal PE/Chem/CBC/UA Results: CBC: HCT 22, WBC 4.6 non regenerative CHEM wnl.

ULTRASONOGRAPHIC EXAMINATION OF THE ABDOMEN

Urinary System

The **urinary bladder**, trigone, and pelvic urethra presented normal thicknesses and normal tone. The ureters were not visible which is normal. No uroliths or sediment were visualized and anechoic urine was present. No evidence of inflammatory or neoplastic changes was noted. Ureteral papillae were normal.

The **kidneys** revealed normal size and structure, corticomedullary definition and ratio for this age. The cortices presented largely uniform texture with normal echogenic relationship to liver and spleen. Medullary structure differed distinctly from the cortex, and no evidence of pelvic dilation was present. The capsules were acceptably uniform without significant irregularities. The left kidney measured 6.16 cm. The right kidney measured 7.3 cm.

Adrenal Glands

The **left adrenal gland** was visualized and recognized as having normal shape, size, position and echogenicity for this breed. The phrenic vasculature, glandular echogenicity and detail were unremarkable. Capsule, cortex, and medullary definition were normal for this age patient. The left adrenal gland measured 0.7 cm.

The region of the **right adrenal gland** was imaged and revealed no evident pathology.

Spleen

The **spleen** was mildly enlarged with subtle micronodular changes. The spleen measured 2.33 cm in width.

Liver

The **liver** images submitted revealed subjectively normal liver size, contour, and structure. Parenchymal echogenicity was naturally coarse and hypoechoic to the spleen. Vascular and biliary tracts were of normal volume with no evidence of congestion. The gallbladder presented acceptably thin walls with primarily anechoic content. The cystic and common bile ducts were normal. No pathological hepatic lymphadenopathy was evident. No overt structural evidence of inflammatory, infiltrative or regenerative pathology was evident.

Gastrointestinal

Examination of the **gastrointestinal tract** revealed a stomach and intestine free of stasis, of normal wall thickness, acceptable curvilinear mural detail, and peristaltic activity. Small and large intestine demonstrated normal luminal chyme and stool consistency respectively. No obstructive or overt infiltrative disease was noted. No associated abnormal lymphatic activity was noted.

Pancreas



PATIENT

Grace Wyczynski

SPECIES

Canine

BREED

Mixed

SEX

Spayed Female

AGE

8

WEIGHT

73.4

INTERPRETED BY

Eric Lindquist, DMV,
DABVP (CFM), Cert.
IVUS

IMAGING PERFORMED BY

Chelsea Pastor

HOSPITAL NAME

Fredon AH

REFERRING VET

Dr. Michelle Roche

INVOICE

35034

DATE

12/22/25

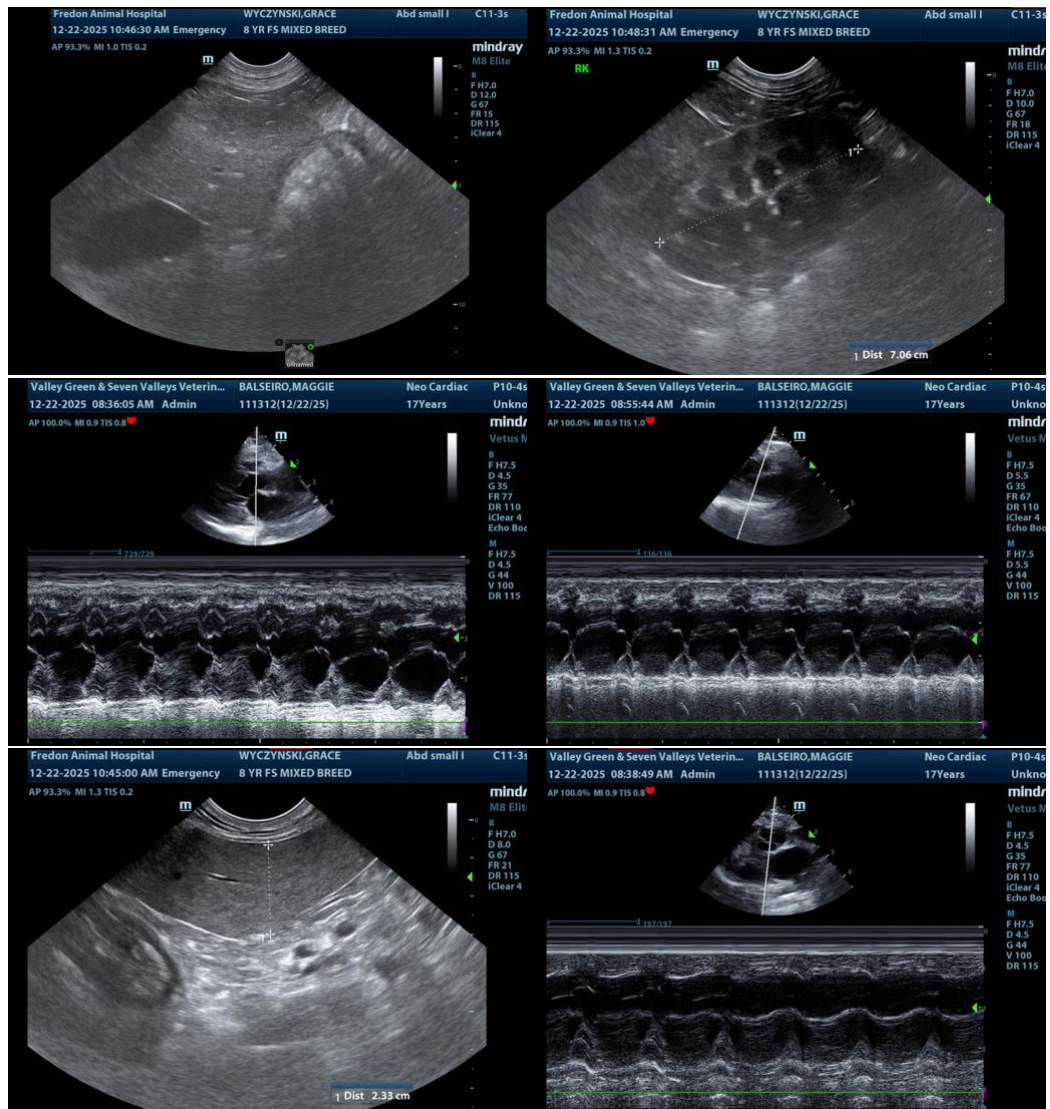
The base and limbs of the **pancreas** were observed to be largely isoechoic to surrounding omental fat. Pancreatic duct and capsular contour were acceptably normal and parenchyma respected normal curvilinear patterns. No overt evidence of active inflammatory or neoplastic disease was noted.

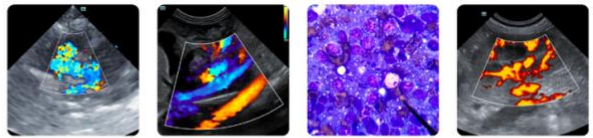
ULTRASONOGRAPHIC FINDINGS

- Mild splenic enlargement – reactive spleen, hyperplasia versus emerging round cell neoplasia are all possibilities.
- Structurally unremarkable abdomen otherwise.

INTERPRETATION OF THE FINDINGS & FURTHER RECOMMENDATIONS

FNA of the spleen is indicated given the patient history and clinical profile. Otherwise, unremarkable abdomen.





PATIENT

Grace Wyczynski

SPECIES

Canine

BREED

Mixed

SEX

Spayed Female

AGE

8

WEIGHT

73.4

INTERPRETED BY

Eric Lindquist, DMV,
DABVP (CFM), Cert.
IVUSS

IMAGING PERFORMED BY

Chelsea Pastor

HOSPITAL NAME

Fredon AH

REFERRING VET

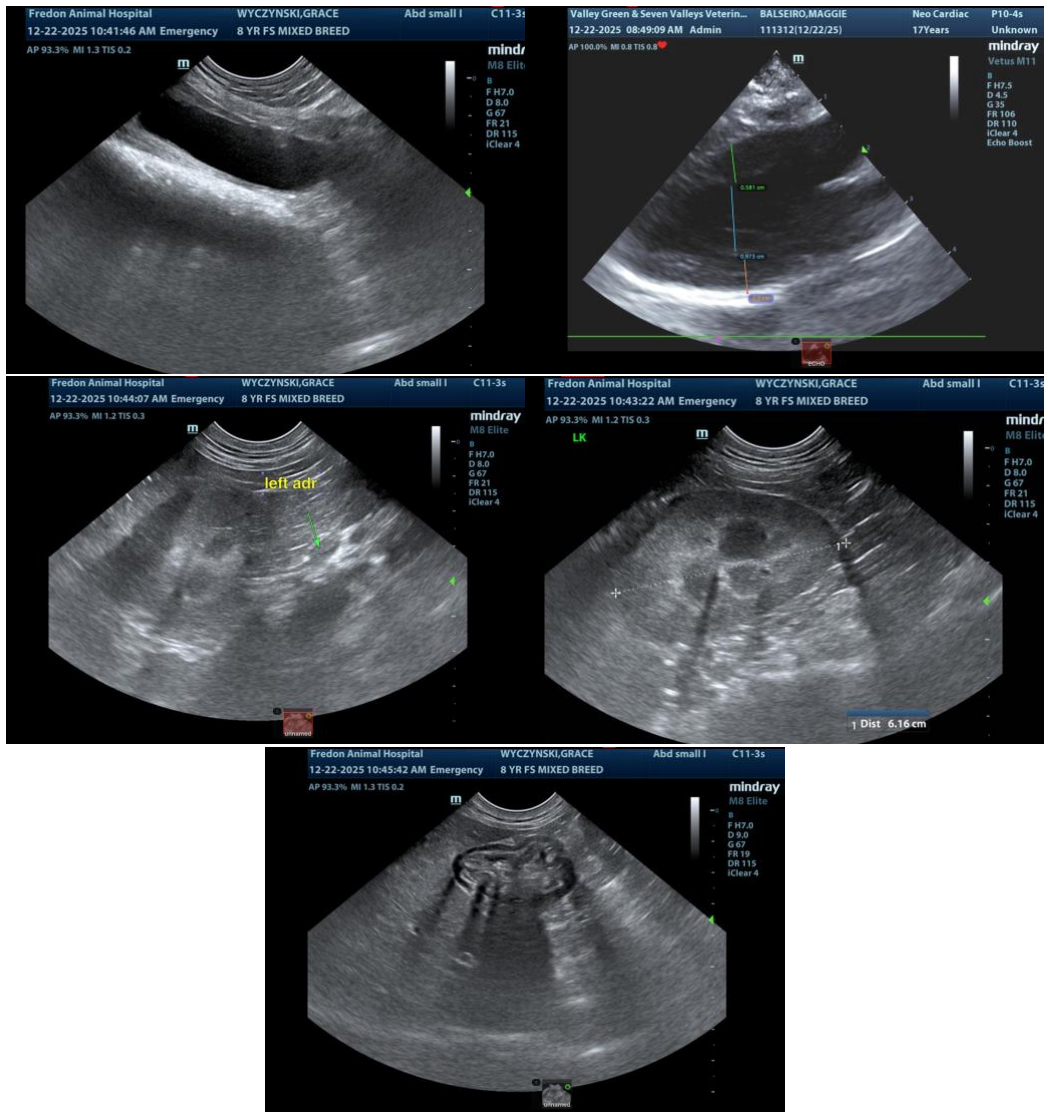
Dr. Michelle Roche

INVOICE

35034

DATE

12/22/25



The information and recommendations provided are based on the images presented by the referring veterinarian/sonographer. No evaluation can be communicated regarding pathology that was not visible in the image/video clips provided.

Thank you for this referral. If the clinical or image interpretation does not parallel your findings or if I can be of any further assistance please contact me.

Eric Lindquist, DMV, DABVP(CFM), Cert. IVUSS,
CEO, Owner, Founder -- SonoPath.com
info@SonoPath.com