



PATIENT

Lacey Pohlman

SPECIES

Canine

BREED

Mini Poodle

SEX

Spayed Female

AGE

13 Years

WEIGHT

13.1 Pounds

INTERPRETED BY

Eric Lindquist, DMV,
 DABVP(CFM), Cert.
 IVUSS

IMAGING PERFORMED BY

Meghan Morse, LVT,
 CVT

HOSPITAL NAME

Newton VH

REFERRING VET

Dr. Chabora

INVOICE

35619

DATE

11/24/25

PRESENTING CLINICAL SIGNS

History: Abdominal distension, v+, enlarged liver and spleen Current meds: Denamarin
 Abnormal PE/Chem/CBC/UA Results: 10/3/25: Glob 3.8, ALT 229, ALP 1076, PSL 395

ULTRASONOGRAPHIC EXAMINATION OF THE HEART & ABDOMEN

CANINE CARDIAC PARAMETERS	MR VMAX (m/s)	TR VMAX (m/s)	LA/AO (M-Mode)	LA/AO (Heart Base; Swe)	FS (%)	EF (%)	EPSS (cm)
NORMAL PARAMETER	4.5-5.5	<2.7	1.3	Up to 1.6	28-40	40-100	<0.6
PATIENT	6.0	--	1.1	1.27	52	85	NM
CANINE CARDIAC PARAMETERS	HR (BPM)	AV VMAX (m/s)	PV MAX (m/s)	BODY WEIGHT (lbs)	LAD LA MAX 4 Chamber	LVIDd Avg; 2D and m-mode short axis (cm)	LVIDs Avg; 2D and m-mode short axis (cm)
NORMAL PARAMETER	50-100	0.7-1.7	0.7-1.6				
PATIENT	80	1.48	.90	13.1	2.5	2.6	--

Cardiac Presentation

The echocardiogram in this patient demonstrated normal **left atrial** size based on 3 different LA measurement methods. Chamber volumes and echogenicity were normal. The cranial and caudal **mitral** valve leaflets presented vegetative thickening consistent with endocardiosis. Doppler indicated measurable insufficiency. The **left ventricle** presented thicknesses with linear contour and was not dilated nor restricted. The **myocardium** presented normal echogenicity without subjective evidence of significant fibrotic or ischemic disease. **Contractility** of the ventricular walls was adequate and in normal range for this patient evidenced by the fractional shortening measurement and subjective evaluation of the different regions of the myocardium. The **left ventricular outflow** tract demonstrated normal laminar flow and subjective structural integrity. The **right atrium** and auricle revealed normal size, structure and content. No evidence of masses was noted or chamber overload. **Tricuspid** valvular assessment demonstrated adequate linear morphology. The **right ventricle** was of normal size (1/3 diameter of LV), chordae structure, myocardial echogenicity and thickness. **Pulmonic** tract assessment revealed normal valve structure, laminar flow, and diameter (approx.1:1 pa/ao ratio). Persistent arrhythmia was noted in this patient. Holter monitor may be obtained from our office.

Urinary System



PATIENT

Lacey Pohlman

SPECIES

Canine

BREED

Mini Poodle

SEX

Spayed Female

AGE

13 Years

WEIGHT

13.1 Pounds

INTERPRETED BY

Eric Lindquist, DMV,
DABVP(CFM), Cert.
IVUSS

IMAGING PERFORMED BY

Meghan Morse, LVT,
CVT

HOSPITAL NAME

Newton VH

REFERRING VET

Dr. Chabora

INVOICE

35619

DATE

11/24/25

The **urinary bladder**, trigone, and pelvic urethra presented normal thicknesses and normal tone. The ureters were not visible which is normal. No uroliths or sediment were visualized and anechoic urine was present. No evidence of inflammatory or neoplastic changes was noted. Ureteral papillae were normal. The pelvic urethra was imaged 2.0 cm beyond the cystourethral junction.

The **kidneys** revealed largely normal size and structure, corticomedullary definition and ratio (cortex 1/3 of medulla) were essentially maintained with some moderate age-related loss of curvilinear patterns regarding the capsule and C/M junction. The cortices presented largely uniform texture with some increased echogenicity expected for this age patient. Medullary structure differed distinctly from that of the cortex, and no evidence of pelvic dilation was present. The right kidney measured 5.02 cm. The left kidney measured 4.73 cm. Mineralization was noted in the kidneys.

Adrenal Glands

Both **adrenal glands** were visualized and recognized as having normal shape, size, position and echogenicity for this breed. The phrenic vasculature, glandular echogenicity and detail were unremarkable. Capsule, cortex, and medullary definition were normal for this age patient. The right adrenal gland measured 1.68 cm x 0.69 cm at the caudal pole and 0.81 cm at the cranial pole. The left adrenal gland measured 0.6 cm.

Spleen

The **spleen** was enlarged and irregular with micronodular changes.

Liver

The **liver** was riddled with multiple expansive mixed echogenic masses, consistent with metastatic pattern. The gallbladder and common bile duct were unremarkable.

Gastrointestinal

Examination of the **gastrointestinal tract** revealed a stomach and intestine free of stasis, of normal wall thickness, acceptable curvilinear mural detail, and peristaltic activity. Small and large intestine demonstrated normal luminal chyme and stool consistency respectively. No obstructive or overt infiltrative disease was noted. No associated abnormal lymphatic activity was noted.

Pancreas

The base and limbs of the **pancreas** were observed to be largely isoechoic to surrounding omental fat. Pancreatic duct and capsular contour were acceptably normal and parenchyma respected normal curvilinear patterns. No overt evidence of active inflammatory or neoplastic disease was noted.

Free Abdomen

Free fluid was noted in the abdomen, likely secondary to portal hypertension and/or paraneoplastic effusion. Multiple lymph nodes were enlarged.

ULTRASONOGRAPHIC FINDINGS

- Stage B-1 valvular disease



PATIENT

Lacey Pohlman

SPECIES

Canine

BREED

Mini Poodle

SEX

Spayed Female

AGE

13 Years

WEIGHT

13.1 Pounds

INTERPRETED BY

Eric Lindquist, DMV,
 DABVP(CFM), Cert.
 IVUSS

IMAGING PERFORMED BY

Meghan Morse, LVT,
 CVT

HOSPITAL NAME

Newton VH

REFERRING VET

Dr. Chabora

INVOICE

35619

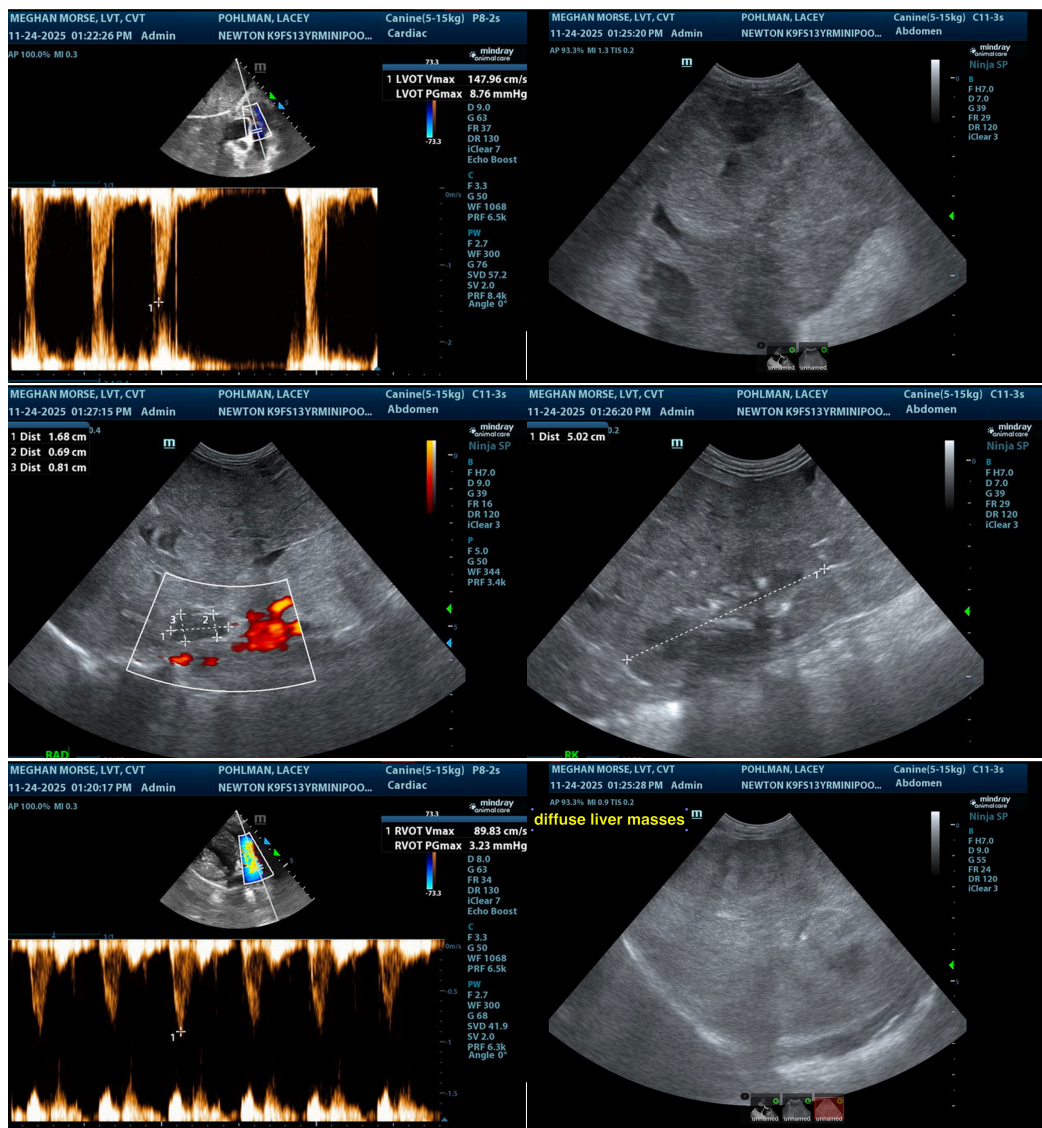
DATE

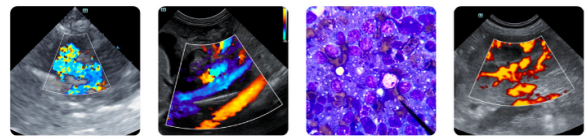
11/24/25

- Persistent arrhythmia- EKG or Holter monitor indicated
- Splenohepatic infiltrative neoplasia
- Lymphadenopathy
- Age-related renal changes with mineralization
- Secondary fluid owing to paraneoplastic processes

INTERPRETATION OF THE FINDINGS & FURTHER RECOMMENDATIONS

Prognosis is poor. Humane euthanasia should be considered in this patient given the diffuse and aggressive nature of the disease.





PATIENT

Lacey Pohlman

SPECIES

Canine

BREED

Mini Poodle

SEX

Spayed Female

AGE

13 Years

WEIGHT

13.1 Pounds

INTERPRETED BY

Eric Lindquist, DMV,
 DABVP(CFM), Cert.
 IVUSS

IMAGING PERFORMED BY

Meghan Morse, LVT,
 CVT

HOSPITAL NAME

Newton VH

REFERRING VET

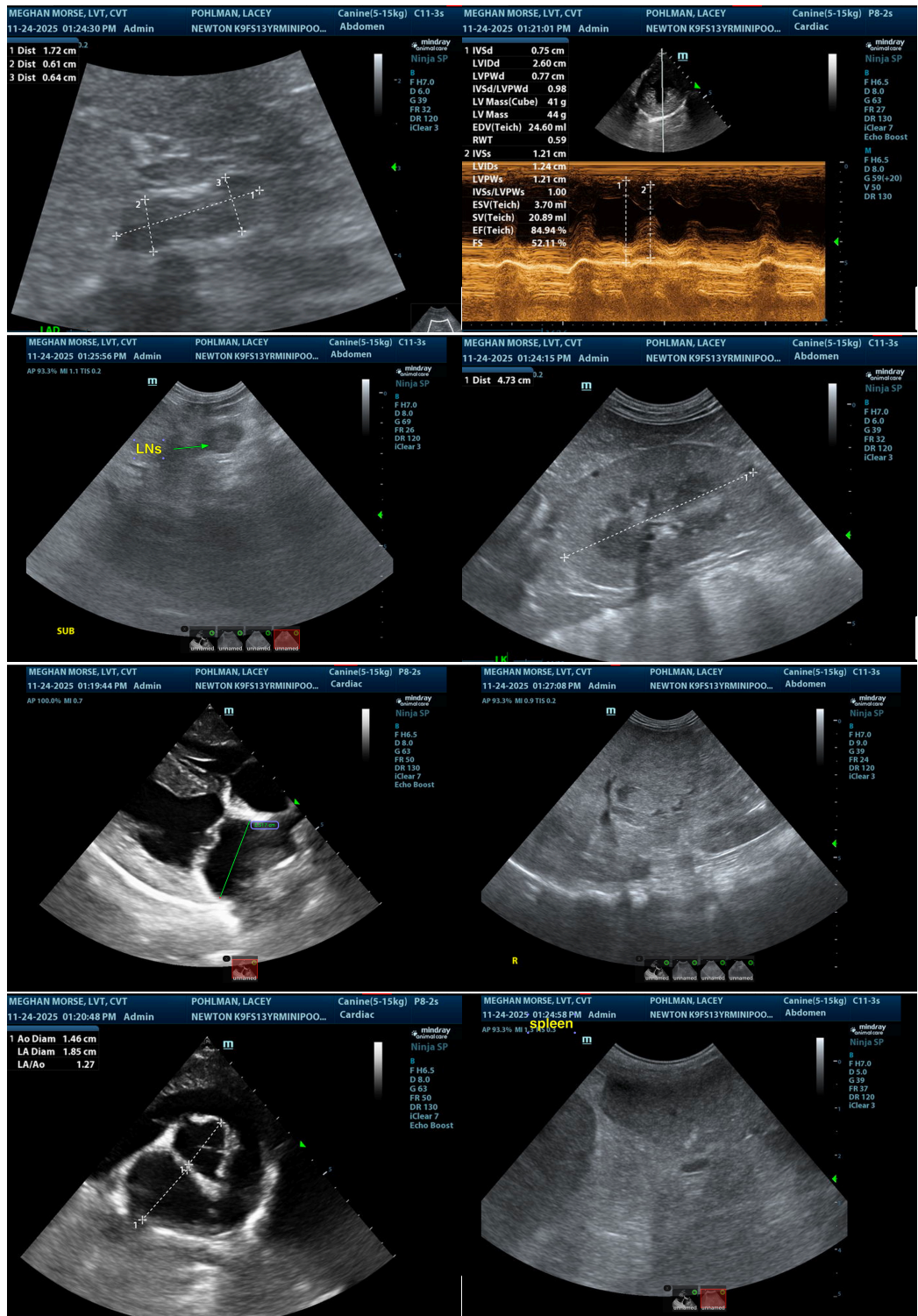
Dr. Chabora

INVOICE

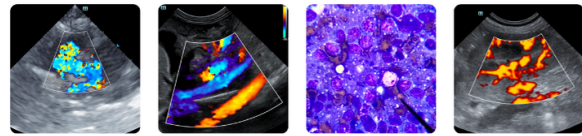
35619

DATE

11/24/25



The information and recommendations provided are based on the images presented by the



PATIENT

Lacey Pohlman

SPECIES

Canine

BREED

Mini Poodle

SEX

Spayed Female

AGE

13 Years

WEIGHT

13.1 Pounds

INTERPRETED BY

Eric Lindquist, DMV,
DABVP(CFM), Cert.
IVUSS

**IMAGING
PERFORMED BY**

Meghan Morse, LVT,
CVT

HOSPITAL NAME

Newton VH

REFERRING VET

Dr. Chabora

INVOICE

35619

DATE

11/24/25

referring veterinarian/sonographer. No evaluation can be communicated regarding pathology that was not visible in the image/video clips provided.

Thank you for this referral. If the clinical or image interpretation does not parallel your findings or if I can be of any further assistance please contact me.

Eric Lindquist, DMV, DABVP(CFM), Cert. IVUSS,
CEO, Owner, Founder -- SonoPath.com
info@SonoPath.com