



PATIENT

Aries Lewis

SPECIES

Canine

BREED

Shepherd Mix

SEX

Neutered male

AGE

2 years

WEIGHT

76 lbs

INTERPRETED BY

Eric Lindquist, DMV
DABVP, Cert. IVUSS

IMAGING PERFORMED BY

Varujan Belekdanian

HOSPITAL NAME

Overpeck CAH

REFERRING VET

Dr. Belekdanian

INVOICE

69817

DATE

1/5/26

PRESENTING CLINICAL SIGNS

History: Aries is a 2 year old MN mixed shepherd breed who presents for non-intentional weight loss and chronic loose stool. Patient's initial weight was around 87 pounds in August, and now is around 76 pounds with a BCS between 3-4. CBC/Chemistry/resting cortisol/cPLI revealed no abnormal bloodwork. Diarrhea PCR came back negative. Abdominal radiographs also did not reveal any major abnormalities. B12/TLI/B9 came back with hypcobalaminemia (170), and an extremely elevated TLI (>50). B9 was normal. Patient has already been dewormed, as well as been treated with metronidazole. Patient is currently on a hydrolyzed diet after recent failure of low fat diet.

ULTRASONOGRAPHIC EXAMINATION OF THE ABDOMEN

Urinary System

The **urinary bladder**, trigone, and pelvic urethra presented normal thicknesses and normal tone. The pelvic urethra was imaged 2.0 cm beyond the cystourethral junction and appeared normal. The ureters were not visible which is normal. No uroliths or sediment were visualized and anechoic urine was present. No evidence of inflammatory or neoplastic changes was noted. Ureteral papillae were normal.

The **kidneys** revealed normal size and structure, corticomedullary definition and ratio for this age. The cortices presented largely uniform texture with normal echogenic relationship to liver and spleen. Medullary structure differed distinctly from the cortex and no evidence of pelvic dilation was present. The capsules were acceptably uniform without significant irregularities. The left kidney measured 7.5 cm. The right kidney measured 7.5 cm.

Adrenal Glands

The **adrenal glands** were not visualized.

Spleen

The **spleen** presented a smooth homogeneous parenchyma hyperechoic to liver and renal cortical parenchyma. The capsule was smooth without noticeable expansion or deviation from within the spleen or adjacent pathology. The splenic vasculature demonstrated normal volume without signs of congestion or thrombosis. No sonographic evidence of acute or chronic inflammatory, neoplastic, or infarctual changes was noted.

Liver

The visible **liver** was minimal. There was no gross pathology. The gallbladder presented acceptably thin walls with primarily anechoic content. The cystic and common bile ducts were normal. No pathological hepatic lymphadenopathy was evident.



PATIENT

Aries Lewis

SPECIES

Canine

BREED

Shepherd Mix

SEX

Neutered male

AGE

2 years

WEIGHT

76 lbs

INTERPRETED BY

Eric Lindquist, DMV
DABVP, Cert. IVUSS

IMAGING PERFORMED BY

Varujan Belekdanian

HOSPITAL NAME

Overpeck CAH

REFERRING VET

Dr. Belekdanian

INVOICE

69817

DATE

1/5/26

Gastrointestinal

Examination of the **gastrointestinal tract** revealed a stomach and intestine free of stasis, of normal wall thickness, acceptable curvilinear mural detail, and peristaltic activity. Small and large intestine demonstrated normal luminal chyme and stool consistency respectively. No obstructive or overt infiltrative disease was noted. No associated abnormal lymphatic activity was noted.

Pancreas

The base and limbs of the **pancreas** were observed to be largely isoechoic to surrounding omental fat. Pancreatic duct and capsular contour were acceptably normal and parenchyma respected normal curvilinear patterns. No overt evidence of active inflammatory or neoplastic disease was noted.

ULTRASONOGRAPHIC FINDINGS

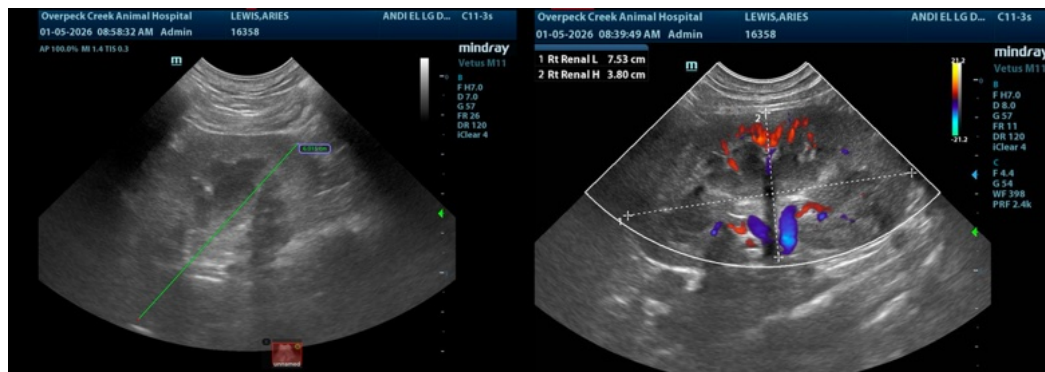
Unremarkable abdomen.

INTERPRETATION OF THE FINDINGS & FURTHER RECOMMENDATIONS

Maldigestion panel, three view chest radiographs and full CNS examination is recommended to examine for occult disease that could be responsible for the weight loss. Evaluation for competitive eating environments should also be considered.

Internal medicine consult can be utilized through SonoPath.com. You can select the internal medicine drop down at <http://spa.sonopath.com/>.

One of the world's top internists & SonoPath associate Dr. Remo Lobetti BVSc, MMedVet, PhD, DECVIM can evaluate your case through SonoPath. <https://sonopath.com/resources/sonopath-services/internal-medicine-teleconsultation-services>





PATIENT

Aries Lewis

SPECIES

Canine

BREED

Shepherd Mix

SEX

Neutered male

AGE

2 years

WEIGHT

76 lbs

INTERPRETED BY

Eric Lindquist, DMV
DABVP, Cert. IVUSS

IMAGING PERFORMED BY

Varujan Belekdanian

HOSPITAL NAME

Overpeck CAH

REFERRING VET

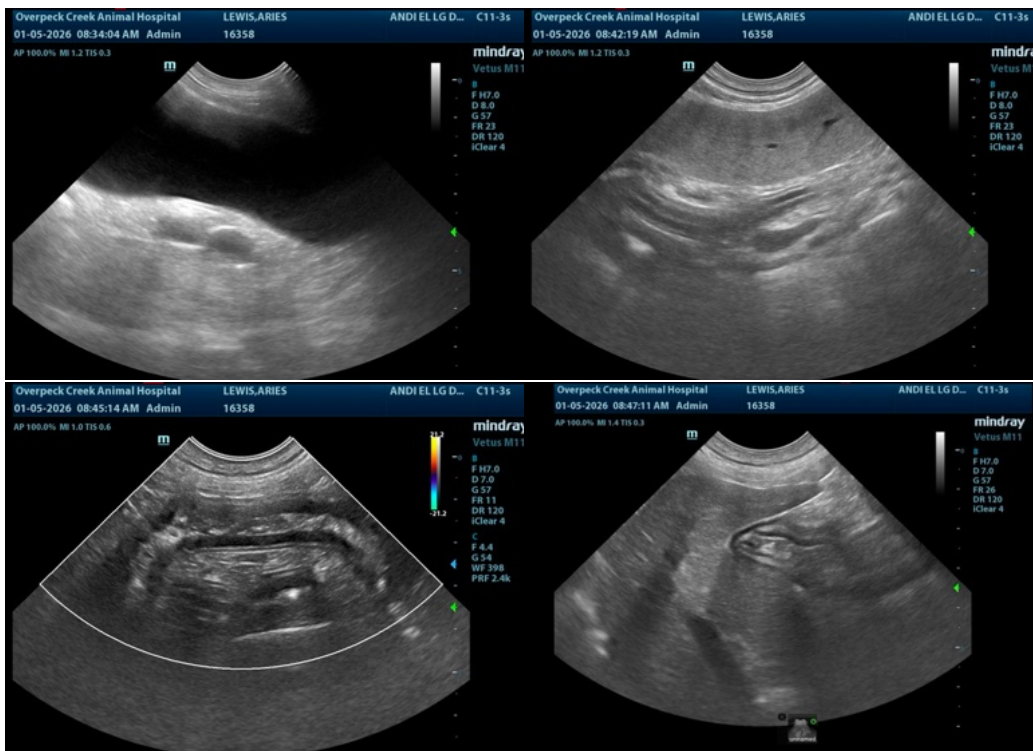
Dr. Belekdanian

INVOICE

69817

DATE

1/5/26



The information and recommendations provided are based on the images presented by the referring veterinarian/sonographer. No evaluation can be communicated regarding pathology that was not visible in the image/video clips provided.

Thank you for this referral. If the clinical or image interpretation does not parallel your findings or if I can be of any further assistance please contact me.

Eric Lindquist, DMV, DABVP (CFM), Cert. IVUSS, CEO of SonoPath.com

info@SonoPath.com