



**PATIENT**

Cooper Costa

**SPECIES**

Canine

**BREED**

Australian Shepherd  
Mix

**SEX**

Neutered Male

**AGE**

12 Years

**WEIGHT**

Not Provided

**INTERPRETED BY**

Eric Lindquist, DMV,  
DABVP (CFM), Cert.  
IVUSS

**IMAGING PERFORMED BY**

Shari Reffi, CVT

**HOSPITAL NAME**

Chester AH

**REFERRING VET**

Dr. Migliaccio

**INVOICE**

35363

**DATE**

1/12/26

**PRESENTING CLINICAL SIGNS**

History: Check liver- increased liver enzymes. Amoxicillin 500mgs BID 21 day Denamarin started 12/11/25

Abnormal PE/Chem/CBC/UA Results: 8/8/24 ALP 258/150, 10/14/25ALB 4.6/4.4 ALP 714/150, ALT 212/118 12/11/25 ALP 1108/150, ALT 305/118, Glu 114

**ULTRASONOGRAPHIC EXAMINATION OF THE ABDOMEN**

**Urinary System**

The **urinary bladder**, trigone, and pelvic urethra presented normal thicknesses and normal tone. The ureters were not visible which is normal. No uroliths or sediment were visualized and anechoic urine was present. No evidence of inflammatory or neoplastic changes was noted. Ureteral papillae were normal. The residual prostate measured 1.35 cm.

The **kidneys** revealed normal size and structure, corticomedullary definition and ratio for this age. The cortices presented largely uniform texture with normal echogenic relationship to liver and spleen. Medullary structure differed distinctly from the cortex, and no evidence of pelvic dilation was present. The capsules were acceptably uniform without significant irregularities. The left kidney measured 6.83 cm. The right kidney measured 6.83 cm.

**Adrenal Glands**

Both **adrenal glands** were visualized and recognized as having normal shape, size, position and echogenicity for this breed. The phrenic vasculature, glandular echogenicity and detail were unremarkable. Capsule, cortex, and medullary definition were normal for this age patient. The left adrenal gland measured 0.77 cm at the caudal pole and 0.62 cm at the cranial pole. The right adrenal gland measured 1.16 cm at the cranial pole and 0.93 cm at the caudal pole.

**Spleen**

The **spleen** revealed a mixed echogenic nodular change at the mid caudal body, measuring 1.7 cm. The remainder of the spleen was unremarkable.

**Liver**

The right **liver** in this patient revealed a microcystic and parenchymal mass, measuring 8.2 cm x 6.0 cm, deriving from the caudate process. The left liver revealed a separate mass, measuring 10.0 cm x 7.0 cm. The left liver mass has the architecture of a hepatoma and impinges upon the diaphragm cranially. The mid cranial liver presented a mild to moderate amount of remodeling. A large cyst was noted associated with the caudal liver, measuring 10.0+ cm. The cystic mass in the caudate process impinged upon the vena cava dorsally. The gallbladder was mildly echogenic.

**Gastrointestinal**

Examination of the **gastrointestinal tract** revealed a stomach and intestine free of stasis, of normal wall thickness, acceptable curvilinear mural detail, and peristaltic activity. Small and large intestine demonstrated normal luminal chyme and stool consistency respectively. No obstructive or overt infiltrative disease was noted. No associated abnormal lymphatic activity was noted.



**PATIENT**

**Pancreas**

Cooper Costa

The base and limbs of the **pancreas** were observed to be largely isoechoic to surrounding omental fat. Pancreatic duct and capsular contour were acceptably normal and parenchyma respected normal curvilinear patterns. No overt evidence of active inflammatory or neoplastic disease was noted.

**SPECIES**

Canine

**Other**

**BREED**

A rapid view of the **heart** revealed no evident pathology.

Australian Shepherd

Mix

**SEX**

Neutered Male

**AGE**

12 Years

**WEIGHT**

Not Provided

**ULTRASONOGRAPHIC FINDINGS**

- Concerning splenic nodule – emerging Hemangiosarcoma, nodular hyperplasia, round cell neoplasia (less likely).
- The left liver mass (architecture of hepatoma). The left liver mass is potentially resectable; however, it does impinge upon the diaphragm cranially.
- Liver mass in the caudate process – differentials include hepatoma versus carcinoma. A cyst was also noted in the caudate process.
- Mildly echogenic gallbladder

**INTERPRETED BY**

Eric Lindquist, DMV,  
DABVP (CFM), Cert.  
IVUSS

**INTERPRETATION OF THE FINDINGS & FURTHER RECOMMENDATIONS**

CT evaluation for potential surgical planning with caudate lobectomy and left cranial liver lobectomy would be indicated with appropriate FNAs. Hepatoma versus carcinoma are primary concerns. Splenectomy is also indicated given the splenic nodule.

**IMAGING PERFORMED BY**

Shari Reffi, CVT

**ABOUT SONOPATH CT SERVICES:**

**SonoPath CT Services** are offered at the SonoPath Imaging and Veterinary Education Center, 141 Main St (rt 206), Andover, New Jersey, a 20-minute drive west on route 80/206 North from the route 80/287 interchange/Parsippany, New Jersey. More information can be found at <https://sonopath.com/services/vetimaging/>

**HOSPITAL NAME**

Chester AH

**REFERRING VET**

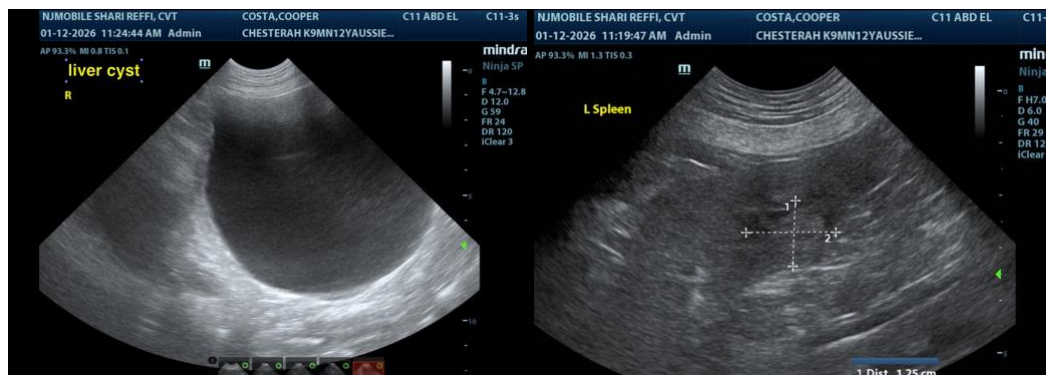
Dr. Migliaccio

**INVOICE**

35363

**DATE**

1/12/26





**PATIENT**

Cooper Costa

**SPECIES**

Canine

**BREED**

Australian Shepherd  
 Mix

**SEX**

Neutered Male

**AGE**

12 Years

**WEIGHT**

Not Provided

**INTERPRETED BY**

Eric Lindquist, DMV,  
 DABVP (CFM), Cert.  
 IVUSS

**IMAGING PERFORMED BY**

Shari Reffi, CVT

**HOSPITAL NAME**

Chester AH

**REFERRING VET**

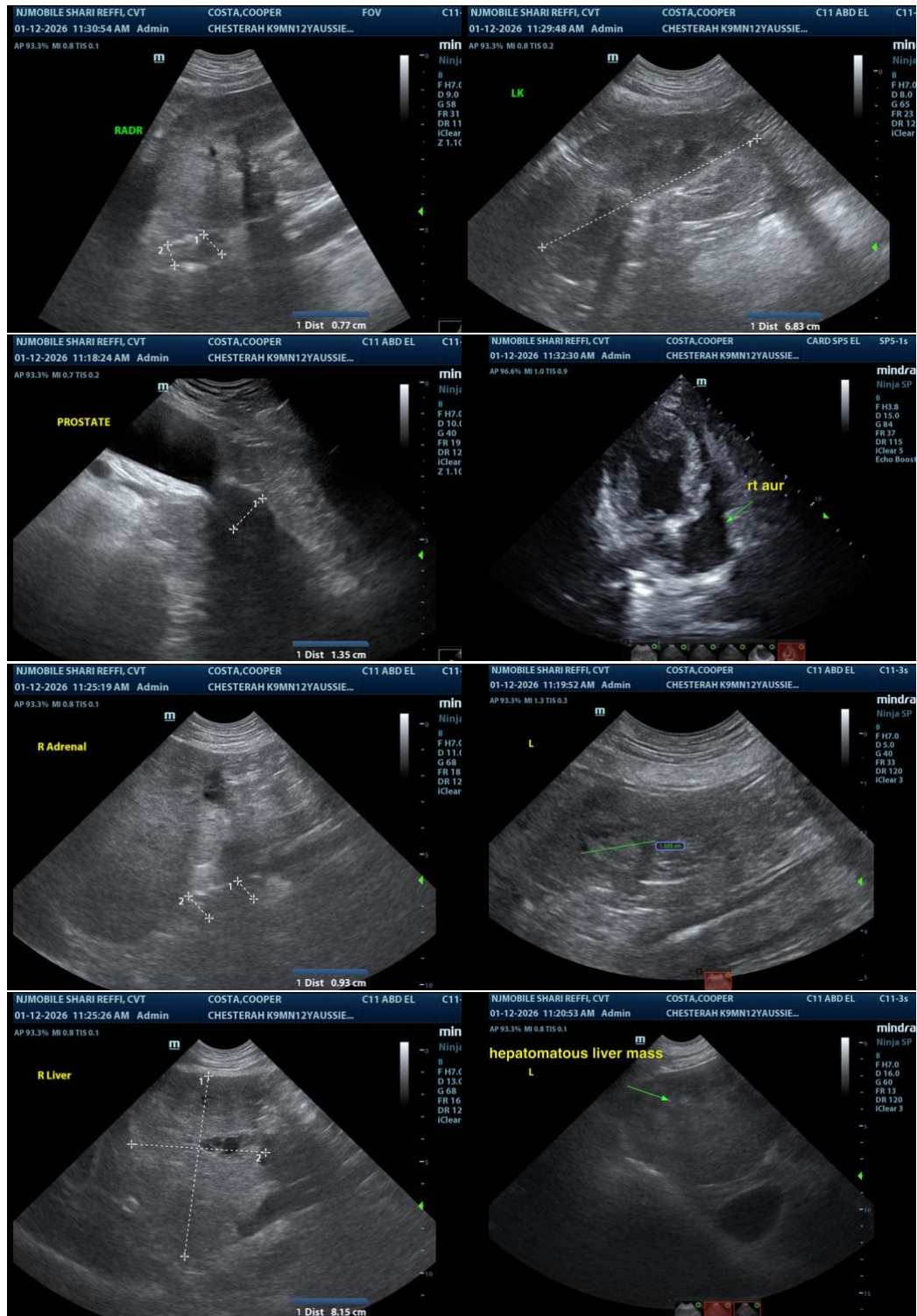
Dr. Migliaccio

**INVOICE**

35363

**DATE**

1/12/26





**PATIENT**

Cooper Costa

**SPECIES**

Canine

**BREED**

Australian Shepherd  
Mix

**SEX**

Neutered Male

**AGE**

12 Years

**WEIGHT**

Not Provided

**INTERPRETED BY**

Eric Lindquist, DMV,  
DABVP (CFM), Cert.  
IVUSS

**IMAGING PERFORMED BY**

Shari Reffi, CVT

**HOSPITAL NAME**

Chester AH

**REFERRING VET**

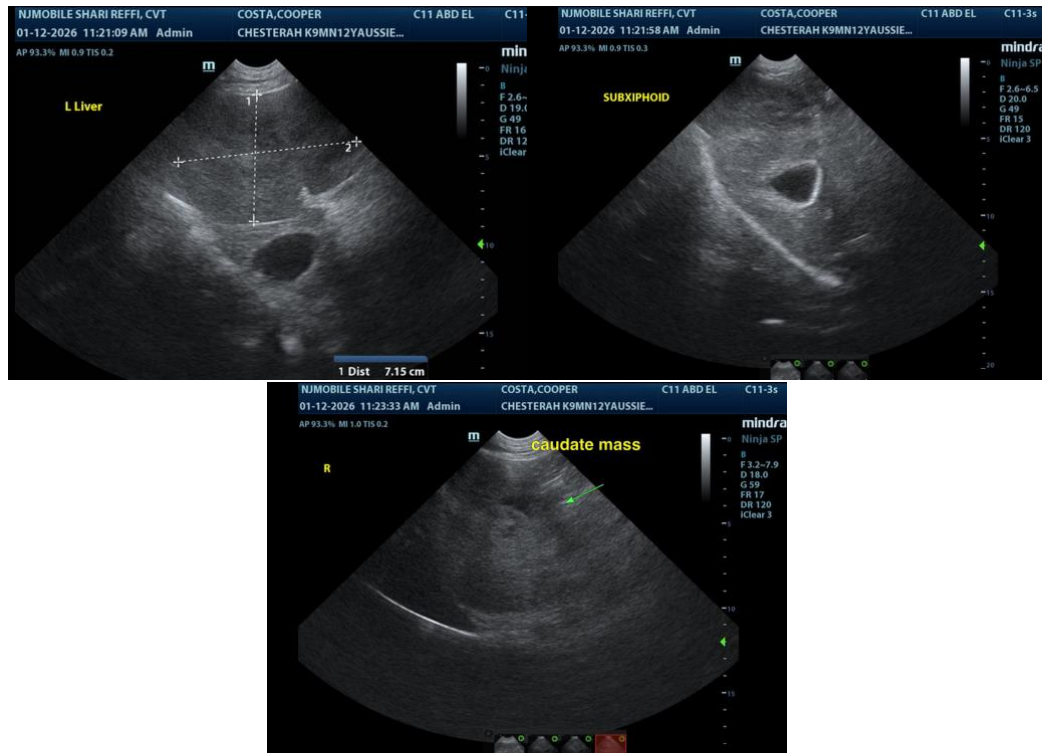
Dr. Migliaccio

**INVOICE**

35363

**DATE**

1/12/26



**The information and recommendations provided are based on the images presented by the referring veterinarian/sonographer. No evaluation can be communicated regarding pathology that was not visible in the image/video clips provided.**

Thank you for this referral. If the clinical or image interpretation does not parallel your findings or if I can be of any further assistance please contact me.

**Eric Lindquist**, DMV, DABVP(CFM), Cert. IVUSS,  
CEO, Owner, Founder -- SonoPath.com  
[info@SonoPath.com](mailto:info@SonoPath.com)

**Hepatic Masses, Biliary Adenoma, and Biliary Adenocarcinoma**

<http://www.sonopath.com/HepaticMasses>

**Description:** Hepatocellular carcinoma typically manifests in the liver's left lateral lobes, yet may cross over to the right lobes should it derive from the hilus. These masses often present cavitating, necrotic cores that are difficult to distinguish from hepatic abscesses. Vascular channels may also be involved, and bile duct obstruction is often present. Older felines often present solitary or multiple fluid-filled cysts within the hepatic parenchyma. The latter are typically benign cystadenomas and should be differentiated from: cystic adenocarcinoma; hepatic lymphoma (usually diffusely



**PATIENT**

Cooper Costa

**SPECIES**

Canine

**BREED**

Australian Shepherd  
Mix

**SEX**

Neutered Male

**AGE**

12 Years

**WEIGHT**

Not Provided

**INTERPRETED BY**

Eric Lindquist, DMV,  
DABVP (CFM), Cert.  
IVUSS

**IMAGING PERFORMED BY**

Shari Reffi, CVT

**HOSPITAL NAME**

Chester AH

**REFERRING VET**

Dr. Migliaccio

**INVOICE**

35363

**DATE**

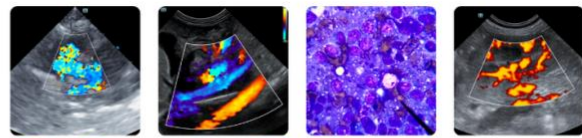
1/12/26

hyperechoic +/- FIV/FelV association); metastatic neoplasia (diffuse hyper- to hypoechoic nodules secondary to mammary adenocarcinoma, splenic hemangiosarcoma, or pancreatic or intestinal adenocarcinoma); benign nodular hyperplasia (accompanied by minimal to no symptoms); hepatic cirrhosis (regenerative nodules); or rare carcinoids, fibrosarcomas, leiomyosarcomas, and osteosarcomas.

**Clinical Signs:** Possible clinical signs and physical exam findings include cranial abdominal organomegaly, sudden collapse associated with mass rupture, vomiting, ascites, jaundice (severe cases), and hypoglycemia secondary to a paraneoplastic syndrome. Sepsis and fever associated with secondary abscessation of the mass may also occur. Cats usually present with anorexia and lethargy.

**Diagnostics:** Routine biochemical analysis primarily shows liver enzyme elevation (i.e., ALT for cellular necrosis; SAP for hepatic congestion; elevated bilirubin for stasis/obstruction; bile acids > 75-100uM/L for significant function impairment). Staging of the disease with 3-view thoracic radiographs is essential, as is conducting a CBC, serum biochemistry, urinalysis, as well as abdominal and possibly also thoracic ultrasounds in order to provide the owner with adequate and well-informed options. Surgical and oncological referral is recommended after a coagulation panel has been assessed and ultrasound-guided biopsies of both normal and pathological tissue have been performed such that the disease is adequately characterized. In cases where surgical resection is impossible, direct chemoembolization of the tumor blood supply could be considered; however, this procedure is only performed at specific tertiary referral locations. Placement of palliative stents into the caudal vena cava (CVC) can be considered as well if compression by an unresectable tumor causes excessive ascitic fluid accumulation. Serum alpha-fetoprotein (AFP) has been shown to reemerge in dogs with malignant hepatobiliary adenocarcinoma. Ultrasound is important to localize the mass in relation to the portal hilus and gallbladder. The portal vein, CVC, aorta, gallbladder, and bile duct should all be identified with respect to the location of the mass to determine resectability. Ultrasound also allows for an examination of possible metastatic sites in the abdomen and, to some degree, in the thorax.

**Treatment:** Hepatic adenoma, hepatoma, and adenocarcinoma are usually amenable to surgical resection via hepatic lobectomy should the pathology be isolated to single-lobe progression. Multi-lobar presentation may be amenable to lobectomy and debulking; this will be determined further during surgical consultation. These tumors tend to displace unaffected parenchyma, allowing for relatively straightforward surgical resection. Up to 80% of the liver can be removed without long-term functional deficits. Blood transfusions may be necessary during surgery. The development and implementation of the LDS™ stapler has helped to streamline the procedure. Most carcinomas have metastasized by the time of diagnosis yet tend to be slow-growing; thus, it may be possible for a certain quality of life to be attained via surgical resection. Hepatic hemangiosarcoma has usually metastasized at the time of diagnosis and carries a much poorer prognosis. Surgical resection and chemotherapy are recommended, but considered by many to be an “aggressive” approach.



**PATIENT**

Cooper Costa

Preliminary trials have shown that gemcitabine is well tolerated and yields good responses in cases of hepatic as well as pancreatic, colonic, and gastric carcinomas. Myelosuppression, however, remains the key issue. Doxorubicin, cyclophosphamide, and fluorouracil combinations have also proven fruitful.

**SPECIES**

Canine

Nonsteroidal anti-inflammatory drugs (NSAIDs) have been demonstrated to have an anti-neoplastic effect due to their inhibition of COX-2 in certain tumor cells. The end product of the cyclooxygenase cascade is prostaglandin E2, which, when expressed in tumor cell lines—and not expressed in normal cells of that particular cell line—results in inhibited apoptosis, immunosuppression, and increased angiogenesis, proliferation, and invasiveness. Inappropriate increases in COX-2 expression have been documented in certain neoplasias, including squamous cell carcinoma, mammary carcinomas, prostatic carcinoma, malignant melanoma, and transitional cell carcinoma.

**BREED**

Australian Shepherd  
Mix

**SEX**

Neutered Male

Metronomic chemotherapy is currently being investigated and compared to traditional chemotherapy protocols; it is thought to be at least as effective as the latter with substantially less toxic side effects. Metronomic chemotherapy is the practice of uninterrupted administration of low-dose cytotoxic drugs at regular and frequent intervals, as opposed to high-dose, shorter-term protocols characteristic of traditional chemotherapeutic practices. The lower dose allows for long-term administration without toxic side effects, and has been postulated as providing longer remission intervals. Moreover, it has the benefit of minimizing the intervals between drug regimens—the period during which tumor cells may repopulate the area—as well as the chance of developing multi-drug resistant genes. Metronomic chemotherapy has been used successfully in human patients who have undergone previous chemotherapy administration. It is thought to destroy endothelial cells, thereby retarding angiogenesis and targeting regulatory T cells. To date, there have only been a few small clinical trials in veterinary patients, and these have focused on animals that have hemangiosarcoma and soft tissue sarcomas.

**AGE**

12 Years

**WEIGHT**

Not Provided

**INTERPRETED BY**

Eric Lindquist, DMV,  
DABVP (CFM), Cert.  
IVUSS

**Conclusion:** With respect to hepatic neoplasia, many surgical and chemotherapeutic options exist; however, it is best to consult with a local board certified oncologist who can help determine the best course of action.

**IMAGING  
PERFORMED BY**

Shari Reffi, CVT

**References:**

Biller BJ. Teaching T cells to target tumors: towards the design of more effective cancer vaccines. Proceedings from the American College of Veterinary Internal Medicine Forum, Denver, CO, June 15-18, 2011.

**HOSPITAL NAME**

Chester AH

Biller BJ, Guth A, Burton JH, Dow SW. Decreased ratio of CD8+ T cells to regulatory T cells associated with decreased survival in dogs with osteosarcoma. *J Vet Intern Med* 2010;24(5):1118-23.

**REFERRING VET**

Dr. Migliaccio

Elmslie RE, Glawe P, Dow SW. Metronomic therapy with cyclophosphamide and piroxicam effectively delays tumor recurrence in dogs with incompletely resected soft tissue sarcomas. *J Vet Intern Med* 2008;22(6):1373-79.

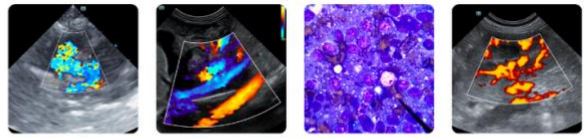
**INVOICE**

35363

Lana S, U'Ren L, Plaza S, et al. Continuous low-dose oral chemotherapy for adjuvant therapy of splenic hemangiosarcoma in dogs. *J Vet Intern Med* 2007;21(4):764-69.

**DATE**

1/12/26



**PATIENT**

Milner RJ. Do NSAIDs make a difference in cancer? Proceedings from the American College of Veterinary Internal Medicine Forum, Denver, CO, June 15-18, 2011.

Cooper Costa

**SPECIES**

Canine

**BREED**

Australian Shepherd  
Mix

**SEX**

Neutered Male

**AGE**

12 Years

**WEIGHT**

Not Provided

**INTERPRETED BY**

Eric Lindquist, DMV,  
DABVP (CFM), Cert.  
IVUSS

**IMAGING  
PERFORMED BY**

Shari Reffi, CVT

**HOSPITAL NAME**

Chester AH

**REFERRING VET**

Dr. Migliaccio

**INVOICE**

35363

**DATE**

1/12/26