



PATIENT

Loki Sadler

SPECIES

Canine

BREED

Poodle X

SEX

Neutered Male

AGE

10 Years

WEIGHT

18 Pounds

INTERPRETED BY

Eric Lindquist, DMV

DABVP, Cert. IVUSS

IMAGING PERFORMED BY

Dr. Desen Ertunc

HOSPITAL NAME

Healing Spirit

REFERRING VET

Dr. Desen Ertunc

INVOICE

40423

DATE

8/12/22

PRESENTING CLINICAL SIGNS

2 day history of vomiting, anorexia and lethargy. Was given ham + eggs and home made biscuits day prior to onset of signs. No prior medical history. No C/S/D reported.

Abnormal PE/Chem/CBC/UA Results: PE_ moderate abdominal distension, very sensitive to palpation along R & L cranial abdomen, no response with pressure along xiphoid process. CBC: Hgb= 19.9 *12-18), HCT= 58 % Chem/T4 not reliable due to lipemia Chem: ALP= 244 (20-150), ALT did not read, tBili= 0.8 (0.1-0.6), Amy= 1505 (200-1200), BUN= 45 (7-25), Creat= 1.9 (0.3-1.4), Glu= 181 (138-160), Na = 108 (138-160), K= 3.9 (3.7-5.8), Na:K= 27

ULTRASONOGRAPHIC EXAMINATION OF THE ABDOMEN

Urinary System

The **urinary bladder** was overdistended at the time of the sonogram, unremarkable otherwise.

The **kidneys** revealed normal size and structure, corticomedullary definition and ratio for this age. The cortices presented largely uniform texture with normal echogenic relationship to liver and spleen. Medullary structure differed distinctly from the cortex and no evidence of pelvic dilation was present. The capsules were acceptably uniform without significant irregularities.

Adrenal Glands

Spleen

The **spleen** was mildly enlarged with uniform, but subtly micronodular parenchyma, and undulating capsular contour. This is consistent with reactive spleen owing to immune stimulus or early infiltrative disease such as mast cell disease or lymphoma. 25-gauge FNA would be ideal if weight loss is an issue to differentiate early round cell neoplasia versus splenitis or reactive spleen all of which can present in this manner.

Liver

The **liver** was swollen with irregular contour and was hypoechoic to falciform fat. Minor gallbladder debris noted. No evidence of post-hepatic obstruction.

Gastrointestinal

Examination of the **gastrointestinal tract** revealed variable irregular thickening without loss of mural detail. Regional inflammation noted. Mesenteric lymph nodes were mildly enlarged, reactive, measuring 2.0 cm x 0.40 cm.

Pancreas

Hypoechoic, undifferentiated pancreatic presentation noted, consistent with areas of necrosis and regional peritonitis.

Free Abdomen

Some of the cranial abdomen was obscured by reactive surrounding mesentery.

ULTRASONOGRAPHIC FINDINGS

- Acute hepatitis/enteritis versus underlying round cell hepatic neoplasia



PATIENT

Loki Sadler

SPECIES

Canine

BREED

Poodle X

SEX

Neutered Male

AGE

10 Years

WEIGHT

18 Pounds

INTERPRETED BY

Eric Lindquist, DMV

DABVP, Cert. IVUSS

IMAGING PERFORMED BY

Dr. Desen Ertunc

HOSPITAL NAME

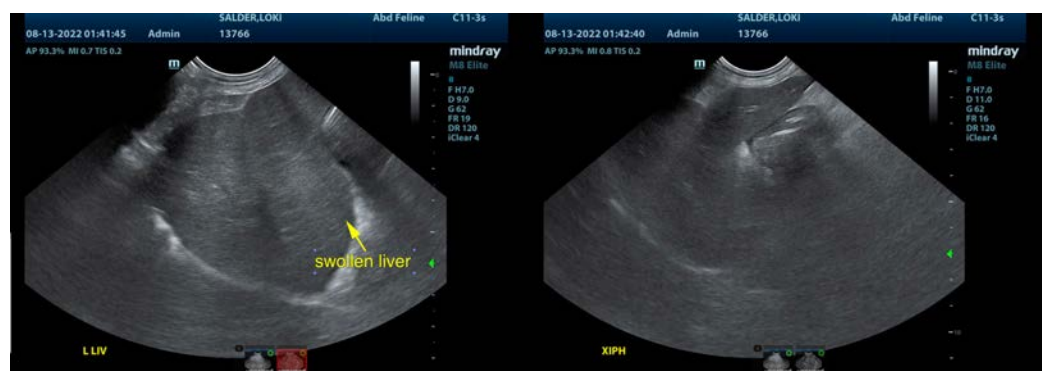
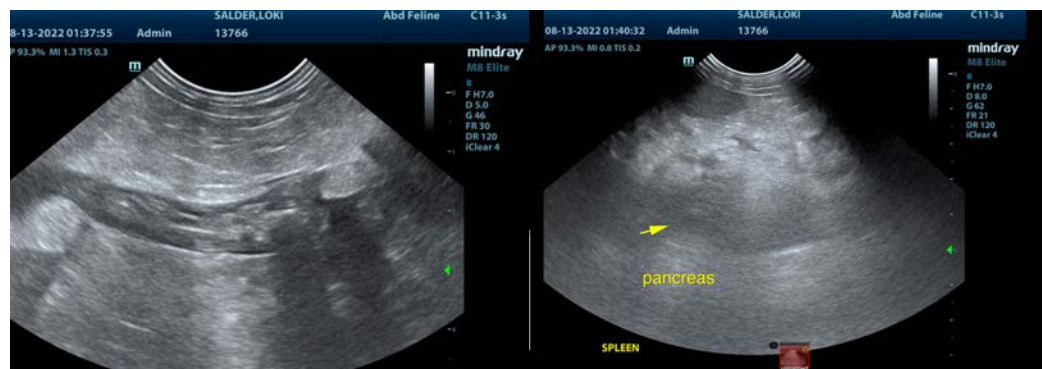
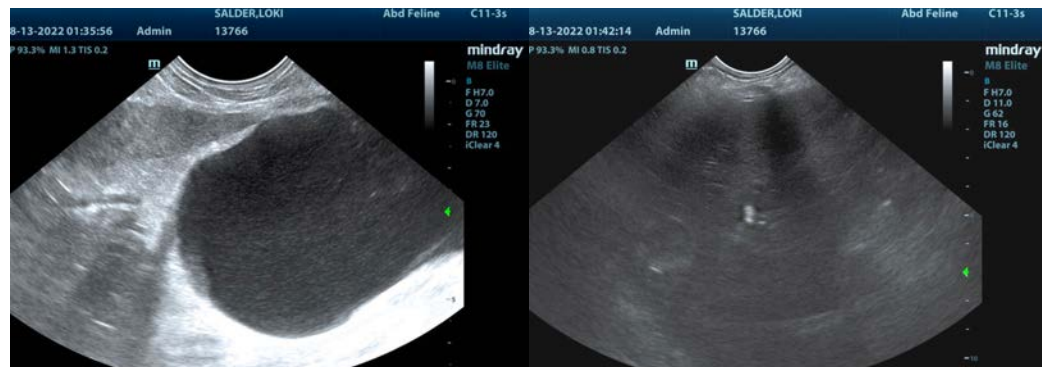
Healing Spirit

REFERRING VET

Dr. Desen Ertunc

INTERPRETATION OF THE FINDINGS & FURTHER RECOMMENDATIONS

Aggressive treatment for enteritis, pancreatitis, cholangiohepatitis recommended. However, screening FNA of the liver indicated. Cytology and culture recommended to assess for possibility of emerging neoplasia/lymphoma. Enterotoxin such as salmonella should be considered. Guarded prognosis.



INVOICE

40423

DATE

8/12/22



PATIENT

Loki Sadler

SPECIES

Canine

BREED

Poodle X

SEX

Neutered Male

AGE

10 Years

WEIGHT

18 Pounds

INTERPRETED BY

Eric Lindquist, DMV
DABVP, Cert. IVUSS

IMAGING PERFORMED BY

Dr. Desen Ertunc

HOSPITAL NAME

Healing Spirit

REFERRING VET

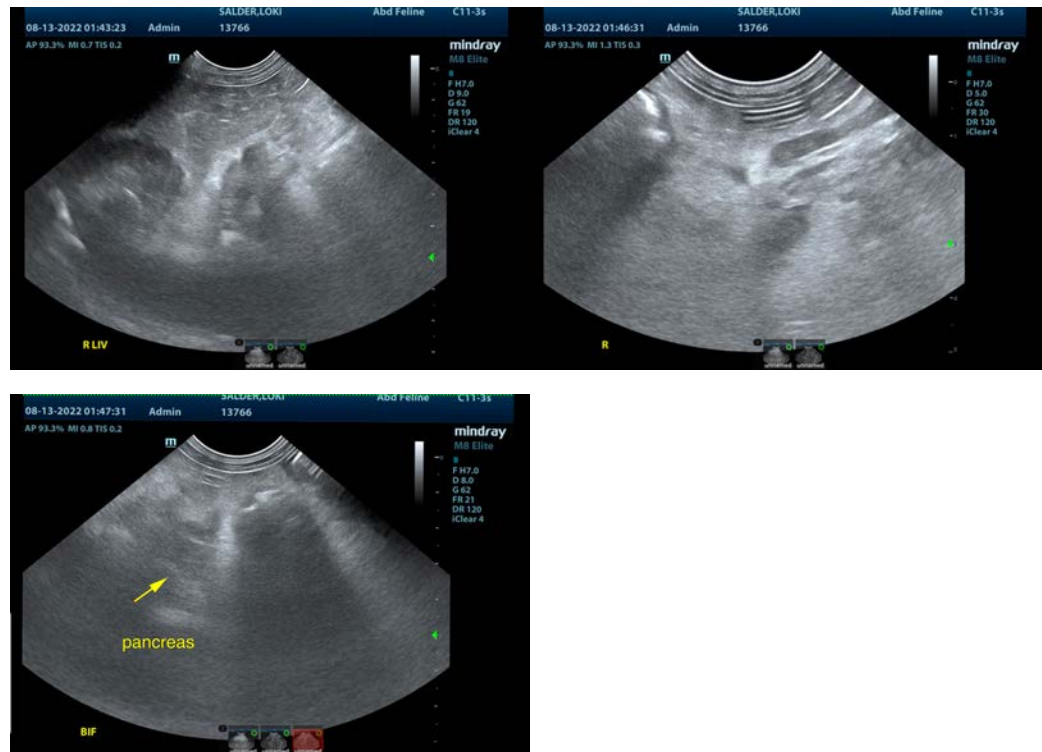
Dr. Desen Ertunc

INVOICE

40423

DATE

8/12/22



The information and recommendations provided are based on the images presented by the referring veterinarian/sonographer. No evaluation can be communicated regarding pathology that was not visible in the image/video clips provided.

Thank you for this referral. If the clinical or image interpretation does not parallel your findings or if I can be of any further assistance please contact me.

Eric Lindquist, DMV, DABVP, Cert. IVUSS, CEO of SonoPath.com

info@SonoPath.com