



PATIENT

Diamond Hoogendoorn

PRESENTING CLINICAL SIGNS

History: AI 32 days ago based on progesterone. Semen sample showed poor motility

SPECIES

Canine

ULTRASONOGRAPHIC EXAMINATION OF THE ABDOMEN

The abdomen in this patient revealed an unremarkable empty uterus that measured 1.0 cm in width. There was no evidence of pathology and no live fetuses.

BREED

Mastiff

ULTRASONOGRAPHIC FINDINGS

Barren female.

SEX

Female

INTERPRETATION OF THE FINDINGS & FURTHER RECOMMENDATIONS

No live fetuses and no overt pathology.

AGE

3 years

WEIGHT

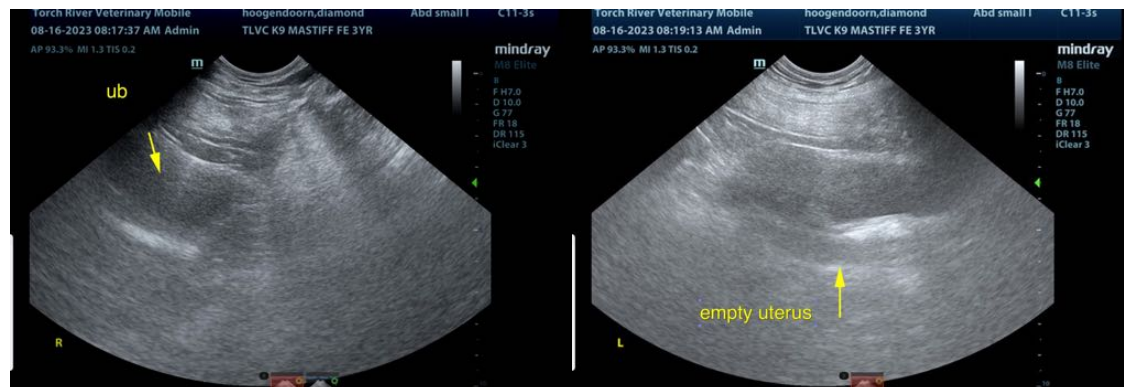
181 lbs

INTERPRETED BY

Eric Lindquist, DMV
DABVP, Cert. IVUSS

IMAGING PERFORMED BY

Torch River Veterinary
Mobile Services



The information and recommendations provided are based on the images presented by the referring veterinarian/sonographer. No evaluation can be communicated regarding pathology that was not visible in the image/video clips provided.

HOSPITAL NAME

Torch Lake VC

Thank you for this referral. If the clinical or image interpretation does not parallel your findings or if I can be of any further assistance please contact me.

REFERRING VET

Dr. Waffle

Eric Lindquist, DMV, DABVP, Cert. IVUSS, CEO of SonoPath.com
info@SonoPath.com

INVOICE

46618

DATE

8/15/23