



**PATIENT**

Marlie Sylsburg

**SPECIES**

Canine

**BREED**

Golden Retriever

**SEX**

Spayed female

**AGE**

8 ½ years

**WEIGHT**

41.8 lbs

**INTERPRETED BY**

Eric Lindquist, DMV,  
DABVP, Cert. IVUSS,  
CEO of SonoPath.com

**IMAGING PERFORMED BY**

Kelly Vazquez, CVT

**HOSPITAL NAME**

Companion VH of  
Wayne

**REFERRING VET**

Dr. Spitz

**INVOICE**

32762

**DATE**

9/7/22

**PRESENTING CLINICAL SIGNS**

History: Elevated T4/Free T4 - no meds. No palpated thyroid tumor.  
Abnormal PE/Chem/CBC/UA Results: T4 6.6, recheck T4 5.0, FT4 8.7, 3, TSH < 0.03.

**ULTRASONOGRAPHIC EXAMINATION OF THE THYROID**

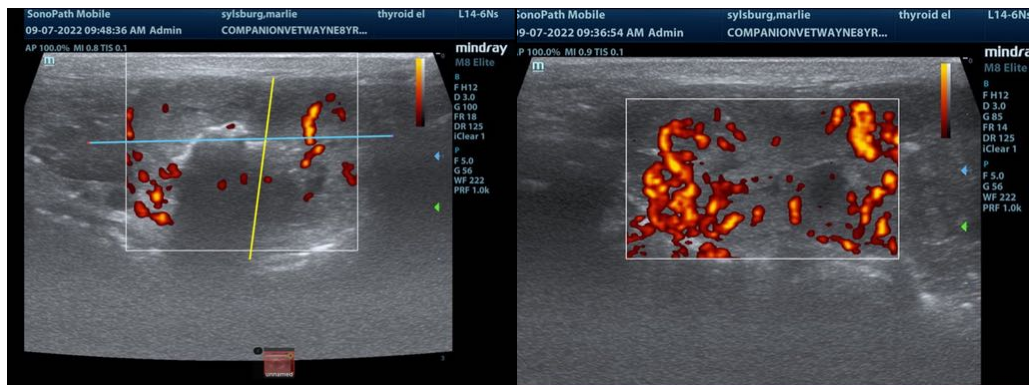
The left thyroid lobe is normal in size and contour measuring 1.03 x 0.17 cm with heterogenous, hypoechoic nodular changes noted. The largest parathyroid nodule measured 0.38 x 0.12 cm. The right thyroid lobe measured 1.05 x 0.25 cm with largest parathyroid at 0.3 x 0.11 cm. An undifferentiated, mineralizing, mixed echogenic and cystic mass was noted. This is highly vascular. The mass measured 3.0 x 1.77 cm and is adjacent to the trachea. The mass cannot be directly connected to either thyroid lobe; however, the structure would suggest thyroid carcinoma and may be ectopic. Ultrasound-guided FNA is warranted as well as CT evaluation for surgical planning.

**ULTRASONOGRAPHIC FINDINGS**

Mineralized, highly vascular mass adjacent to the thyroid lobes. Likely thyroid carcinoma; however, direct connection cannot be found.

**INTERPRETATION OF THE FINDINGS & FURTHER RECOMMENDATIONS**

The mass may be resectable based on CT results. FNA is indicated to confirm suspicion of thyroid carcinoma, possibly ectopic or a small bridge to normal thyroid tissue may be present, but not visible.





**PATIENT**

Marlie Sylsburg

**SPECIES**

Canine

**BREED**

Golden Retriever

**SEX**

Spayed female

**AGE**

8 ½ years

**WEIGHT**

41.8 lbs

**INTERPRETED BY**

Eric Lindquist, DMV,  
DABVP, Cert. IVUSS,  
CEO of SonoPath.com

**IMAGING PERFORMED BY**

Kelly Vazquez, CVT

**HOSPITAL NAME**

Companion VH of  
Wayne

**REFERRING VET**

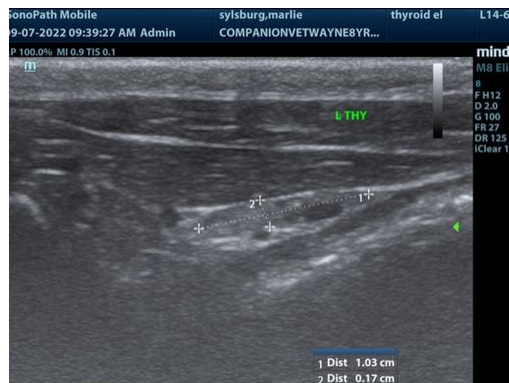
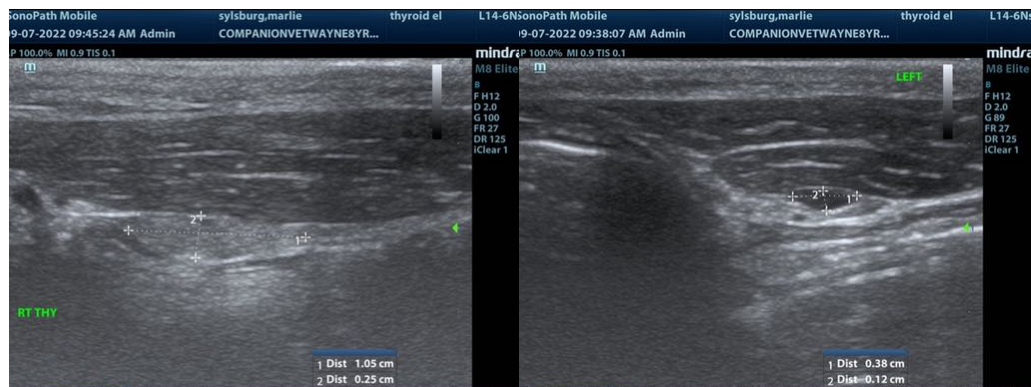
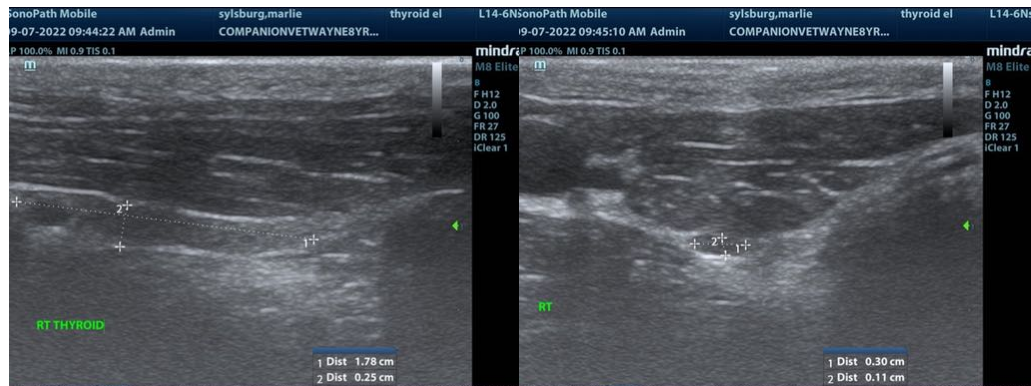
Dr. Spitz

**INVOICE**

32762

**DATE**

9/7/22



The information and recommendations provided are based on the images presented by the referring veterinarian/sonographer. No evaluation can be communicated regarding pathology that was not visible in the image/video clips provided.

Thank you for this referral. If the clinical or image interpretation does not parallel your findings or if I can be of any further assistance please contact me.

Eric Lindquist, DMV, DABVP, Cert. IVUSS, CEO of SonoPath.com

Info@SonoPath.com