



PATIENT PRESENTING CLINICAL SIGNS

Walter Ross

History: Grade II/VI R sided heart murmur, dx at time of neuter approx. 4 mos ago. Asymptomatic, no current meds.

SPECIES

Canine

BREED

Boxer

SEX

Neutered male

AGE

10 months

WEIGHT

74.5 lbs

INTERPRETED BY

Eric Lindquist, DMV
DABVP, Cert. IVUSS

IMAGING PERFORMED BY

Shari Reffi, CVT

HOSPITAL NAME

Branchville County VC

REFERRING VET

Dr. Talbot-Valerio

INVOICE

32739

DATE

9/6/22

ULTRASONOGRAPHIC EXAMINATION OF THE HEART

The echocardiogram in this patient demonstrated normal **left atrial** size based on 3 separate methods of LA evaluation. The cranial and caudal **mitral** valve leaflets presented normal linear structure, extension in systole, and union in diastole with normal kinesis. The **left ventricle** presented thicknesses with linear contour and was not dilated nor restricted. The **myocardium** presented normal echogenicity without subjective evidence of significant fibrotic or ischemic disease. **Contractility** of the ventricular walls was adequate and in normal range for this patient evidenced by the fractional shortening measurement and subjective evaluation of the different regions of the myocardium. The **left ventricular outflow** tract demonstrated normal laminar flow and subjective structural integrity. The **right atrial** size was mildly excessive. Septal tricuspid leaflet was appeared to be shortened, tethered and hypomotile. **Tricuspid** insufficiency was noted at 3.36 m/sec. The **right ventricle** was of normal size (1/3 diameter of LV), chordae structure, myocardial echogenicity and thickness. **Pulmonary outflow** tract assessment revealed normal valve structure, laminar flow, and diameter (approx. 1:1 pa/ao ratio). No visible **pericardial** or free pleura fluid was noted. The cranial **mediastinum and pericardial and extra-cardiac regions** were free of masses in the visible window.

| CANINE CARDIAC PARAMETERS | MR VMAX (m/s) | TR VMAX (m/s) | LA/AO (Boon method) | LA/AO (Heart Base; Swe) | FS (%) | EF (%) | EPSS (cm) |
|---------------------------|---------------|---------------|---------------------|-------------------------|-----------------------------------|--|--|
| NORMAL PARAMETER | 4.5-5.5 | <2.7 | 1.3 | <1.6 | 28-40 | 40-100 | <0.6 |
| PATIENT | | 3.36 | 1.15 | | 32 | 60 | NM |
| CANINE CARDIAC PARAMETERS | HR (BPM) | AV VMAX (m/s) | PV MAX (m/s) | BODY WEIGHT (kg) | LA (2D short axis Base view) (cm) | LVIDd (Avg; 2D and m-mode short axis) (cm) | LVIDs (Avg; 2D and m-mode short axis) (cm) |
| NORMAL PARAMETER | 50-100 | 0.7-1.7 | 0.7-1.6 | BELOW | BELOW | BELOW | BELOW |
| PATIENT | 209 | 2.0 | 1.28 | 74.5 lbs | 1.2 max | 3.98 | |

ULTRASONOGRAPHIC FINDINGS

Tricuspid insufficiency with shortened tricuspid valve.

INTERPRETATION OF THE FINDINGS & FURTHER RECOMMENDATIONS

The patient has a mild form of tricuspid dysplasia. There is no overt contraindication to anesthetic procedure indicated. Recheck echocardiogram in a year.



PATIENT

Walter Ross

SPECIES

Canine

BREED

Boxer

SEX

Neutered male

AGE

10 months

WEIGHT

74.5 lbs

INTERPRETED BY

Eric Lindquist, DMV
DABVP, Cert. IVUSS

IMAGING PERFORMED BY

Shari Reffi, CVT

HOSPITAL NAME

Branchville County VC

REFERRING VET

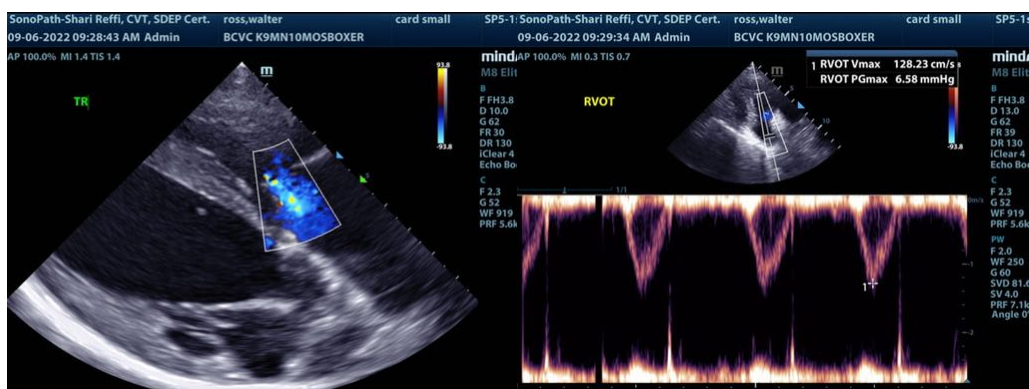
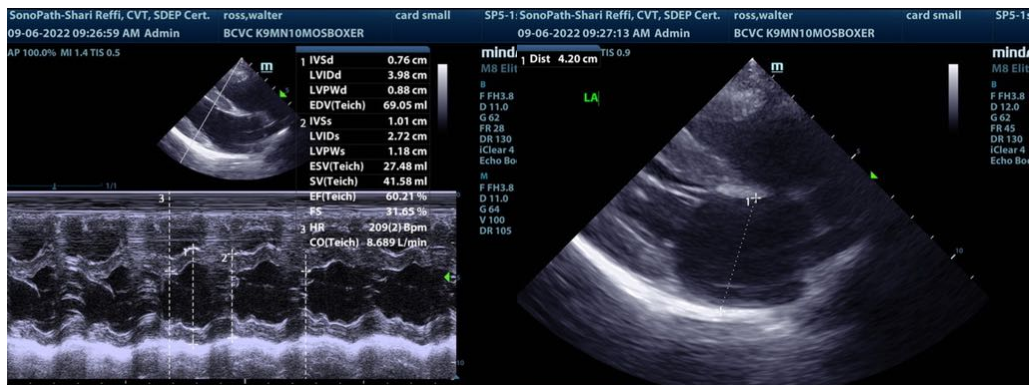
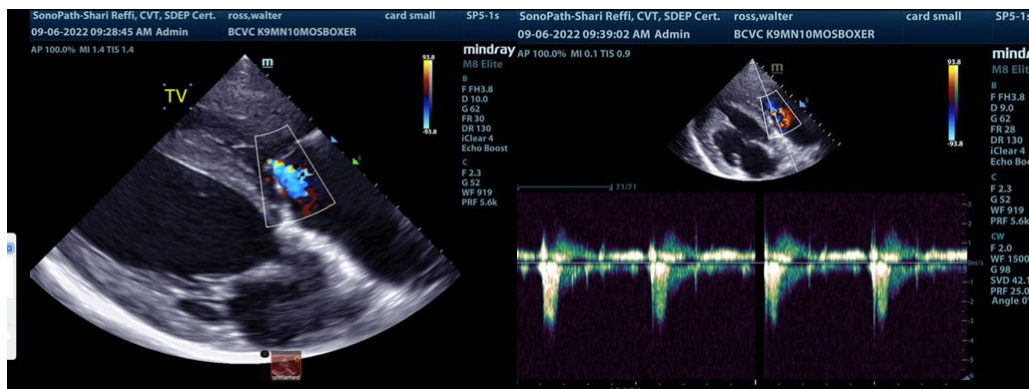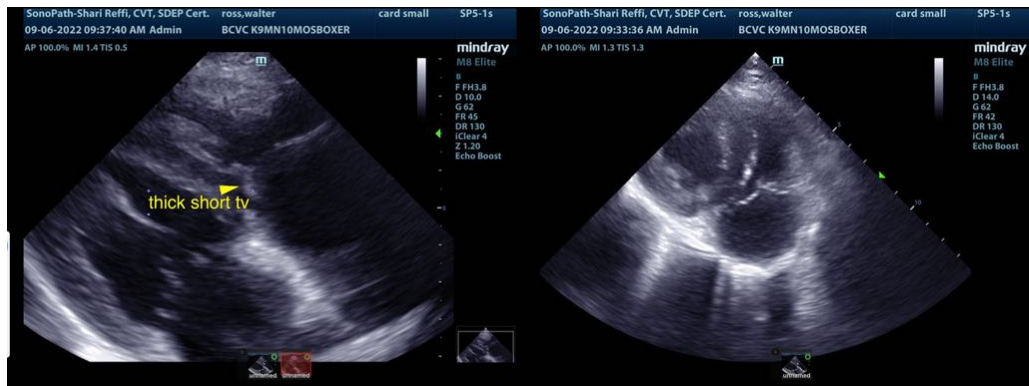
Dr. Talbot-Valerio

INVOICE

32739

DATE

9/6/22





PATIENT

Walter Ross

SPECIES

Canine

BREED

Boxer

SEX

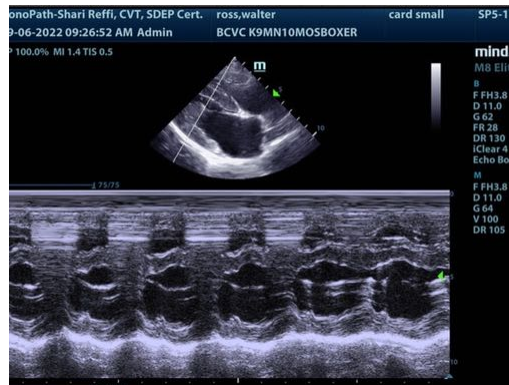
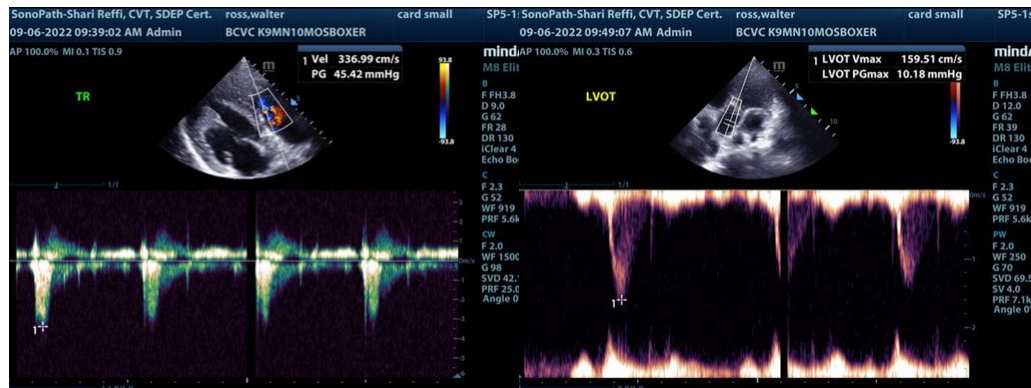
Neutered male

AGE

10 months

WEIGHT

74.5 lbs



INTERPRETED BY

Eric Lindquist, DMV
DABVP, Cert. IVUSS

IMAGING PERFORMED BY

Shari Reffi, CVT

HOSPITAL NAME

Branchville County VC

REFERRING VET

Dr. Talbot-Valerio

INVOICE

32739

DATE

9/6/22

The information and recommendations provided are based on the images presented by the referring veterinarian/sonographer. No evaluation can be communicated regarding pathology that was not visible in the image/video clips provided.

Thank you for this referral. If the clinical or image interpretation does not parallel your findings or if I can be of any further assistance please contact me.

Eric Lindquist, DMV, DABVP, Cert. IVUSS, CEO of SonoPath.com
Info@SonoPath.com