

**PATIENT**

Tyson Kali

**PRESENTING CLINICAL SIGNS**

History: hematuria; finished Clavamox a few days ago  
Abnormal PE/Chem/CBC/UA Results: UA: pH 5, UPC 1.7 incr.

**SPECIES**

Canine

**ULTRASONOGRAPHIC EXAMINATION OF THE ABDOMEN**  
**Urinary System**

**BREED**

Pitbull

The **urinary bladder** revealed an apical mass that measured 3.0 cm. Moderate blood flow to the mass was noted. The mass occupied the cranial half of the urinary bladder. The cystourethral junction and urethra were normal to approximately 3.0 cm.

**SEX**

Neutered male

The prostate was slightly heterogenous, yet there was no obvious evident metastasis.

**AGE**

10 years

The **kidneys** revealed normal size and structure, corticomedullary definition and ratio for this age. The cortices presented largely uniform texture with normal echogenic relationship to liver and spleen. Medullary structure differed distinctly from the cortex and no evidence of pelvic dilation was present. The capsules were acceptably uniform without significant irregularities. The right kidney measured 6.61 cm. The left kidney measured 6.54 cm.

**WEIGHT**

53.2 lbs

**Adrenal Glands**

Both **adrenal glands** were visualized and recognized as having normal shape, size, position and echogenicity for this breed. The phrenic vasculature, glandular echogenicity and detail were unremarkable. Capsule, cortex, and medullary definition were normal for this age patient. The left adrenal gland measured 2.32 x 0.68 cm at the caudal pole and 0.59 cm at the cranial pole. The right adrenal gland measured 2.93 x 2.06 cm at the cranial pole and 0.69 cm at the caudal pole.

**INTERPRETED BY**

Eric Lindquist, DMV  
DABVP, Cert. IVUSS

**Spleen**

The **spleen** presented a smooth homogeneous parenchyma hyperechoic to liver and renal cortical parenchyma. The capsule was smooth without noticeable expansion or deviation from within the spleen or adjacent pathology. The splenic vasculature demonstrated normal volume without signs of congestion or thrombosis. No sonographic evidence of acute or chronic inflammatory, neoplastic, or infarctual changes was noted.

**IMAGING PERFORMED BY**

Diane McFadden, RVT

**HOSPITAL NAME**

Animal Hospital of  
Roxbury

**Liver**

**REFERRING VET**

Dr. Flia

The **liver** images submitted revealed subjectively normal liver size, contour, and structure. Parenchymal echogenicity was naturally coarse and hypoechoic to the spleen. Vascular and biliary tracts were of normal volume with no evidence of congestion. The gallbladder presented acceptably thin walls with primarily anechoic content. The cystic and common bile ducts were normal. No pathological hepatic lymphadenopathy was evident. No overt structural evidence of inflammatory, infiltrative or regenerative pathology was evident.

**INVOICE**

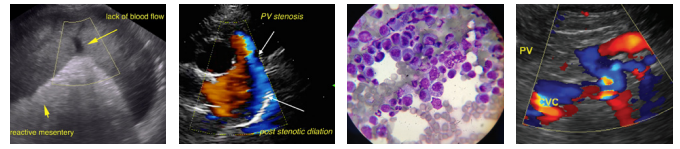
39809

**DATE**

9/29/22

**Gastrointestinal**

Examination of the **gastrointestinal tract** revealed a stomach and intestine free of stasis, of normal wall thickness, acceptable curvilinear mural detail, and peristaltic activity. Small and large intestine



**PATIENT**

Tyson Kali

demonstrated normal luminal chyme and stool consistency respectively. No obstructive or overt infiltrative disease was noted. No associated abnormal lymphatic activity was noted.

**SPECIES**

Canine

***Pancreas***

The base and limbs of the **pancreas** were observed to be largely isoechoic to surrounding omental fat. Pancreatic duct and capsular contour were acceptably normal and parenchyma respected normal curvilinear patterns. No overt evidence of active inflammatory or neoplastic disease was noted.

**BREED**

Pitbull

**ULTRASONOGRAPHIC FINDINGS**

**SEX**

Neutered male

Apical bladder mass, appears resectable. Carcinoma is likely.

**AGE**

10 years

**INTERPRETATION OF THE FINDINGS & FURTHER RECOMMENDATIONS**

There is a mild potential for chronic polypoid cystitis. Surgical intervention is recommended with removal of the cranial half of the urinary bladder is recommended. Traumatic catheterization with ultrasound-guidance can be considered to confirm suspicion of carcinoma.

**WEIGHT**

53.2 lbs

**INTERPRETED BY**

Eric Lindquist, DMV  
DABVP, Cert. IVUSS

**IMAGING PERFORMED BY**

Diane McFadden, RVT

**HOSPITAL NAME**

Animal Hospital of  
Roxbury

**REFERRING VET**

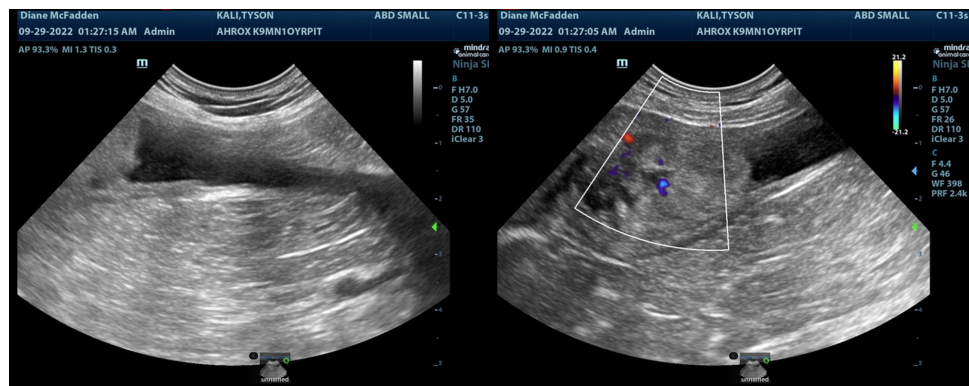
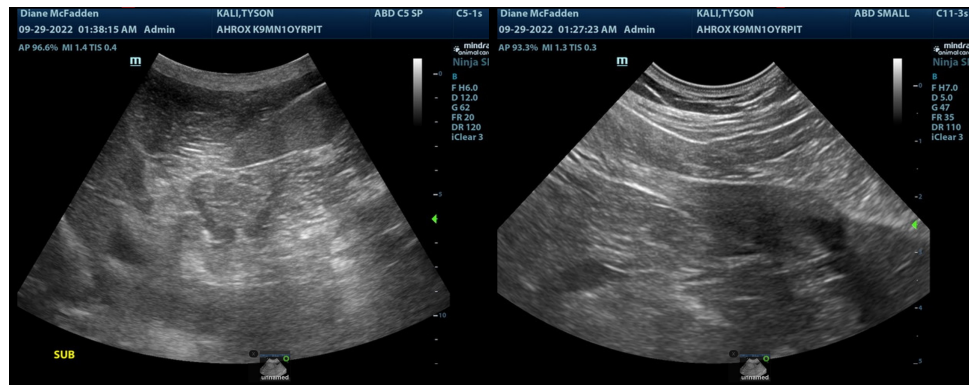
Dr. Flia

**INVOICE**

39809

**DATE**

9/29/22





**PATIENT**

Tyson Kali

**SPECIES**

Canine

**BREED**

Pitbull

**SEX**

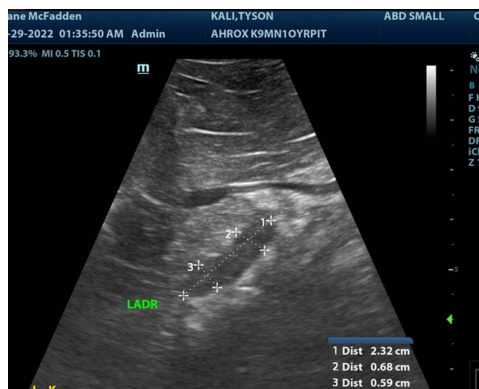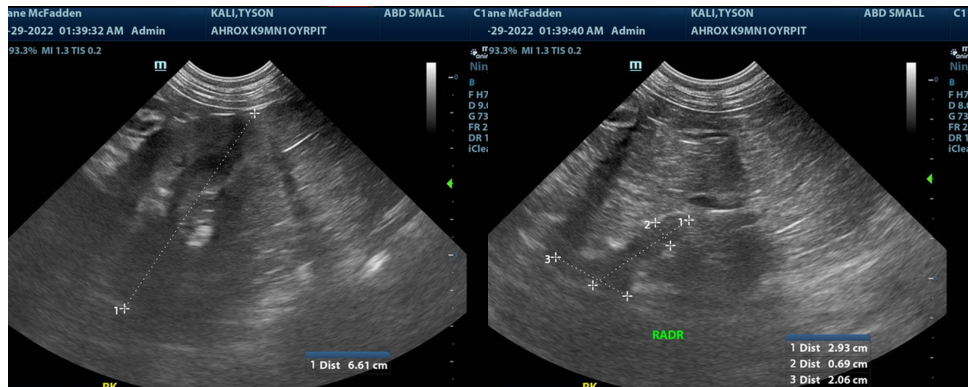
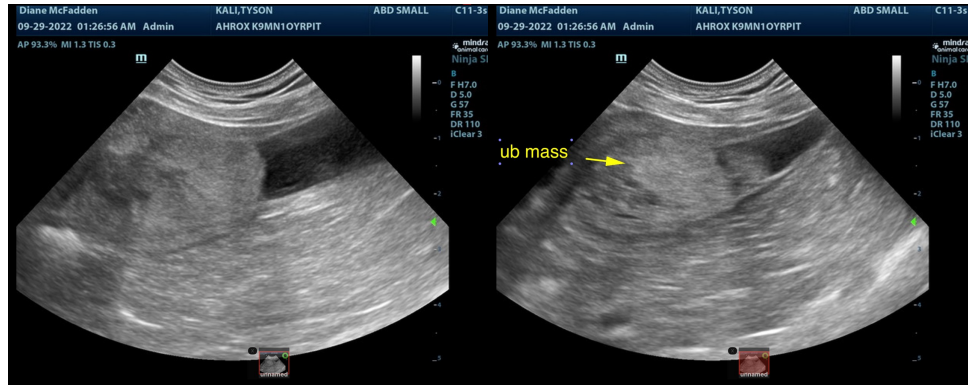
Neutered male

**AGE**

10 years

**WEIGHT**

53.2 lbs



**INTERPRETED BY**

Eric Lindquist, DMV  
DABVP, Cert. IVUSS

**IMAGING PERFORMED BY**

Diane McFadden, RVT

**HOSPITAL NAME**

Animal Hospital of  
Roxbury

**REFERRING VET**

Dr. Flia

**INVOICE**

39809

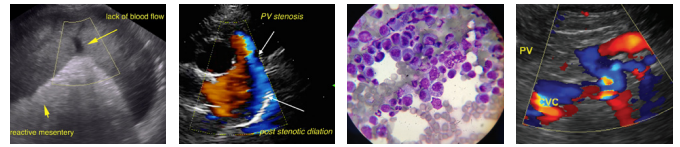
**DATE**

9/29/22

The information and recommendations provided are based on the images presented by the referring veterinarian/sonographer. No evaluation can be communicated regarding pathology that was not visible in the image/video clips provided.

Thank you for this referral. If the clinical or image interpretation does not parallel your findings or if I can be of any further assistance please contact me.

**Eric Lindquist, DMV, DABVP, Cert. IVUSS, CEO of SonoPath.com**  
Info@SonoPath.com



**PATIENT**

Tyson Kali

**SPECIES**

Canine

**BREED**

Pitbull

**SEX**

Nuetered male

**AGE**

10 years

**WEIGHT**

53.2 lbs

**INTERPRETED BY**

Eric Lindquist, DMV  
DABVP, Cert. IVUSS

**IMAGING  
PERFORMED BY**

Diane McFadden, RVT

**HOSPITAL NAME**

Animal Hospital of  
Roxbury

**REFERRING VET**

Dr. Flia

**INVOICE**

39809

**DATE**

9/29/22