



PATIENT PRESENTING CLINICAL SIGNS

Shoshanna Muenster History: screening echo

SPECIES ULTRASONOGRAPHIC EXAMINATION OF THE ABDOMEN

Canine

BREED

Maltese

SEX

Spayed female

AGE

3 years

The echocardiogram in this patient demonstrated normal **left atrial** size based on 3 separate methods of LA evaluation. The cranial and caudal **mitral** valve leaflets presented normal linear structure, extension in systole, and union in diastole with normal kinesis. The **left ventricle** presented normal thicknesses with linear contour and was not dilated nor restricted. The **myocardium** presented normal echogenicity without subjective evidence of significant fibrotic or ischemic disease. **Contractility** of the ventricular walls was adequate and in normal range for this patient evidenced by the fractional shortening measurement and subjective evaluation of the different regions of the myocardium. The **left ventricular outflow** tract demonstrated normal laminar flow and subjective structural integrity. The **right atrium** and auricle revealed normal size, structure and content. No evidence of masses was noted. **Tricuspid** valvular assessment demonstrated adequate linear morphology and kinesis. The **right ventricle** was of normal size (1/3 diameter of LV), chordae structure, myocardial echogenicity and thickness. **Pulmonary outflow** tract assessment revealed normal valve structure, laminar flow, and diameter (approx. 1:1 pa/ao ratio). No visible **pericardial** or free pleura fluid was noted. The cranial **mediastinum** and **pericardial and extra-cardiac regions** were free of masses in the visible window.

WEIGHT

CANINE CARDIAC PARAMETERS	MR VMAX (m/s)	TR VMAX (m/s)	LA/AO (Boon method)	LA/AO (Heart Base; Swe)	FS (%)	EF (%)	EPSS (cm)
NORMAL PARAMETER	4.5-5.5	<2.7	1.3	<1.6	28-40	40-100	<0.6
PATIENT			1.3	1.41	43	77	0.13
CANINE CARDIAC PARAMETERS	HR (BPM)	AV VMAX (m/s)	PV MAX (m/s)	BODY WEIGHT	LA (2D short axis Base view) (cm)	LVIDd (Avg; 2D and m-mode short axis) (cm)	LVIDs (Avg; 2D and m-mode short axis) (cm)
NORMAL PARAMETER	50-100	0.7-1.7	0.7-1.6	BELOW	BELOW	BELOW	BELOW
PATIENT	147	1.0	0.9	-	1.47	1.83	

INTERPRETED BY

Eric Lindquist, DMV DABVP, Cert. IVUSS

IMAGING PERFORMED BY

Diane McFadden, RVT

HOSPITAL NAME

Willowbrooc AC

REFERRING VET

Dr. Palescandolo

INVOICE

39661

DATE

9/28/22



PATIENT **ULTRASONOGRAPHIC FINDINGS**

Shoshanna Muenster Normal echocardiogram.

SPECIES **INTERPRETATION OF THE FINDINGS & FURTHER RECOMMENDATIONS**

Canine There is no evidence of pathology congenital or acquired.

BREED

Maltese

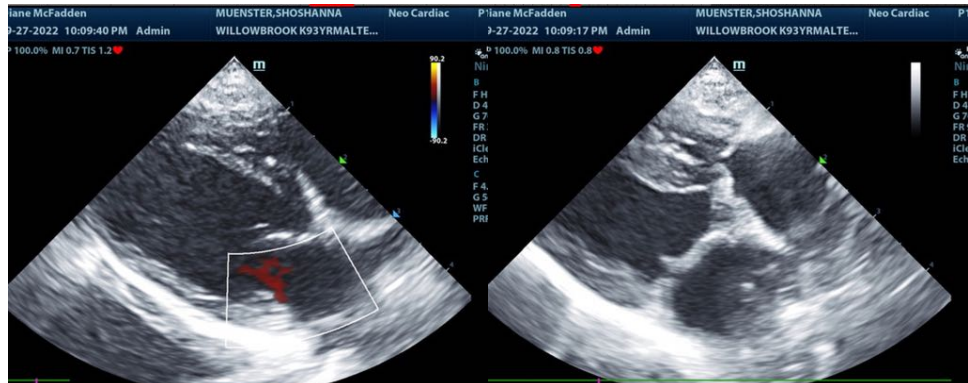
SEX

Spayed female

AGE

3 years

WEIGHT

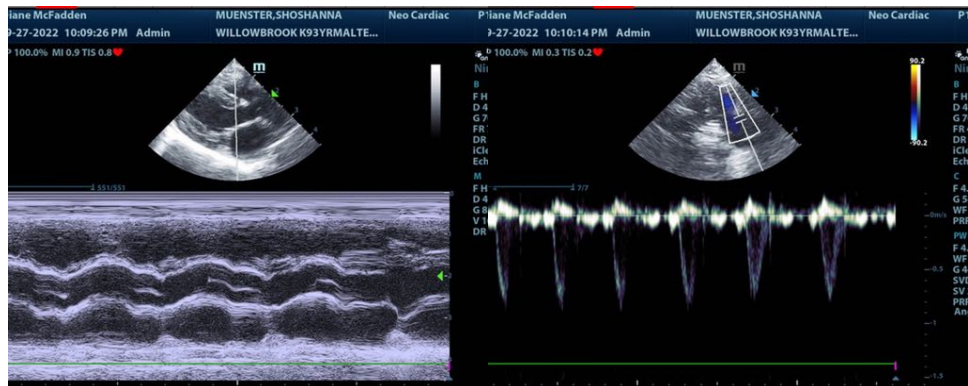


INTERPRETED BY

Eric Lindquist, DMV
DABVP, Cert. IVUSS

IMAGING PERFORMED BY

Diane McFadden, RVT



HOSPITAL NAME

Willowbrook AC

REFERRING VET

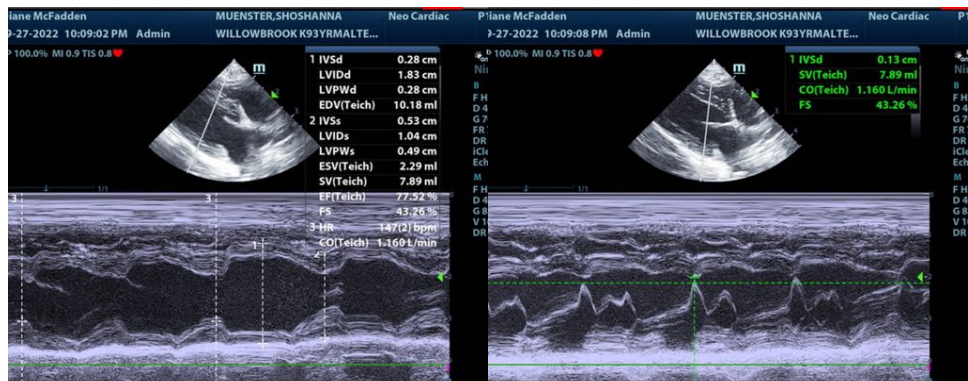
Dr. Palescandolo

INVOICE

39661

DATE

9/28/22





PATIENT

Shoshanna Muenster

SPECIES

Canine

BREED

Maltese

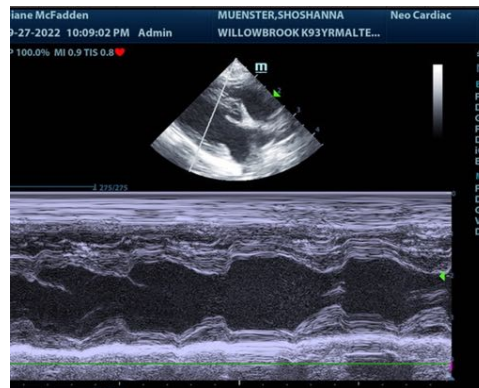
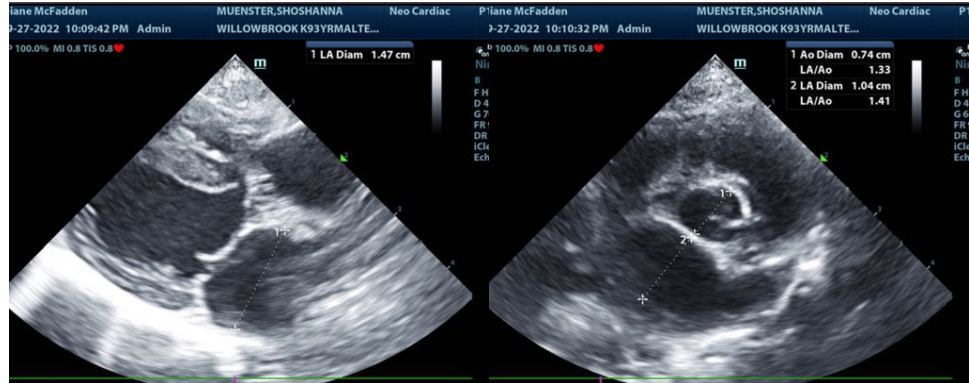
SEX

Spayed female

AGE

3 years

WEIGHT



INTERPRETED BY

Eric Lindquist, DMV
DABVP, Cert. IVUSS

IMAGING PERFORMED BY

Diane McFadden, RVT

HOSPITAL NAME

Willowbrooc AC

REFERRING VET

Dr. Palescandolo

INVOICE

39661

DATE

9/28/22

The information and recommendations provided are based on the images presented by the referring veterinarian/sonographer. No evaluation can be communicated regarding pathology that was not visible in the image/video clips provided.

Thank you for this referral. If the clinical or image interpretation does not parallel your findings or if I can be of any further assistance please contact me.

Eric Lindquist, DMV, DABVP, Cert. IVUSS, CEO of SonoPath.com
Info@SonoPath.com