

PATIENT PRESENTING CLINICAL SIGNS

Trace Hahn History of vomiting and urinating in crate.

SPECIES ULTRASONOGRAPHIC EXAMINATION OF THE ABDOMEN

Canine The **liver** was slightly heterogenous. The gallbladder and common bile duct were unremarkable. There was no evidence of vascular congestion.

BREED

Rottweiler

The midabdomen revealed a large, undifferentiated 15 x 30 + cm mass that appeared to be deriving from the mesenteric lymph nodes or intestinal tract. The duodenum was visualized; however, the stomach appeared to be deviated or enveloped by the mass. Areas of free fluid were noted. The visible spleen was unremarkable and could not be connected to the mass. The spleen had uniform parenchyma. The gastrointestinal tract was enveloped as well as portions of the pancreas with the mass itself.

SEX

Male

The **adrenal glands** were not visualized.

AGE

7 years

ULTRASONOGRAPHIC FINDINGS

INTERPRETED BY

Eric Lindquist, DMV
DABVP, Cert. IVUSS

Undifferentiated midabdominal mass with free fluid with omental involvement. Does not appear to be surgical.

IMAGING PERFORMED BY

Eric Lindquist, DMV
DABVP, Cert. IVUSS

INTERPRETATION OF THE FINDINGS & FURTHER RECOMMENDATIONS

CT evaluation of the abdomen and chest for metastatic disease as well as definition of the origin of the mass is recommended with FNA of the mass and possible liver. The prognosis long term is poor, yet may be chemoresponsive.

HOSPITAL NAME

Andover AH

REFERRING VET

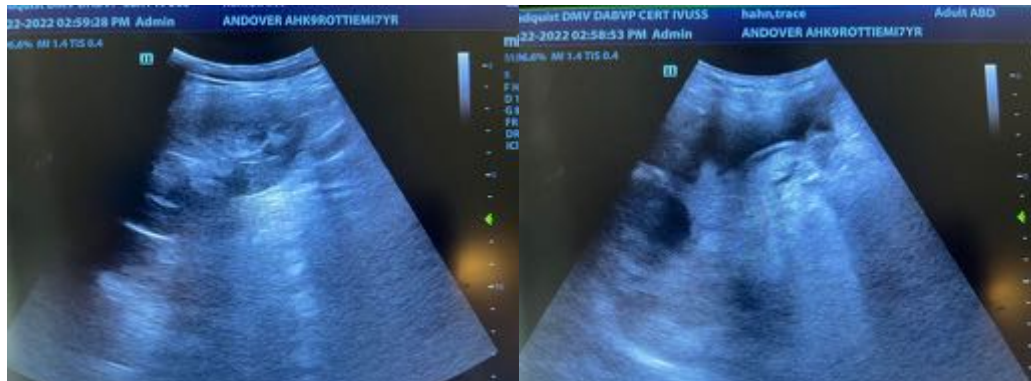Dr. Lind

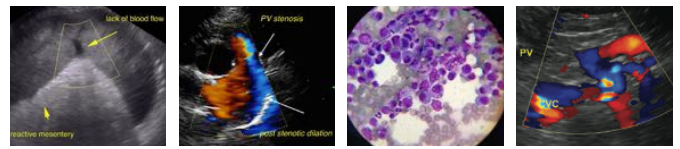
INVOICE

39555

DATE

9/22/22





PATIENT

Trace Hahn

SPECIES

Canine

BREED

Rottweiler

SEX

Male

AGE

7 years

INTERPRETED BY

Eric Lindquist, DMV
DABVP, Cert. IVUSS

IMAGING PERFORMED BY

Eric Lindquist, DMV
DABVP, Cert. IVUSS

HOSPITAL NAME

Andover AH

REFERRING VET

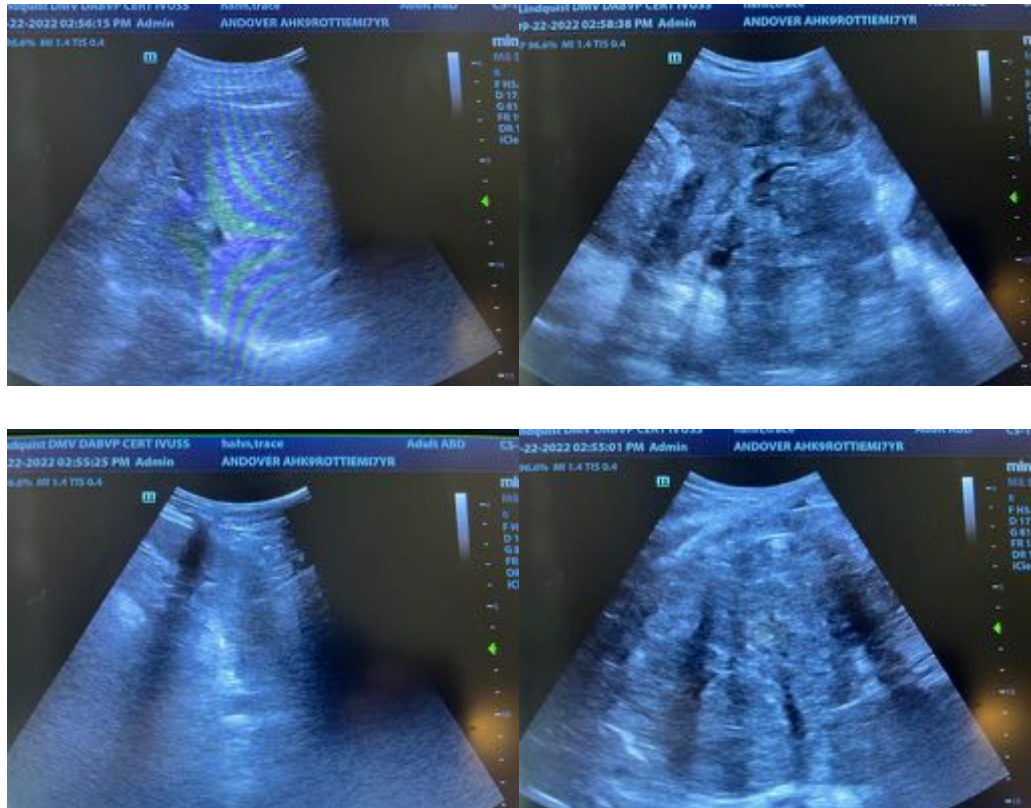
Dr. Lind

INVOICE

39555

DATE

9/22/22



The information and recommendations provided are based on the images presented by the referring veterinarian/sonographer. No evaluation can be communicated regarding pathology that was not visible in the image/video clips provided.

Thank you for this referral. If the clinical or image interpretation does not parallel your findings or if I can be of any further assistance please contact me.

Eric Lindquist, DMV, DABVP, Cert. IVUSS, CEO of SonoPath.com
Info@SonoPath.com