



PATIENT

Tigger Munoz

PRESENTING CLINICAL SIGNS

History: elevated kidney values, PD, urinating outside box. Currently on clavamox
Abnormal PE/Chem/CBC/UA Results: BUN 47, Crea 27, Na/K 45, SDMA 20.6

SPECIES

Feline

ULTRASONOGRAPHIC EXAMINATION OF THE ABDOMEN
Urinary System

BREED

Domestic Shorthair

The **urinary bladder**, trigone, and pelvic urethra presented normal thicknesses and normal tone. The ureters were not visible which is normal. No uroliths or sediment were visualized and anechoic urine was present. No evidence of inflammatory or neoplastic changes was noted. Ureteral papillae were normal.

SEX

Spayed female

The **kidneys** presented a relatively uniform cortical hyperechogenicity when compared to the renal medulla, spleen and liver. No overt masses were noted. Corticomedullary definition was nebulous and the ratio favored the cortex slightly. The ureters were not visible and assumed to be normal. These changes are most consistent with chronic interstitial nephritis yet infiltrative disease could not be entirely ruled out without biopsy though neoplasia is not suspected. The kidneys revealed infarcts particularly the right kidney with cortical collapse. The left kidney also revealed cortical collapse and infarcts. Mineralization was noted in the kidneys. Significant disrupted architecture was noted. The patient may have passed calculi periodically including the current clinical status. The right kidney measured 4.26 cm.

AGE

5 years

WEIGHT

10.9 lbs

INTERPRETED BY

Eric Lindquist, DMV
DABVP, Cert. IVUSS

Adrenal Glands

Both **adrenal glands** were visualized and recognized as having normal shape, size, position and echogenicity for this breed. The phrenic vasculature, glandular echogenicity and detail were unremarkable. Capsule, cortex, and medullary definition were normal for this age patient. The right adrenal gland measured 0.31 cm. The left adrenal gland measured 0.34 cm.

IMAGING PERFORMED BY

Diane McFadden, RVT

Spleen

The **spleen** was mildly enlarged with uniform, but subtly micronodular parenchyma, and undulating capsular contour. This is consistent with reactive spleen owing to immune stimulus or early infiltrative disease such as mast cell disease or lymphoma. 25-gauge FNA would be ideal if weight loss is an issue to differentiate early round cell neoplasia versus splenitis or reactive spleen all of which can present in this manner. The spleen measured 1.2 cm in width.

HOSPITAL NAME

Animal Hospital of
Roxbury

REFERRING VET

Dr. Flia

INVOICE

39569

Liver

The **liver** images submitted revealed subjectively normal liver size, contour, and structure. Parenchymal echogenicity was naturally coarse and hypoechoic to the spleen. Vascular and biliary tracts were of normal volume with no evidence of congestion. The gallbladder presented acceptably thin walls with primarily anechoic content. The cystic and common bile ducts were normal. No pathological hepatic lymphadenopathy was evident. No overt structural evidence of inflammatory, infiltrative or regenerative pathology was evident.

DATE

9/15/22



PATIENT

Gastrointestinal

Tigger Munoz

There was some residual chyme and gas noted in the **stomach**, yet not pathological. This is consistent with end post prandial presentation. Transit of chyme into the small intestine was normal. Curvilinear patterns were maintained throughout the GI tract. No evidence of pathology. Small and large intestine demonstrated normal luminal chyme and stool consistency respectively. No obstructive or overt infiltrative disease was noted. No associated abnormal lymphatic activity was noted.

SPECIES

Feline

BREED

Domestic Shorthair

Pancreas

The base and limbs of the **pancreas** were observed to be largely isoechoic to surrounding omental fat. Pancreatic duct and capsular contour were acceptably normal and parenchyma respected normal curvilinear patterns. No overt evidence of active inflammatory or neoplastic disease was noted.

SEX

Spayed female

ULTRASONOGRAPHIC FINDINGS

AGE

5 years

Renal dystrophy.

Reactive spleen.

WEIGHT

10.9 lbs

INTERPRETATION OF THE FINDINGS & FURTHER RECOMMENDATIONS

Full urinary work-up, 72 hour IV fluid protocol and blood pressure measurements are all indicated. FNA of the spleen would be ideal. There is a minor potential for emerging splenic neoplasia.

INTERPRETED BY

Eric Lindquist, DMV
DABVP, Cert. IVUSS

IMAGING PERFORMED BY

Diane McFadden, RVT

HOSPITAL NAME

Animal Hospital of
Roxbury

REFERRING VET

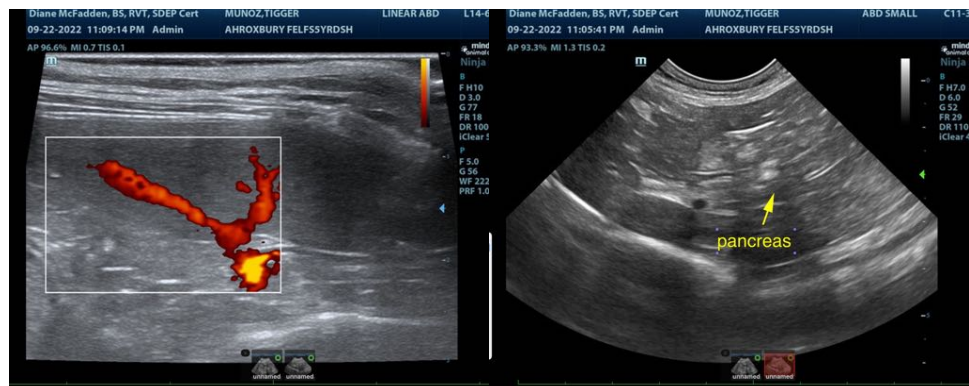
Dr. Flia

INVOICE

39569

DATE

9/15/22





PATIENT

Tigger Munoz

SPECIES

Feline

BREED

Domestic Shorthair

SEX

Spayed female

AGE

5 years

WEIGHT

10.9 lbs

INTERPRETED BY

Eric Lindquist, DMV
DABVP, Cert. IVUS

IMAGING PERFORMED BY

Diane McFadden, RVT

HOSPITAL NAME

Animal Hospital of
Roxbury

REFERRING VET

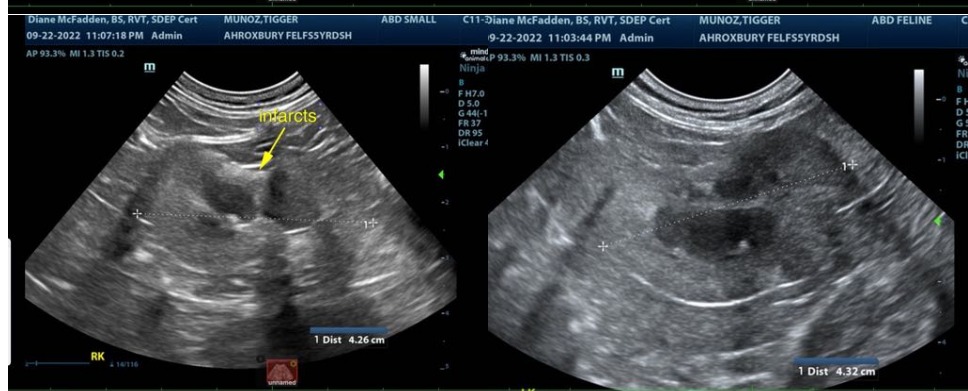
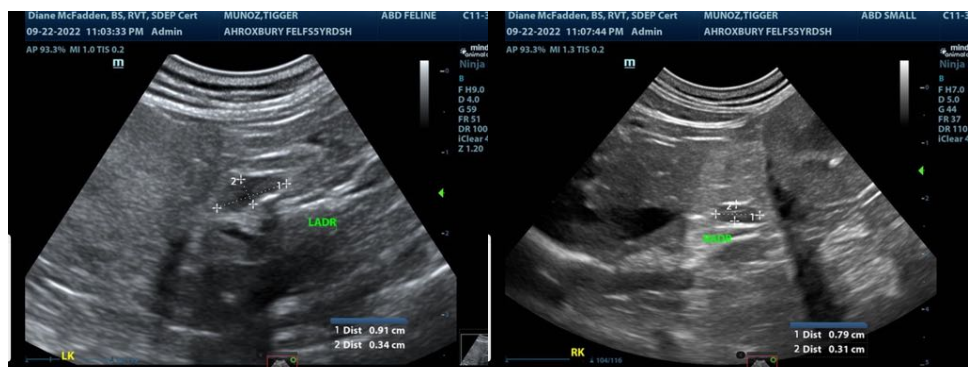
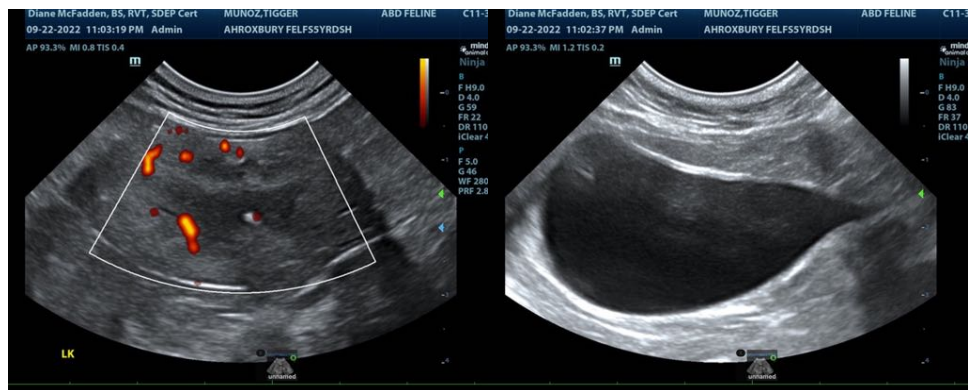
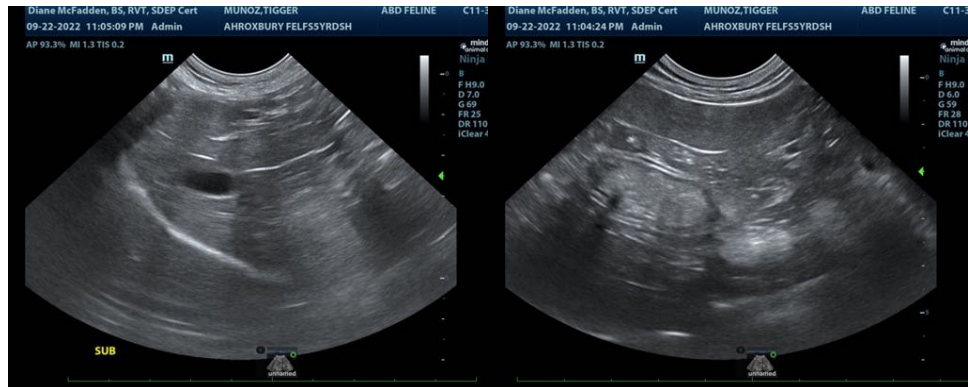
Dr Flia

INVOICE

39569

DATE

9/15/22





PATIENT

Tigger Munoz

The information and recommendations provided are based on the images presented by the referring veterinarian/sonographer. No evaluation can be communicated regarding pathology that was not visible in the image/video clips provided.

SPECIES

Feline

Thank you for this referral. If the clinical or image interpretation does not parallel your findings or if I can be of any further assistance please contact me.

BREED

Domestic Shorthair

Eric Lindquist, DMV, DABVP, Cert. IVUSS, CEO of SonoPath.com
Info@SonoPath.com

SEX

Spayed female

AGE

5 years

WEIGHT

10.9 lbs

INTERPRETED BY

Eric Lindquist, DMV
DABVP, Cert. IVUSS

**IMAGING
PERFORMED BY**

Diane McFadden, RVT

HOSPITAL NAME

Animal Hospital of
Roxbury

REFERRING VET

Dr. Flia

INVOICE

39569

DATE

9/15/22