

PATIENT

Chovan Wobble

PRESENTING CLINICAL SIGNS

Irregular rhythm with grade II/VI heart murmur.

SPECIES

Feline

BREED

Maine Coon Mix

SEX

Neutered male

AGE

15 years

INTERPRETED BY

Eric Lindquist, DMV
DABVP, Cert. IVUSS

IMAGING PERFORMED BY

Eric Lindquist, DMV
DABVP, Cert. IVUSS

HOSPITAL NAME

Franklin Lakes AH

ULTRASONOGRAPHIC EXAMINATION OF THE HEART

The echocardiogram in this patient revealed a thorax free of effusion and masses. The heart revealed normal pericardium and chamber sizes with persistent arrhythmia. Myocardial remodeling was noted with sectorial hypertrophy and sectorial retraction. Mitral and tricuspid insufficiency was noted. Mitral insufficiency was > 4.0 m/sec and tricuspid insufficiency was noted at 1.7 m/sec. The outflow velocities were normal. Contractility was adequate, however, persistent and consistent arrhythmia was noted. This may represent hypertrophic cardiomyopathy patient with remodeling and now arrhythmogenic activity.

FELINE CARDIAC PARAMETERS	BODY WEIGHT (kg)	HR (BPM)	IVSd (cm)	LVIDd (cm)	LVWd (cm)	FS (%)	EF (%)
NORMAL PARAMETER	-----	150-240	0.3-0.6	1.0-2.1	0.25-0.6	35-67	80-100
PATIENT		Variable 205	0.44	1.17	0.55	60	93
FELINE CARDIAC PARAMETERS	LA/AO (Boon)	LA/AO HEART BASE (Sisson)	LA 2D 4-chamber long axis AS to FW (Sisson) (cm)		LVOT VEL. (m/s)	RVOT VEL. (m/s)	IVRT (m)
NORMAL PARAMETER	<1.5	0.88-1.79	0.7-1.7		<1.6	<1.3	40-60
PATIENT	1.25	1.2	1.3		1.25	1.0	NM
Adapted from June Boon, Veterinary Echocardiography, 1998 Sisson D et al. JVIM 1991; 5: 232, Jacobs et al. Am J Vet Res 1985; 46:1705							

REFERRING VET

Dr. Hudson

ULTRASONOGRAPHIC FINDINGS

Persistent arrhythmia.
Sectorial hypertrophy and retraction.
Mitral and tricuspid insufficiency.

INVOICE

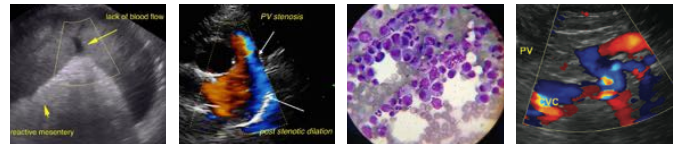
39556

DATE

9/22/22

INTERPRETATION OF THE FINDINGS & FURTHER RECOMMENDATIONS

No cardiac treatment was recommended. However, blood pressure measurements, thyroid and EKG monitoring is important. Based on the echocardiogram and the frequency of the arrhythmia anti-arrhythmic therapy would likely be in this patient's best interest. Plavix therapy is debatable, yet is not contraindicated.



PATIENT

Chovan Wobble

SPECIES

Feline

BREED

Maine Coon Mix

SEX

Neutered male

AGE

15 years

INTERPRETED BY

Eric Lindquist, DMV
DABVP, Cert. IVUSS

IMAGING PERFORMED BY

Eric Lindquist, DMV
DABVP, Cert. IVUSS

HOSPITAL NAME

Franklin Lakes AH

REFERRING VET

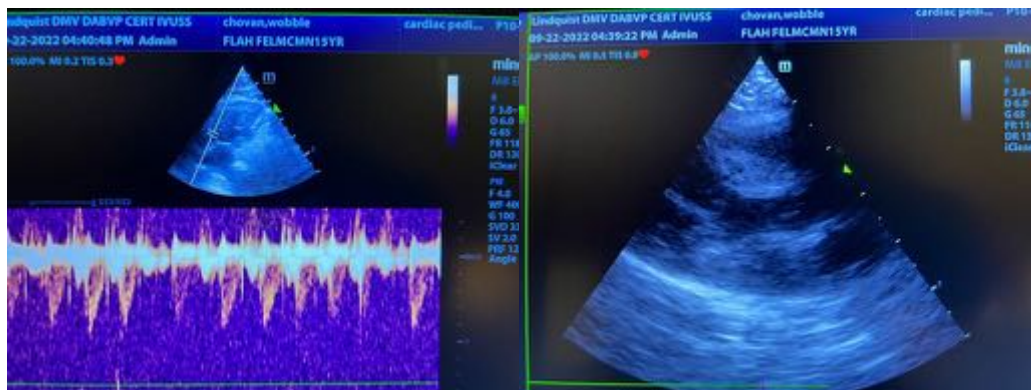
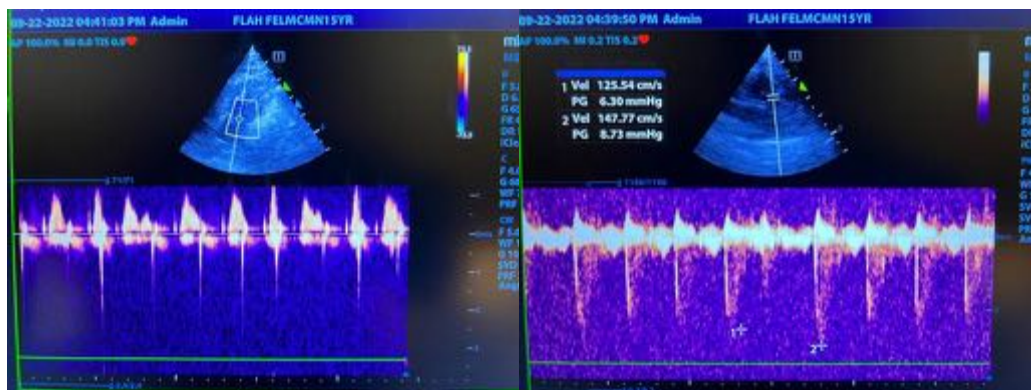
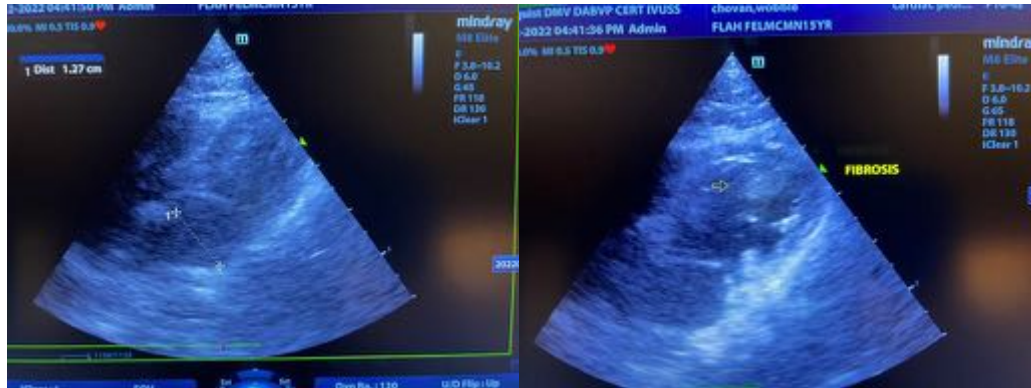
Dr. Hudson

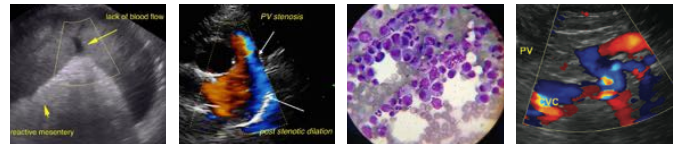
INVOICE

39556

DATE

9/22/22





PATIENT

Chovan Wobble

SPECIES

Feline

BREED

Maine Coon Mix

SEX

Neutered male

AGE

15 years

INTERPRETED BY

Eric Lindquist, DMV
DABVP, Cert. IVUSS

IMAGING PERFORMED BY

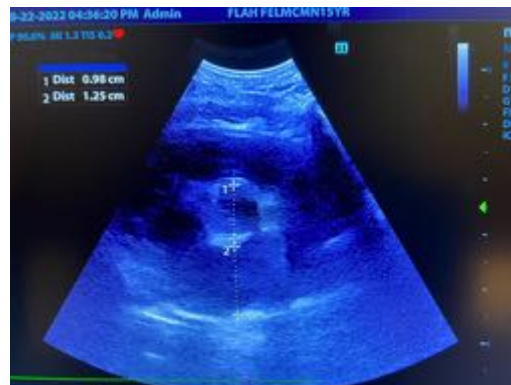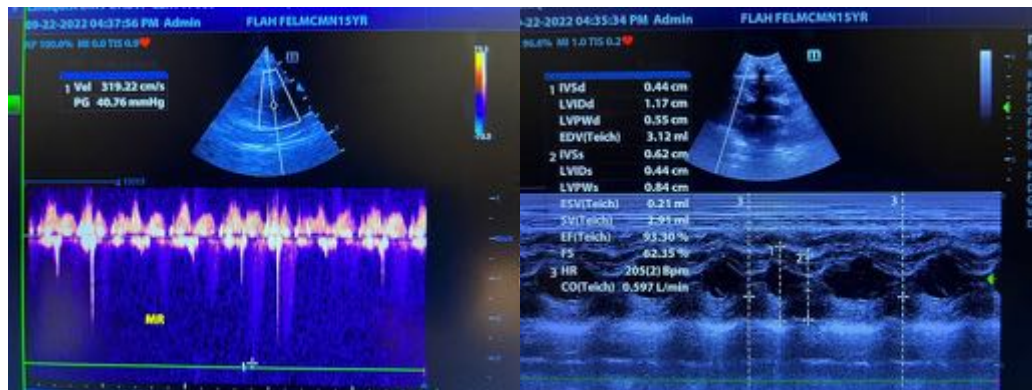
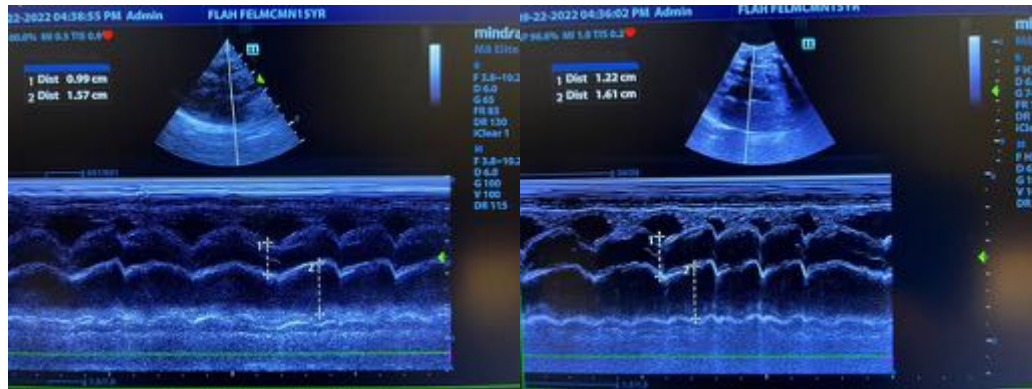
Eric Lindquist, DMV
DABVP, Cert. IVUSS

HOSPITAL NAME

Franklin Lakes AH

REFERRING VET

Dr. Hudson



INVOICE

39556

DATE

9/22/22

The information and recommendations provided are based on the images presented by the referring veterinarian/sonographer. No evaluation can be communicated regarding pathology that was not visible in the image/video clips provided.

Thank you for this referral. If the clinical or image interpretation does not parallel your findings or if I can be of any further assistance please contact me.

Eric Lindquist, DMV, DABVP, Cert. IVUSS, CEO of SonoPath.com
Info@SonoPath.com