



PATIENT PRESENTING CLINICAL SIGNS

Lily Newman Recheck echo (prev. report attached) Grade II-III/VI L side heart murmur. Stable. Current meds: Apoquel 3.6mg 1/2 t sid
Abnormal PE/Chem/CBC/UA Results: 2/2022-ALKP 418

SPECIES

Canine

ULTRASONOGRAPHIC EXAMINATION OF THE HEART

BREED

Maltese Mix

The echocardiogram in this patient presented mitral and tricuspid insufficiency with adequate contractility and no evidence of volume overload. The right and left ventricular outflow velocities were normal. Slight prolapse of the anterior mitral valve was noted. Periodic arrhythmia is noted in this patient. This is likely a sinus arrhythmia.

SEX

Spayed female

AGE

11 years

WEIGHT

7.1 lbs

CANINE CARDIAC PARAMETERS	MR VMAX (m/s)	TR VMAX (m/s)	LA/AO (Boon method)	LA/AO (Heart Base; Swe)	FS (%)	EF (%)	EPSS (cm)
NORMAL PARAMETER	4.5-5.5	<2.7	1.3	<1.6	28-40	40-100	<0.6
PATIENT	6.32	1.61	NM	1.5	35	67	0.3
CANINE CARDIAC PARAMETERS	HR (BPM)	AV VMAX (m/s)	PV MAX (m/s)	BODY WEIGHT	LA (2D short axis Base view) (cm)	LVIDd (Avg; 2D and m-mode short axis) (cm)	LVIDs (Avg; 2D and m-mode short axis) (cm)
NORMAL PARAMETER	50-100	0.7-1.7	0.7-1.6	BELOW	BELOW	BELOW	BELOW
PATIENT	152	1.4	0.97	7.1 lbs	2.77	2.76	

INTERPRETED BY

Eric Lindquist, DMV DABVP, Cert. IVUSS

IMAGING PERFORMED BY

Shari Reffi, CVT

HOSPITAL NAME

Animal Care Center of Flanders

REFERRING VET

Dr. Hallihan

ULTRASONOGRAPHIC FINDINGS

B1 valvular disease, compensated.
Periodic arrhythmia, likely sinus arrhythmia.

INTERPRETATION OF THE FINDINGS & FURTHER RECOMMENDATIONS

No medication is recommend at this time. EKG is warranted as well as blood pressure measurements.

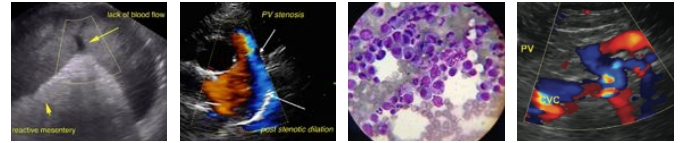
INVOICE

32255

DATE

8/9/22

The heart is stable without clinical disease. No overt contraindication for anesthesia of brief to moderate duration. I suggest Torbutrol premed, Propofol induction, Isoflor maintenance or similar protocol if anesthesia is desired. Blood pressure recommended if not already performed and target white coat negative systolic pressure of < 160 mmHg. If higher than this ACE-inhibitor is suggested to reach this level. Recheck echocardiogram is recommended in 6 months, earlier if murmur grade increases or clinical signs initiate.



PATIENT

Lily Newman

SPECIES

Canine

BREED

Maltese Mix

SEX

Spayed female

AGE

11 years

WEIGHT

7.1 lbs

INTERPRETED BY

Eric Lindquist, DMV
DABVP, Cert. IVUSS

IMAGING PERFORMED BY

Shari Reffi, CVT

HOSPITAL NAME

Animal Care Center of
Flanders

REFERRING VET

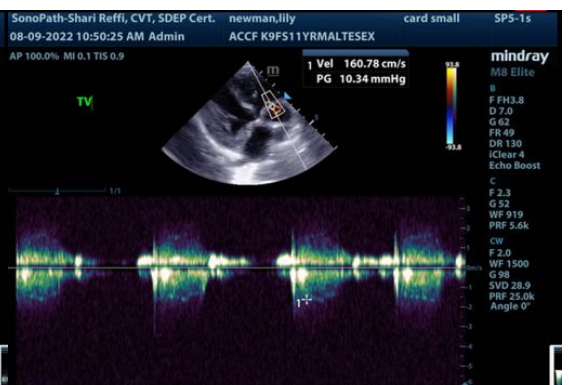
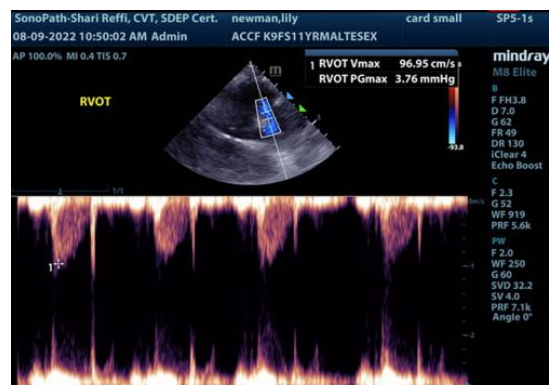
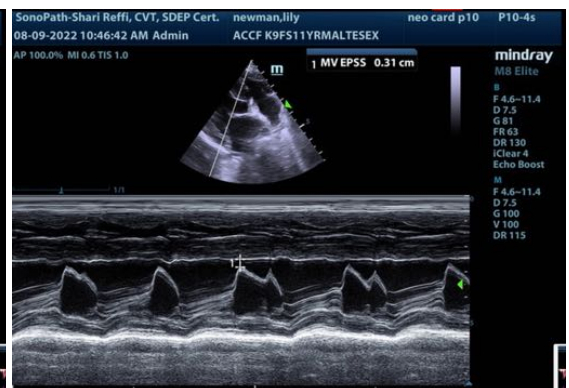
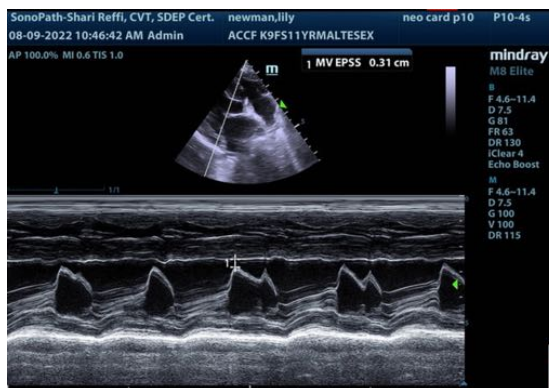
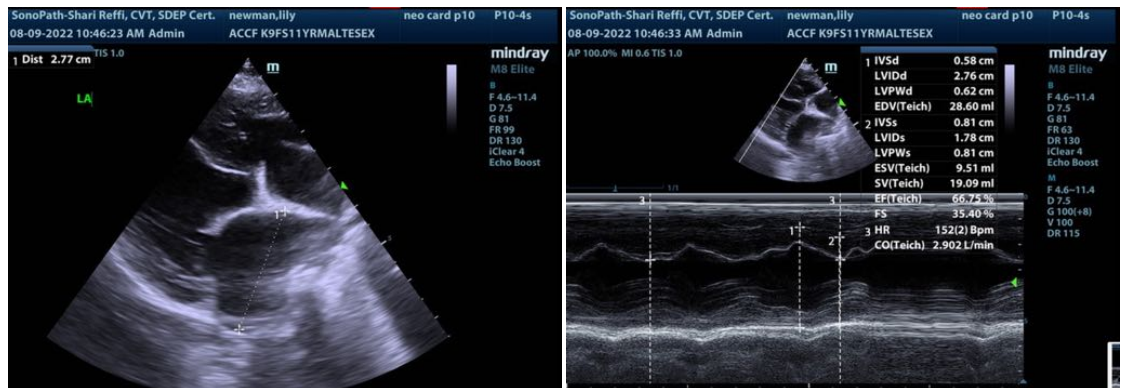
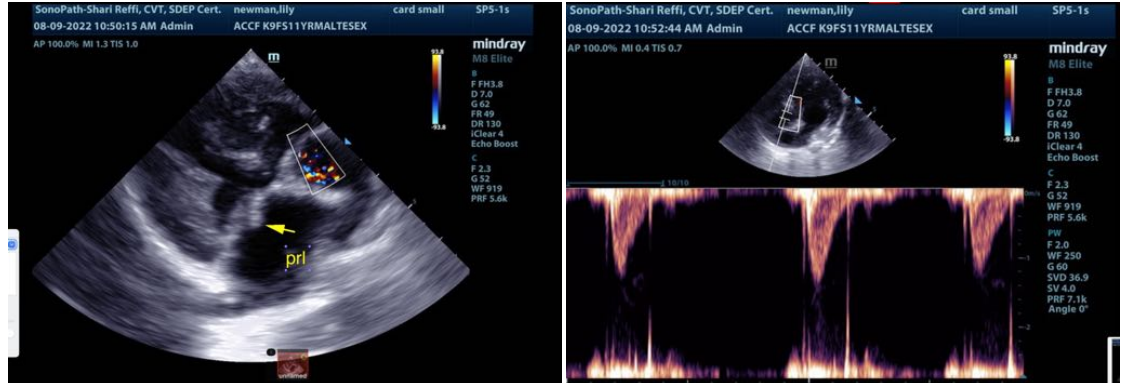
Dr. Hallihan

INVOICE

32255

DATE

8/9/22





PATIENT

Lily Newman

SPECIES

Canine

BREED

Maltese Mix

SEX

Spayed female

AGE

11 years

WEIGHT

7.1 lbs

INTERPRETED BY

Eric Lindquist, DMV
DABVP, Cert. IVUSS

IMAGING PERFORMED BY

Shari Reffi, CVT

HOSPITAL NAME

Animal Care Center of
Flanders

REFERRING VET

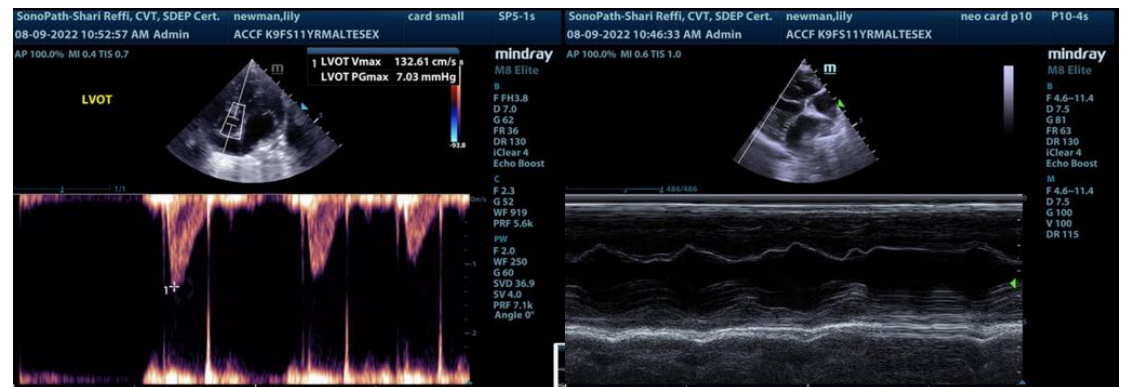
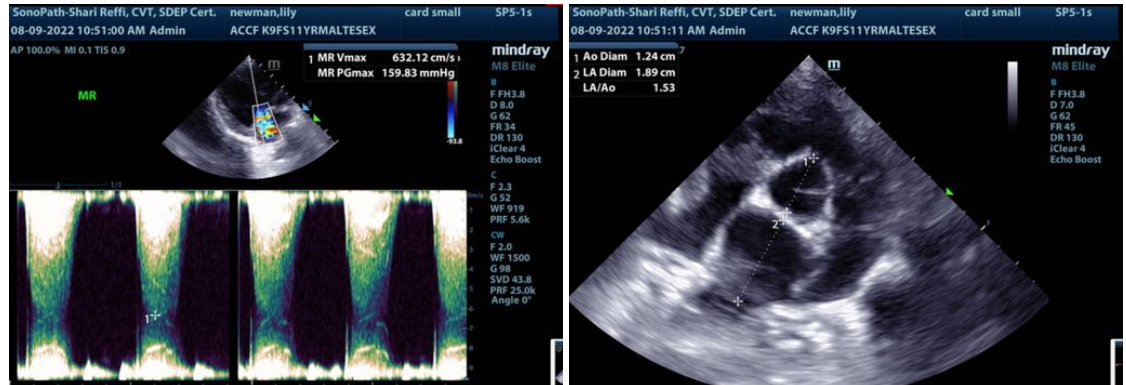
Dr. Hallihan

INVOICE

32255

DATE

8/9/22



The information and recommendations provided are based on the images presented by the referring veterinarian/sonographer. No evaluation can be communicated regarding pathology that was not visible in the image/video clips provided.

Thank you for this referral. If the clinical or image interpretation does not parallel your findings or if I can be of any further assistance please contact me.

Eric Lindquist, DMV, DABVP, Cert. IVUSS, CEO of SonoPath.com
Info@SonoPath.com