



**PATIENT PRESENTING CLINICAL SIGNS**

Munson Ritzer

History: Grade II/VI heart murmur; owner reports collapse/seizure after coughing, pet is otherwise normal. No current meds.  
Abnormal PE/Chem/CBC/UA Results: Pending

**SPECIES**

Canine

**ULTRASONOGRAPHIC EXAMINATION OF THE HEART**

**BREED**

Shih Tzu

**SEX**

Male

**AGE**

10 years

**WEIGHT**

16.4 lbs

The echocardiogram in this patient demonstrated enlarged **left atrial** size based on 3 different LA measurement methods. Chamber volumes and echogenicity were normal. The cranial and caudal **mitral** valve leaflets presented vegetative thickening consistent with endocardiosis. Complete filling of the left and right atria were noted on color flow Doppler of the mitral and tricuspid insufficiency respectively. Doppler indicated measurable insufficiency. The **left ventricle** presented thicknesses with linear contour and was not dilated nor restricted. The **myocardium** presented normal echogenicity without subjective evidence of significant fibrotic or ischemic disease. **Contractility** of the ventricular walls was adequate and in normal range for this patient evidenced by the fractional shortening measurement and subjective evaluation of the different regions of the myocardium. The **left ventricular outflow** tract demonstrated normal laminar flow and subjective structural integrity. The **right atrium** and auricle revealed normal size, structure and content. No evidence of masses was noted or chamber overload. **Tricuspid** insufficiency was noted. The **right ventricle** was of normal size (1/3 diameter of LV), chordae structure, myocardial echogenicity and thickness. **Pulmonic** tract assessment revealed normal valve structure, laminar flow, and diameter (approx. 1:1 pa/ao ratio). No visible **pericardial** or free pleura fluid was noted. No echographically detectable evidence of infiltrative disease was visible. The cranial **mediastinum and pericardial regions** were free of masses in the visible window.

**INTERPRETED BY**

Eric Lindquist, DMV  
DABVP, Cert. IVUSS

**IMAGING PERFORMED BY**

Shari Reffi, CVT

**HOSPITAL NAME**

Byram AH

**REFERRING VET**

Dr. Abdul-Chani

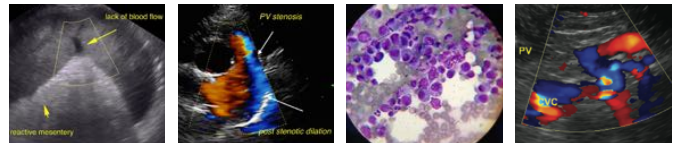
CANINE CARDIAC PARAMETERS	MR VMAX (m/s)	TR VMAX (m/s)	LA/AO (Boon method)	LA/AO (Heart Base; Swe)	FS (%)	EF (%)	EPSS (cm)
NORMAL PARAMETER	4.5-5.5	<2.7	1.3	<1.6	28-40	40-100	<0.6
PATIENT	5.46	3.3	1.8	2.0	47	79	NM
CANINE CARDIAC PARAMETERS	HR (BPM)	AV VMAX (m/s)	PV MAX (m/s)	BODY WEIGHT (kg)	LA (2D short axis Base view) (cm)	LVIDd (Avg; 2D and m-mode short axis) (cm)	LVIDs (Avg; 2D and m-mode short axis) (cm)
NORMAL PARAMETER	50-100	0.7-1.7	0.7-1.6	BELOW	BELOW	BELOW	BELOW
PATIENT	76	1.1	0.75	16.4 lbs	4.1	3.96	

**INVOICE**

32668

**DATE**

8/31/22



**PATIENT** **ULTRASONOGRAPHIC FINDINGS**

Munson Ritzer

Mitral and tricuspid insufficiency with moderate left atrial enlargement and mild early pulmonary hypertension.

**SPECIES**

Advanced stage B2 valvular disease.

Canine

**BREED**

Shih Tzu

**SEX**

Male

**AGE**

10 years

**WEIGHT**

16.4 lbs

**INTERPRETATION OF THE FINDINGS & FURTHER RECOMMENDATIONS**

Given the collapse and seizure post cough two separate scenarios may be playing a role. Valvular disease and volume overload may be an issue as well as ‘cough drop syndrome’ which is a vagal tone issue and would necessitate a Holter monitor or event monitor for Evaluation. I recommend Pimobendan at 0.3-mg/kg b.i.d. Consideration to ace inhibitor at 0.5 mg/kg s.i.d. progressing to b.i.d. and Spironolactone at 1-2 mg/kg b.i.d. Sleeping respiratory rate, further coughing and collapsing episodes should be monitored carefully as well as blood pressure measurements, BUN and creatinine.

The heart has some volume overload and is working to compensate for the valvular insufficiency. Target respiratory rate is < 20 resp/minute after therapy. After initiating therapy, I recommend recheck on the clinical exam, BUN, Creatinine, USG, Chest radiographs & Blood pressure in 5-7 days. Recheck echo in 1 month. Earlier if clinical decompensation is occurring. I do not recommend anesthesia at this time until stabilization has occurred on the recommended medications. Repeat preanesthetic echo is ideal if anesthesia is eventually necessary

**INTERPRETED BY**

Eric Lindquist, DMV  
DABVP, Cert. IVUSS

**IMAGING PERFORMED BY**

Shari Reffi, CVT

**HOSPITAL NAME**

Byram AH

**REFERRING VET**

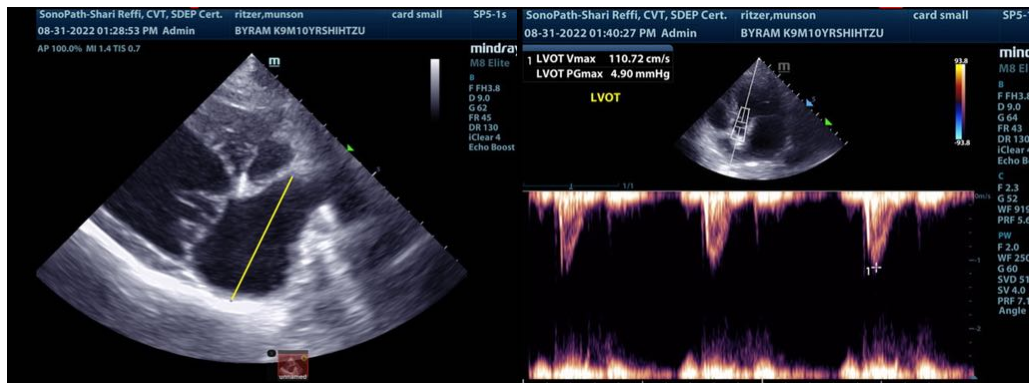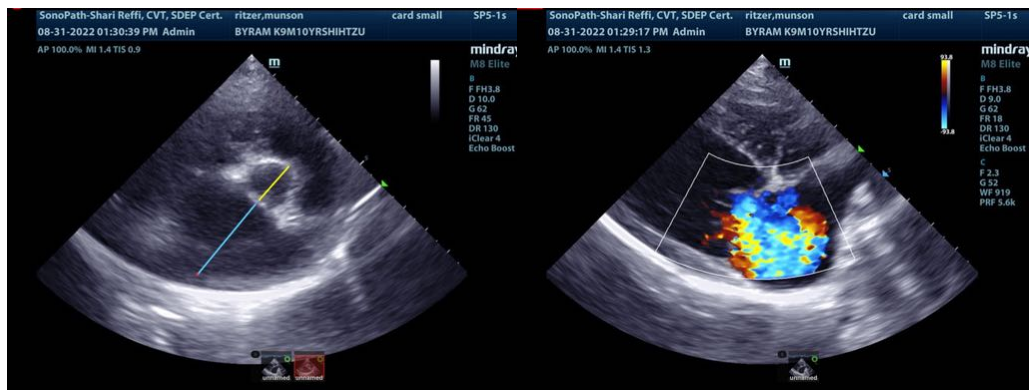
Dr. Abdul-Chani

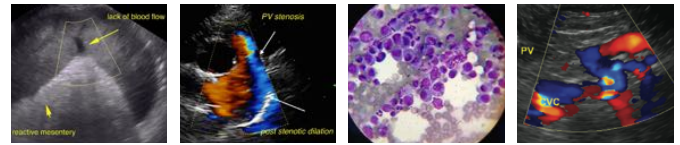
**INVOICE**

32668

**DATE**

8/31/22





**PATIENT**

Munson Ritzer

**SPECIES**

Canine

**BREED**

Shih Tzu

**SEX**

Male

**AGE**

10 years

**WEIGHT**

16.4 lbs

**INTERPRETED BY**

Eric Lindquist, DMV  
DABVP, Cert. IVUSS

**IMAGING PERFORMED BY**

Shari Reffi, CVT

**HOSPITAL NAME**

Byram AH

**REFERRING VET**

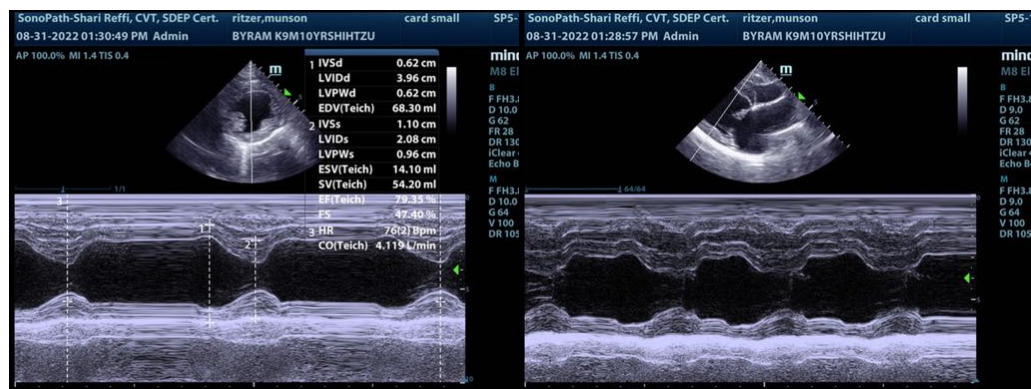
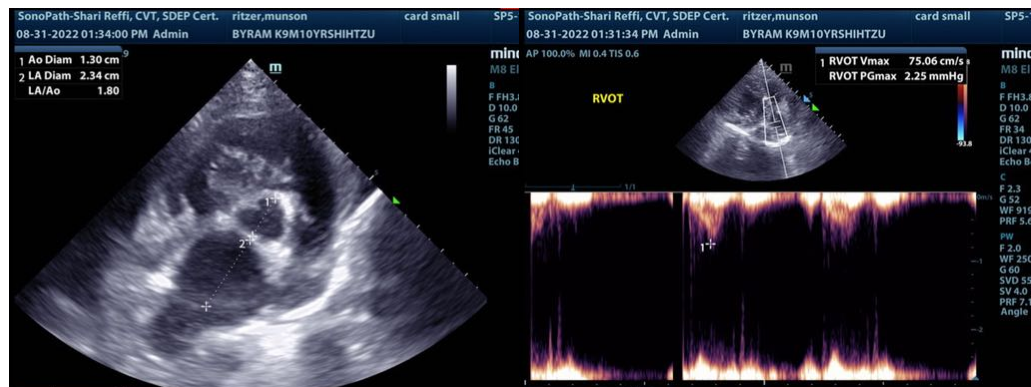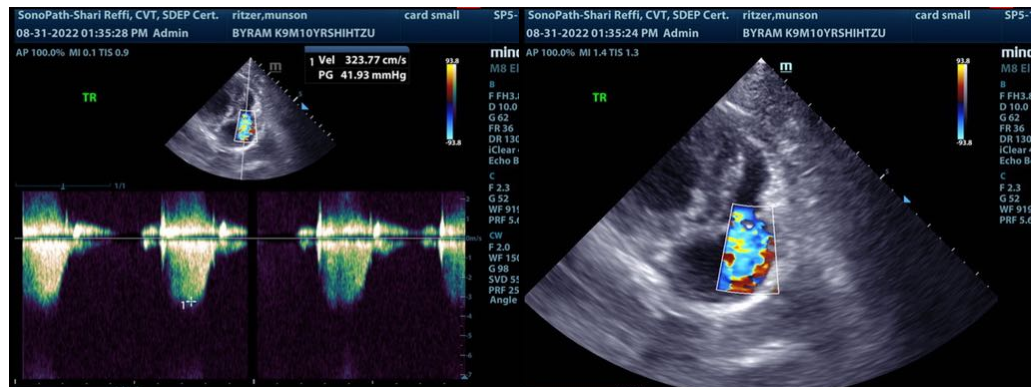
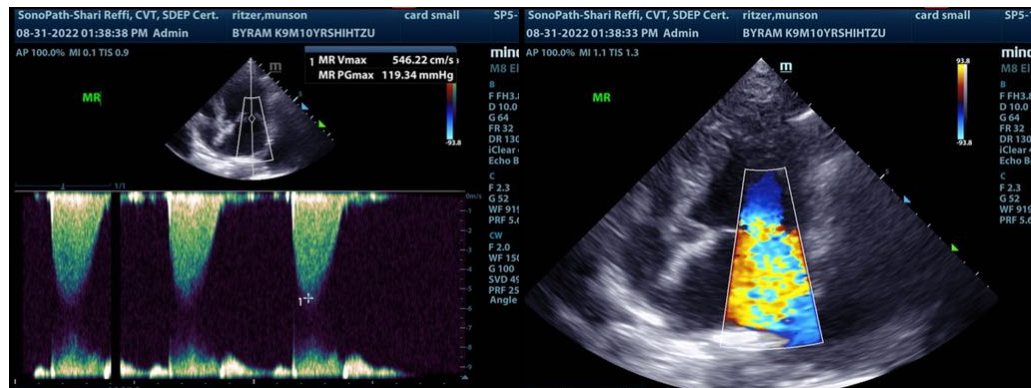
Dr. Abdul-Chani

**INVOICE**

32668

**DATE**

8/31/22





**PATIENT**

Munson Ritzer

**The information and recommendations provided are based on the images presented by the referring veterinarian/sonographer. No evaluation can be communicated regarding pathology that was not visible in the image/video clips provided.**

**SPECIES**

Canine

Thank you for this referral. If the clinical or image interpretation does not parallel your findings or if I can be of any further assistance please contact me.

**BREED**

Shih Tzu

**Eric Lindquist**, DMV, DABVP, Cert. IVUSS, CEO of SonoPath.com  
Info@SonoPath.com

**SEX**

Male

**AGE**

10 years

**WEIGHT**

16.4 lbs

**INTERPRETED BY**

Eric Lindquist, DMV  
DABVP, Cert. IVUSS

**IMAGING  
PERFORMED BY**

Shari Reffi, CVT

**HOSPITAL NAME**

Byram AH

**REFERRING VET**

Dr. Abdul-Chani

**INVOICE**

32668

**DATE**

8/31/22