



PATIENT

Bruno Severson

PRESENTING CLINICAL SIGNS

History: Chronic diarrhea; history of dietary indiscretion; concern for gastric foreign body. On IVFs (LRS) and metronidazole.

Abnormal PE/Chem/CBC/UA Results: CBC/Chem: WNL.

SPECIES

Canine

ULTRASONOGRAPHIC EXAMINATION OF THE ABDOMEN

Urinary System

The **urinary bladder**, trigone, and pelvic urethra presented normal thicknesses and normal tone. The ureters were not visible which is normal. No uroliths or sediment were visualized and anechoic urine was present. No evidence of inflammatory or neoplastic changes was noted. Ureteral papillae were normal.

BREED

Great Pyrenees Mix

SEX

Intact male

The residual prostate was uniform and measured 2.0 cm. The testicles were imaged and found to be uniform. The right testicle measured 3.34 cm.

AGE

5 months

The **kidneys** revealed normal size and structure, corticomedullary definition and ratio for this age. The cortices presented largely uniform texture with normal echogenic relationship to liver and spleen. Medullary structure differed distinctly from the cortex and no evidence of pelvic dilation was present. The capsules were acceptably uniform without significant irregularities. The right kidney measured 4.97 cm.

WEIGHT

58.5 lbs

Adrenal Glands

The right **adrenal gland** was flattened and isoechoic measuring 1.92 x 0.36 cm at the caudal pole and 0.34 cm at the cranial pole. The left adrenal gland measured 1.92 x 0.25 cm at the caudal pole and 0.3 cm at the cranial pole.

INTERPRETED BY

Eric Lindquist, DMV,
DABVP, Cert. IVUSS,
CEO of SonoPath.com

Spleen

The **spleen** in this patient was mildly enlarged with uniform parenchyma and was folded upon itself cranially. This is a positional variant and is not pathological. There was no evidence of significant disease.

IMAGING PERFORMED BY

Kelly Vazquez, CVT

HOSPITAL NAME

Rockaway AH

Liver

The **liver** images submitted revealed subjectively normal liver size, contour, and structure. Parenchymal echogenicity was naturally coarse and hypoechoic to the spleen. Vascular and biliary tracts were of normal volume with no evidence of congestion. The gallbladder presented acceptably thin walls with primarily anechoic content. The cystic and common bile ducts were normal. No pathological hepatic lymphadenopathy was evident. No overt structural evidence of inflammatory, infiltrative or regenerative pathology was evident.

REFERRING VET

Dr. Maniar

INVOICE

32649

Gastrointestinal

DATE

8/30/22

Examination of the **gastrointestinal tract** revealed a stomach and intestine free of stasis, of normal wall thickness, acceptable curvilinear mural detail, and peristaltic activity. Small and large intestine



PATIENT

Bruno Severson

demonstrated normal luminal chyme and stool consistency respectively. Soft stool was noted in the colon. No obstructive or overt infiltrative disease was noted. No associated abnormal lymphatic activity was noted.

SPECIES

Canine

Pancreas

The base and limbs of the **pancreas** were observed to be largely isoechoic to surrounding omental fat. Pancreatic duct and capsular contour were acceptably normal and parenchyma respected normal curvilinear patterns. No overt evidence of active inflammatory or neoplastic disease was noted.

BREED

Great Pyrenees Mix

ULTRASONOGRAPHIC FINDINGS

SEX

Intact male

Structurally normal abdomen with flattened adrenal glands.

AGE

5 months

INTERPRETATION OF THE FINDINGS & FURTHER RECOMMENDATIONS

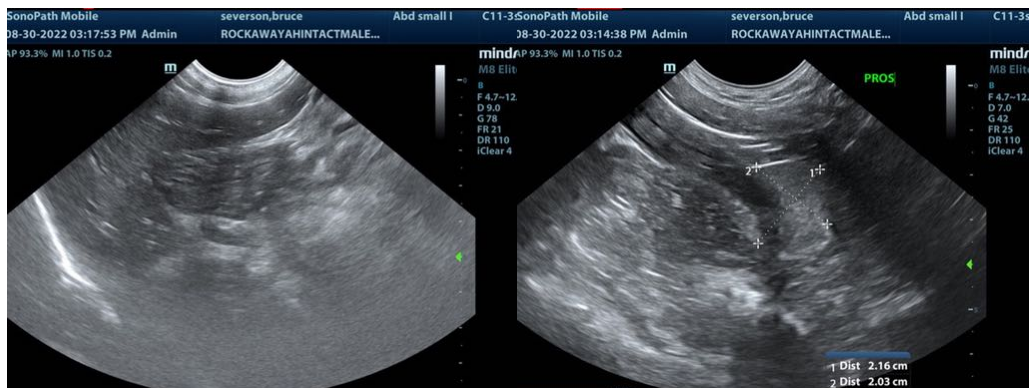
Screening for Addison's is warranted with baseline cortisol or ACTH stimulation. There was no other evidence of pathology. Dietary indiscretion, food intolerance, structurally significant inflammatory bowel or occult parasitism and occult Addison's are all potentials.

WEIGHT

58.5 lbs

INTERPRETED BY

Eric Lindquist, DMV,
DABVP, Cert. IVUSS,
CEO of SonoPath.com

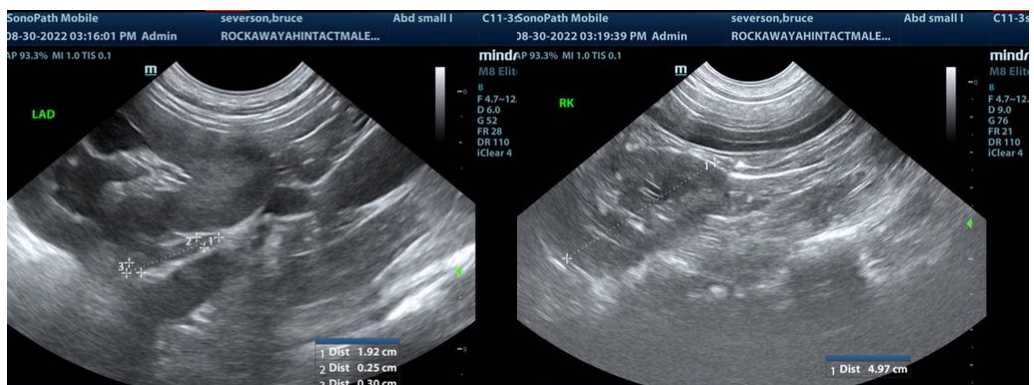


IMAGING PERFORMED BY

Kelly Vazquez, CVT

HOSPITAL NAME

Rockaway AH



REFERRING VET

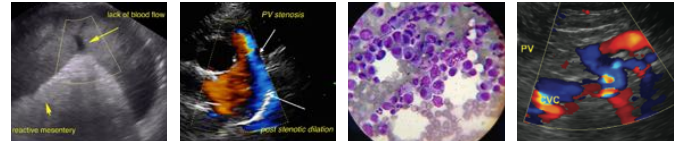
Dr. Maniar

INVOICE

32649

DATE

8/30/22



PATIENT

Bruno Severson

SPECIES

Canine

BREED

Great Pyrenees Mix

SEX

Intact male

AGE

5 months

WEIGHT

58.5 lbs

INTERPRETED BY

Eric Lindquist, DMV,
DABVP, Cert. IVUSS,
CEO of SonoPath.com

**IMAGING
PERFORMED BY**

Kelly Vazquez, CVT

HOSPITAL NAME

Rockaway AH

REFERRING VET

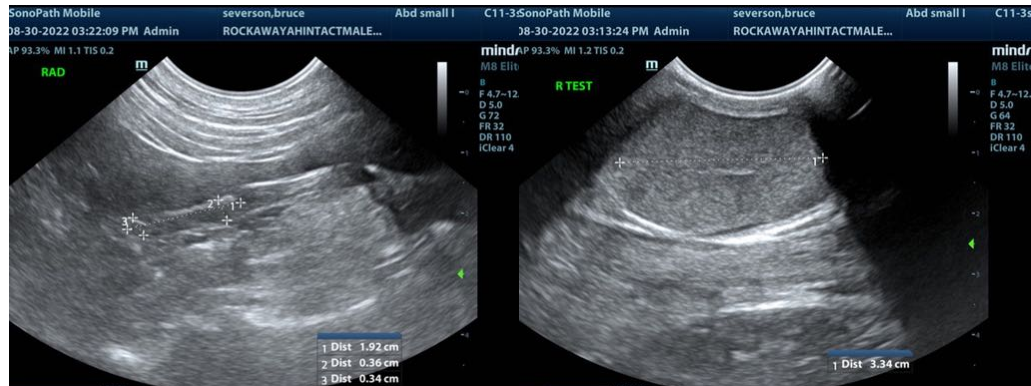
Dr. Maniar

INVOICE

32649

DATE

8/30/22



The information and recommendations provided are based on the images presented by the referring veterinarian/sonographer. No evaluation can be communicated regarding pathology that was not visible in the image/video clips provided.

Thank you for this referral. If the clinical or image interpretation does not parallel your findings or if I can be of any further assistance please contact me.

Eric Lindquist, DMV, DABVP, Cert. IVUSS, CEO of SonoPath.com

Info@SonoPath.com