

PATIENT

Sonny Maresca

PRESENTING CLINICAL SIGNS

History: Increase in heart murmur III-IV/VI vs II/VI in December 2022. No current meds.
Abnormal PE/Chem/CBC/UA Results: WNL 2022

SPECIES

Canine

ULTRASONOGRAPHIC EXAMINATION OF THE HEART

BREED

Maltese Mix

SEX

Neutered male

AGE

12 years

WEIGHT

9.5 lbs

The echocardiogram in this patient demonstrated enlarged **left atrial** size based on 3 different LA measurement methods. Chamber volumes and echogenicity were normal. The cranial and caudal **mitral** valve leaflets presented vegetative thickening consistent with endocardiosis. Doppler indicated measurable insufficiency. The **left ventricle** presented normal thicknesses with linear contour and was not dilated nor restricted. The **myocardium** presented normal echogenicity without subjective evidence of significant fibrotic or ischemic disease. **Contractility** of the ventricular walls was adequate and in normal range for this patient evidenced by the fractional shortening measurement and subjective evaluation of the different regions of the myocardium. The **left ventricular outflow** tract demonstrated normal laminar flow and subjective structural integrity. The **right atrium** and auricle revealed normal size, structure and content. No evidence of masses was noted or chamber overload. **Tricuspid** valvular assessment demonstrated adequate linear morphology. The **right ventricle** was of normal size (1/3 diameter of LV), chordae structure, myocardial echogenicity and thickness. **Pulmonic** tract assessment revealed normal valve structure, laminar flow, and diameter (approx. 1:1 pa/ao ratio). No visible **pericardial** or free pleura fluid was noted. No echographically detectable evidence of infiltrative disease was visible. The cranial **mediastinum and pericardial regions** were free of masses in the visible window.

INTERPRETED BY

Eric Lindquist, DMV
DABVP, Cert. IVUSS

IMAGING PERFORMED BY

Jessica Miller, RDMS

HOSPITAL NAME

Hillsdale AH

REFERRING VET

Dr. Fischer

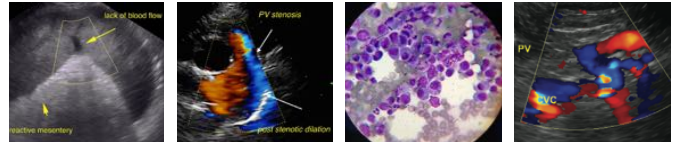
INVOICE

46742

DATE

8/23/23

CANINE CARDIAC PARAMETERS	MR VMAX (m/s)	TR VMAX (m/s)	LA/AO (Boon method)	LA/AO (Heart Base;)	FS (%)	EF (%)	EPSS (cm)
NORMAL PARAMETER	4.5-5.5	<2.7	1.3	Up to 1.6	28-40	40-100	<0.6
PATIENT	6.0		2.09	2.16	45	79	NM
CANINE CARDIAC PARAMETERS	HR (BPM)	AV VMAX (m/s)	PV MAX (m/s)	BODY WEIGHT	LA 2D short axis Base view (cm)	LVIDd Avg; 2D and m- mode short axis (cm)	LVIDs Avg; 2D and m- mode short axis (cm)
NORMAL PARAMETER	50-100	0.7-1.7	0.7-1.6	BELOW	BELOW	BELOW	BELOW
PATIENT	142	0.43	0.86	9.5 lbs	3.2	2.5	



PATIENT

Sonny Maresca

ULTRASONOGRAPHIC FINDINGS

Stage B2 valvular disease.

Complete filling of the left atrium was noted on color flow assessment of the mitral valve.

SPECIES

Canine

INTERPRETATION OF THE FINDINGS & FURTHER RECOMMENDATIONS

Pimobendan would be indicated at 0.3 mg/kg b.i.d. Without consensus ace inhibitor and Spironolactone could be considered in this particular case especially if systolic blood pressure measurements are > 160.

BREED

Maltese Mix

The heart has some volume overload and is working to compensate for the valvular insufficiency. Target respiratory rate is < 20 resp/minute after therapy. After initiating therapy, I recommend recheck on the clinical exam, BUN, Creatinine, USG, Chest radiographs & Blood pressure in 5-7 days. Recheck echo in 1 month. Earlier if clinical decompensation is occurring. I do not recommend anesthesia at this time until stabilization has occurred on the recommended medications. Repeat preanesthetic echo is ideal if anesthesia is eventually necessary.

AGE

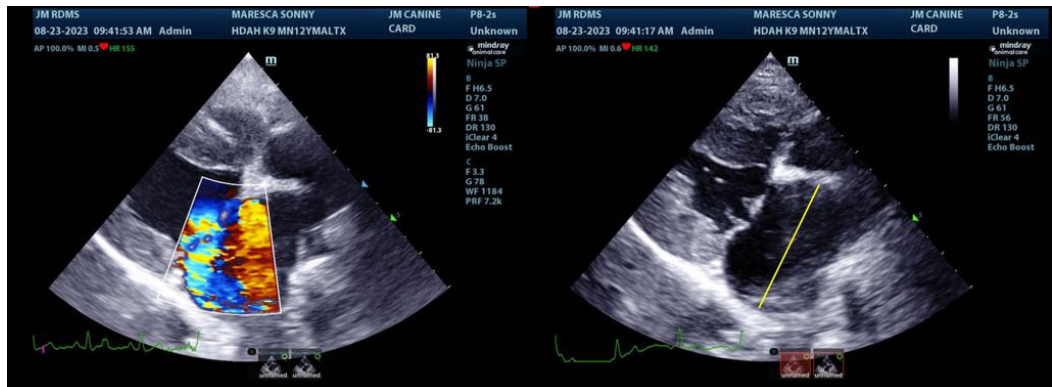
12 years

WEIGHT

9.5 lbs

INTERPRETED BY

Eric Lindquist, DMV
DABVP, Cert. IVUSS



IMAGING PERFORMED BY

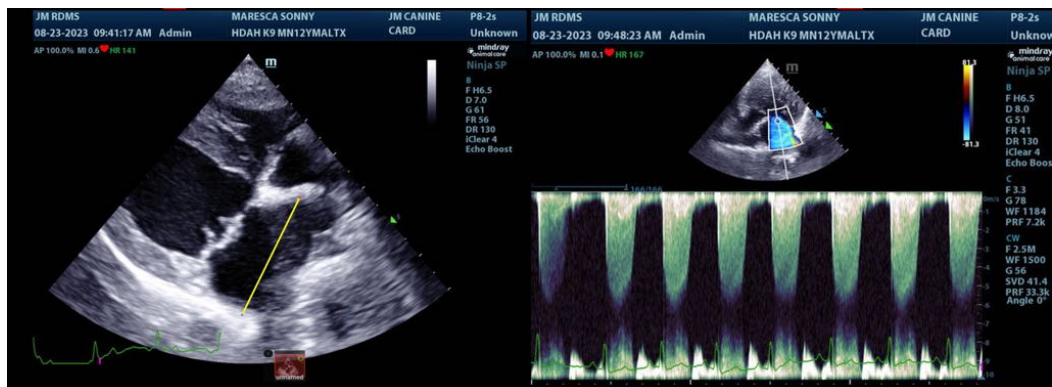
Jessica Miller, RDMS

HOSPITAL NAME

Hillsdale AH

REFERRING VET

Dr. Fischer

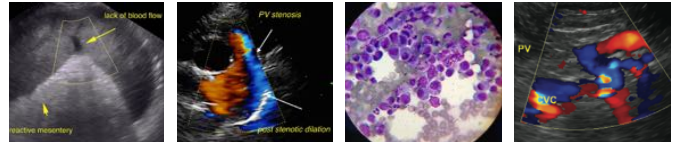


INVOICE

46742

DATE

8/23/23



PATIENT

Sonny Maresca

SPECIES

Canine

BREED

Maltese Mix

SEX

Neutered male

AGE

12 years

WEIGHT

9.5 lbs

INTERPRETED BY

Eric Lindquist, DMV
DABVP, Cert. IVUSS

IMAGING PERFORMED BY

Jessica Miller, RDMS

HOSPITAL NAME

Hillsdale AH

REFERRING VET

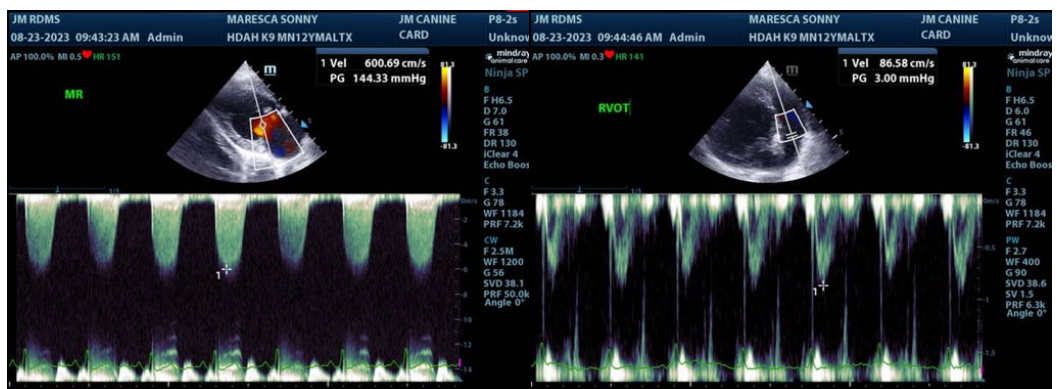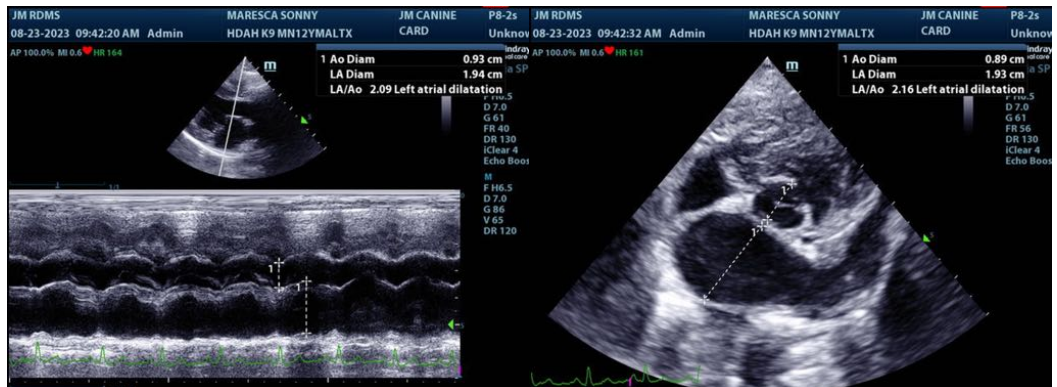
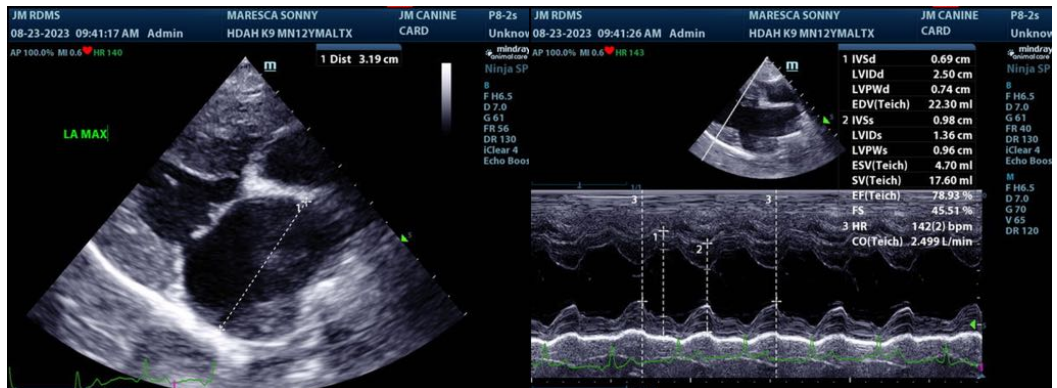
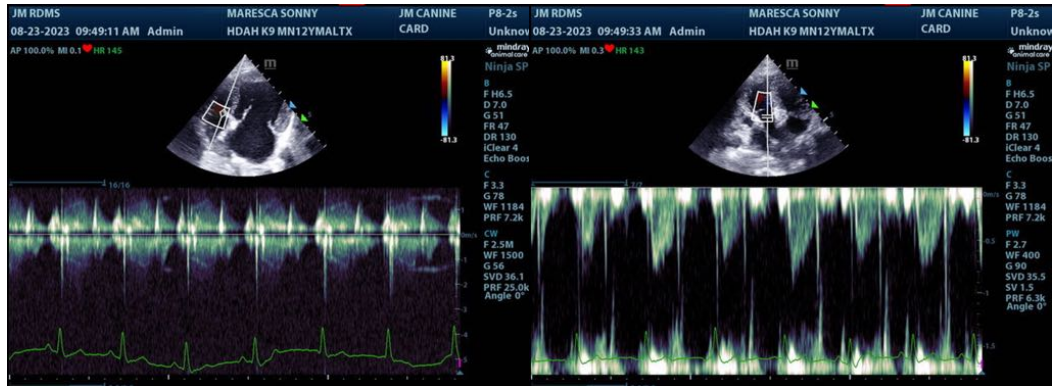
Dr. Fischer

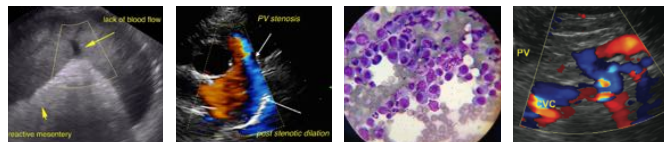
INVOICE

46742

DATE

8/23/23





PATIENT

Sonny Maresca

SPECIES

Canine

BREED

Maltese Mix

SEX

Neutered male

AGE

12 years

WEIGHT

9.5 lbs

INTERPRETED BY

Eric Lindquist, DMV
DABVP, Cert. IVUSS

IMAGING PERFORMED BY

Jessica Miller, RDMS

HOSPITAL NAME

Hillsdale AH

REFERRING VET

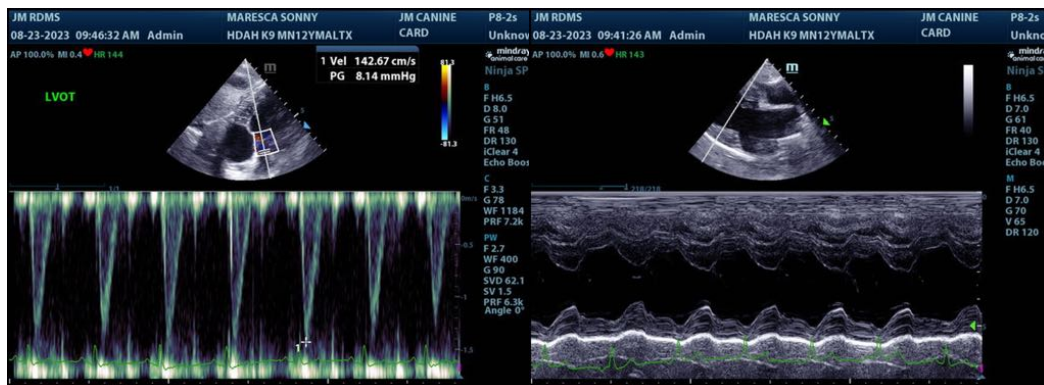
Dr. Fischer

INVOICE

46742

DATE

8/23/23



The information and recommendations provided are based on the images presented by the referring veterinarian/sonographer. No evaluation can be communicated regarding pathology that was not visible in the image/video clips provided.

Thank you for this referral. If the clinical or image interpretation does not parallel your findings or if I can be of any further assistance please contact me.

Eric Lindquist, DMV, DABVP, Cert. IVUSS, CEO of SonoPath.com
Info@SonoPath.com