

PATIENT PRESENTING CLINICAL SIGNS

Einstein Trentacosta

History: coughing, 5/5 murmur, collapsed. On Pimobendan 0.5mg tid, amlodipine sid, cough tabs 0.5 tablet; Plavix and hydrocodone recommended by previous vet, not sure if filled.

SPECIES

Abnormal PE/Chem/CBC/UA Results: ALKP 297 in March 2023, 451 on 8/20/23; ALT 184, d-dimer 3704 (normal 0.3-575); UA: USPG 1.018

Canine

ULTRASONOGRAPHIC EXAMINATION OF THE HEART

BREED

Miniature Schnauzer

The echocardiogram in this patient demonstrated enlarged **left atrial** size based on 3 different LA measurement methods. Chamber volumes and echogenicity were normal. The cranial and caudal **mitral** valve leaflets presented vegetative thickening consistent with endocardiosis. Doppler indicated measurable insufficiency. The **left ventricle** presented normal thicknesses with linear contour and was not dilated nor restricted. The **myocardium** presented normal echogenicity without subjective evidence of significant fibrotic or ischemic disease. **Contractility** of the ventricular walls was adequate and in normal range for this patient evidenced by the fractional shortening measurement and subjective evaluation of the different regions of the myocardium. The **left ventricular outflow** tract demonstrated normal laminar flow and subjective structural integrity. The **right atrium** and auricle revealed normal size, structure and content. No evidence of masses was noted or chamber overload. **Tricuspid** valvular assessment demonstrated adequate linear morphology. The **right ventricle** was of normal size (1/3 diameter of LV), chordae structure, myocardial echogenicity and thickness. **Pulmonic** tract assessment revealed normal valve structure, laminar flow, and diameter (approx. 1:1 pa/ao ratio). No visible **pericardial** or free pleura fluid was noted. No echographically detectable evidence of infiltrative disease was visible. The cranial **mediastinum and pericardial regions** were free of masses in the visible window.

SEX

Neutered male

AGE

15 years

WEIGHT

17.9 lbs

INTERPRETED BY

Eric Lindquist, DMV
DABVP, Cert. IVUSS

IMAGING PERFORMED BY

Diane McFadden

HOSPITAL NAME

Sova

REFERRING VET

Dr. Bott-Wentworth

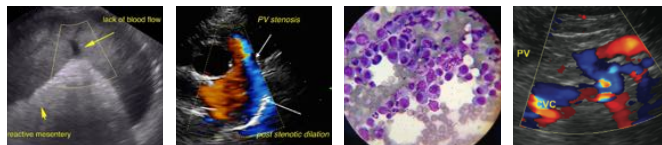
INVOICE

46740

DATE

8/23/23

CANINE CARDIAC PARAMETERS	MR VMAX (m/s)	TR VMAX (m/s)	LA/AO (Boon method)	LA/AO (Heart Base:)	FS (%)	EF (%)	EPSS (cm)
NORMAL PARAMETER	4.5-5.5	<2.7	1.3	Up to 1.6	28-40	40-100	<0.6
PATIENT	5.44	3.6	1.4	2.2	39	71	0.1
CANINE CARDIAC PARAMETERS	HR (BPM)	AV VMAX (m/s)	PV MAX (m/s)	BODY WEIGHT	LA 2D short axis Base view (cm)	LVIDd Avg; 2D and m- mode short axis (cm)	LVIDs Avg; 2D and m- mode short axis (cm)
NORMAL PARAMETER	50-100	0.7-1.7	0.7-1.6	BELOW	BELOW	BELOW	BELOW
PATIENT	143	1.12		17.9 lbs	4.07	3.25	



PATIENT

Einstein Trentacosta

SPECIES

Canine

BREED

Miniature Schnauzer

SEX

Neutered male

AGE

15 years

WEIGHT

17.9 lbs

INTERPRETED BY

Eric Lindquist, DMV
DABVP, Cert. IVUSS

**IMAGING
PERFORMED BY**

Diane McFadden

HOSPITAL NAME

Sova

REFERRING VET

Dr. Bott-Wentworth

INVOICE

46740

DATE

8/23/23

ULTRASONOGRAPHIC EXAMINATION OF THE ABDOMEN

Urinary System

The **urinary bladder**, trigone, and pelvic urethra presented normal thicknesses and normal tone. The ureters were not visible which is normal. No uroliths or sediment were visualized and anechoic urine was present. No evidence of inflammatory or neoplastic changes was noted. Ureteral papillae were normal.

The **kidneys** revealed largely normal size and structure, corticomedullary definition and ratio (cortex 1/3 of medulla) were essentially maintained with some age-related loss of curvilinear patterns regarding the capsule and C/M junction. The cortices presented largely uniform texture with some increased echogenicity expected for his age patient. Medullary structure differed distinctly from that of the cortex and no evidence of pelvic dilation was present. The right kidney measured 4.5 cm. The left kidney measured 4.6 cm.

Adrenal Glands

The **adrenal glands** appeared slightly enlarged and swollen. No evidence of focal capsular expansion or invasion into the phrenic veins was noted. No overt suspicion of neoplasia was noted. This is considered likely a hyperplastic change associated with stress or adrenal endocrinopathy (PDH). If isosthenuria is persistently present and the patient morphologically suggests Cushing's disease then ACTH testing would be indicated. The right adrenal gland measured 2.39 x 1.39 cm at the cranial pole and 0.59 cm at the caudal pole. The left adrenal gland measured 1.7 x 0.58 cm at the cranial pole and 0.45 cm at the caudal pole.

Spleen

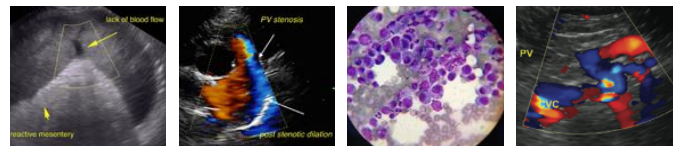
The **spleen** was largely smooth with subtle heterogeneous parenchymal changes while maintaining normal echogenic relationship to the liver and kidney. These changes are consistent with normal age-related alteration. Multi-focal, hyperechoic lipid plaques were noted in the spleen. The capsule was smooth without noticeable impingement from within the spleen or from pathology in the adjacent abdomen. The splenic vasculature demonstrated normal volume without signs of congestion or significant contraction. No evidence of active acute or chronic inflammatory, neoplastic, or infarctual changes was noted.

Liver

The **liver** images submitted revealed subjectively normal liver size, contour, and structure. Parenchymal echogenicity was naturally coarse and hypoechoic to the spleen. Slight hepatic vein dilation was noted in this patient. The gallbladder presented acceptably thin walls with primarily anechoic content. The cystic and common bile ducts were normal. No pathological hepatic lymphadenopathy was evident. No overt structural evidence of inflammatory, infiltrative or regenerative pathology was evident.

Gastrointestinal

Examination of the **gastrointestinal tract** revealed a stomach and intestine free of stasis, of normal wall thickness, acceptable curvilinear mural detail, and peristaltic activity. Small and large intestine



PATIENT

Einstein Trentacosta

demonstrated normal luminal chyme and stool consistency respectively. No obstructive or overt infiltrative disease was noted. No associated abnormal lymphatic activity was noted.

SPECIES

Pancreas

Canine

The base and limbs of the **pancreas** were observed to be largely isoechoic to surrounding omental fat. Pancreatic duct and capsular contour were acceptably normal and parenchyma respected normal curvilinear patterns. No overt evidence of active inflammatory or neoplastic disease was noted.

BREED

Miniature Schnauzer

ULTRASONOGRAPHIC FINDINGS

SEX

Neutered male

Mitral and tricuspid insufficiency with mild left atrial enlargement with mild pulmonary hypertension.

Slightly enlarged adrenal glands.

Hyperechoic lipid plaques in spleen.

AGE

15 years

INTERPRETATION OF THE FINDINGS & FURTHER RECOMMENDATIONS

WEIGHT

17.9 lbs

From cardiac standpoint I recommend adding ace inhibitor therapy at 0.5 mg/kg b.i.d. If the patient appears Cushingoid and urine specific gravity is persistently less than 1.020 then work-up for Cushing's/PDH is indicated.

INTERPRETED BY

Eric Lindquist, DMV DABVP, Cert. IVUSS

The heart has some volume overload and is working to compensate for the valvular insufficiency. Target respiratory rate is < 20 resp/minute after therapy. After initiating therapy, I recommend recheck on the clinical exam, BUN, Creatinine, USG, Chest radiographs & Blood pressure in 5-7 days. Recheck echo in 1 month. Earlier if clinical decompensation is occurring. I do not recommend anesthesia at this time until stabilization has occurred on the recommended medications. Repeat preanesthetic echo is ideal if anesthesia is eventually necessary

IMAGING PERFORMED BY

Diane McFadden

HOSPITAL NAME

Sova

REFERRING VET

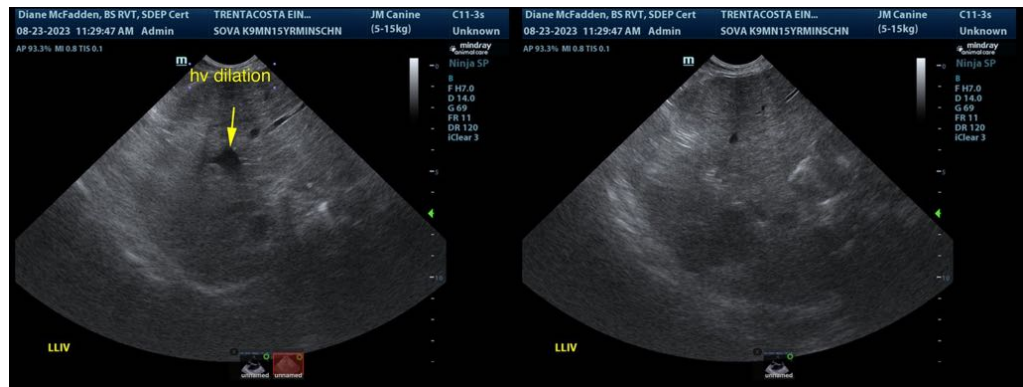
Dr. Bott-Wentworth

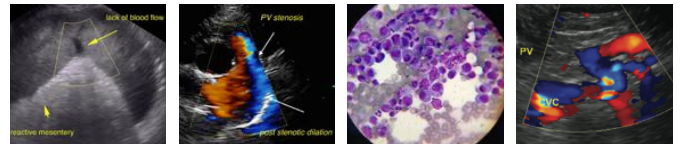
INVOICE

46740

DATE

8/23/23





PATIENT

Einstein Trentacosta

SPECIES

Canine

BREED

Miniature Schnauzer

SEX

Neutered male

AGE

15 years

WEIGHT

17.9 lbs

INTERPRETED BY

Eric Lindquist, DMV
DABVP, Cert. IVUS

IMAGING PERFORMED BY

Diane McFadden

HOSPITAL NAME

Sova

REFERRING VET

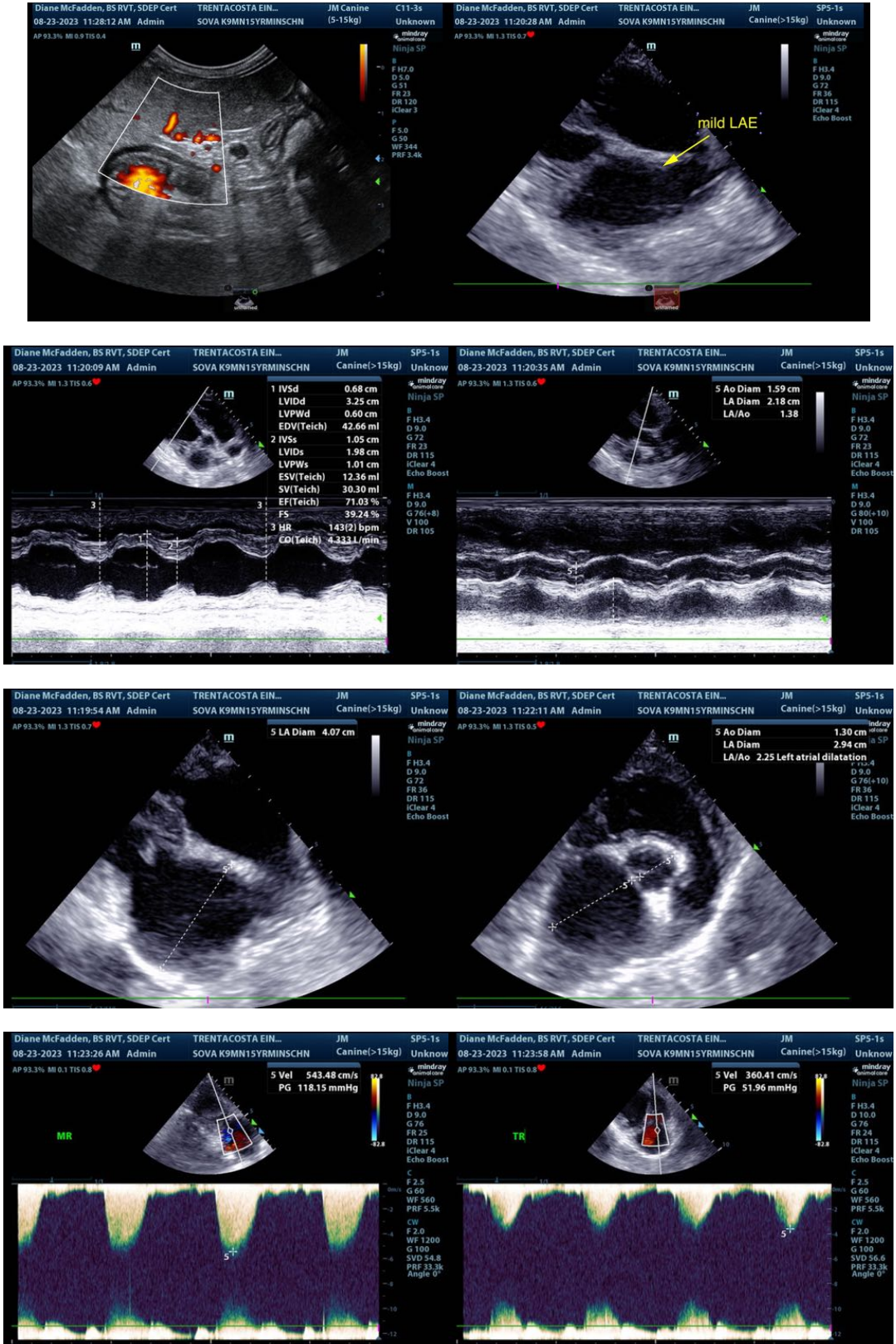
Dr. Bott-Wentworth

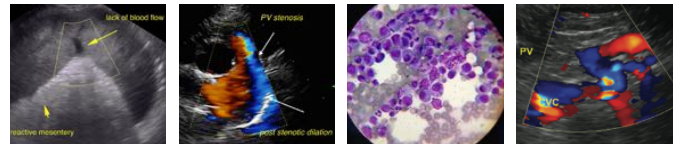
INVOICE

46740

DATE

8/23/23





PATIENT

Einstein Trentacosta

SPECIES

Canine

BREED

Miniature Schnauzer

SEX

Neutered male

AGE

15 years

WEIGHT

17.9 lbs

INTERPRETED BY

Eric Lindquist, DMV
DABVP, Cert. IVUSS

IMAGING PERFORMED BY

Diane McFadden

HOSPITAL NAME

Sova

REFERRING VET

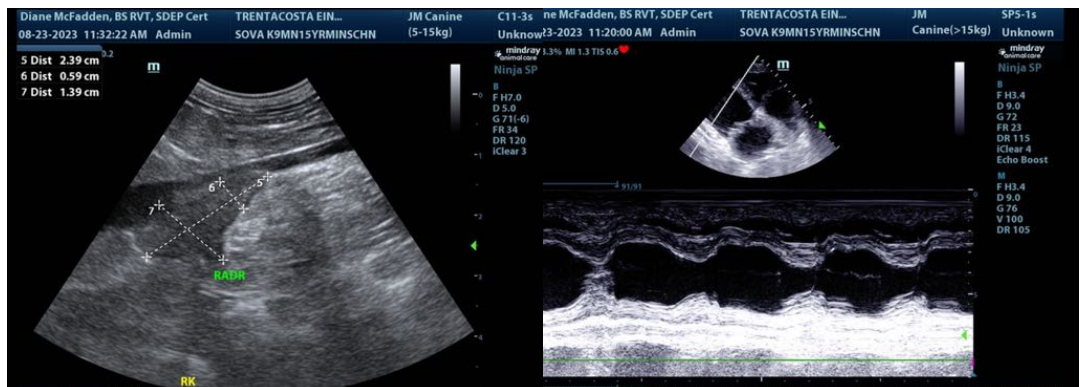
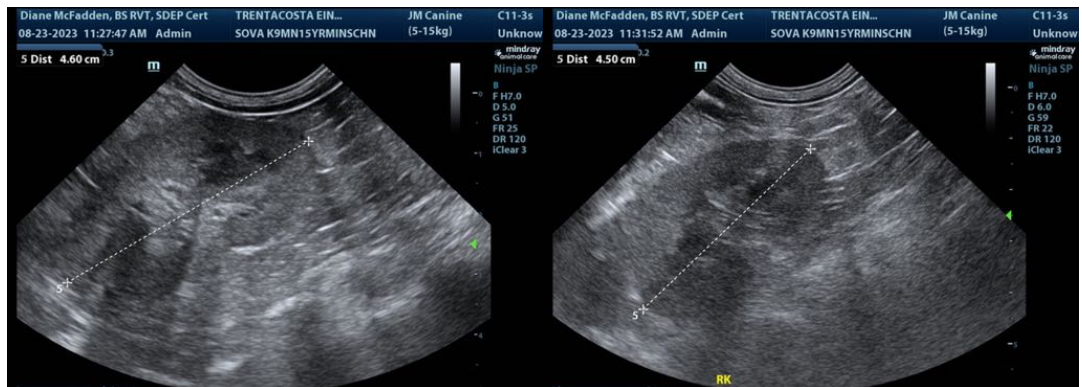
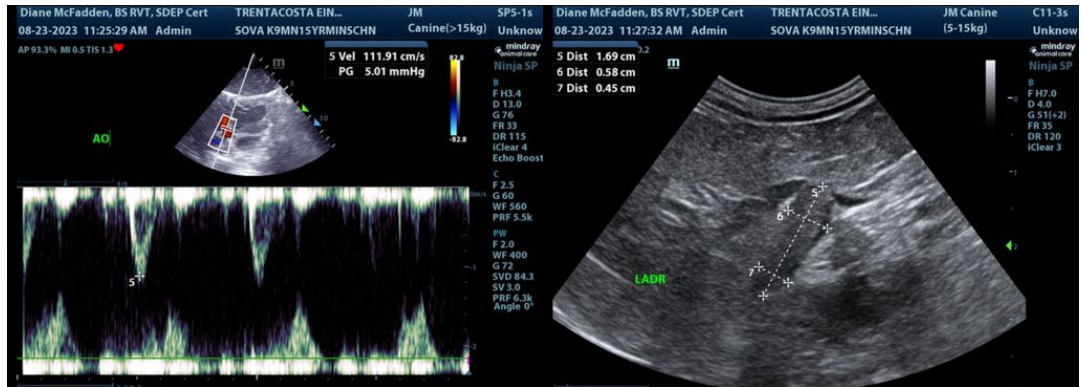
Dr. Bott-Wentworth

INVOICE

46740

DATE

8/23/23



The information and recommendations provided are based on the images presented by the referring veterinarian/sonographer. No evaluation can be communicated regarding pathology that was not visible in the image/video clips provided.

Thank you for this referral. If the clinical or image interpretation does not parallel your findings or if I can be of any further assistance please contact me.

Eric Lindquist, DMV, DABVP, Cert. IVUSS, CEO of SonoPath.com
Info@SonoPath.com