

PATIENT

Archie Gruss

SPECIES

Feline

BREED

Siamese

SEX

Neutered male

AGE

9 years

INTERPRETED BY

Eric Lindquist, DMV
DABVP, Cert. IVUSS

IMAGING PERFORMED BY

Eric Lindquist, DMV
DABVP, Cert. IVUSS

HOSPITAL NAME

Basking Ridge AH

REFERRING VET

Dr. Rotella

INVOICE

46718

DATE

8/23/23

PRESENTING CLINICAL SIGNS

Weight loss, decreased appetite, vomiting 2x/week. History of chronic GI signs.
Prior ultrasound revealed prominent GI and mesenteric lymph nodes.

ULTRASONOGRAPHIC EXAMINATION OF THE ABDOMEN

Urinary System

The **urinary bladder**, trigone, and pelvic urethra presented normal thicknesses and normal tone. The ureters were not visible which is normal. No uroliths or sediment were visualized and anechoic urine was present. No evidence of inflammatory or neoplastic changes was noted. Ureteral papillae were normal.

The **kidneys** revealed largely normal size and structure, corticomedullary definition and ratio (cortex 1/3 of medulla) were essentially maintained with some age-related loss of curvilinear patterns regarding the capsule and C/M junction. The cortices presented largely uniform texture with some increased echogenicity expected for his age patient. Medullary structure differed distinctly from that of the cortex and no evidence of pelvic dilation was present. The left kidney measured 4.5 cm. The right kidney measured 4.26 cm.

Adrenal Glands

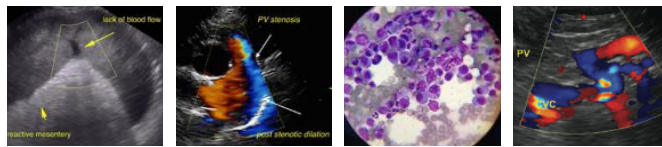
Both **adrenal glands** were visualized and recognized as having normal shape, size, position and echogenicity for this breed. The phrenic vasculature, glandular echogenicity and detail were unremarkable. Capsule, cortex, and medullary definition were normal for this age patient. The left adrenal gland measured 0.34 cm. The right adrenal gland measured 0.48 cm.

Spleen

The **spleen** presented a smooth homogeneous parenchyma hyperechoic to liver and renal cortical parenchyma. The capsule was smooth without noticeable expansion or deviation from within the spleen or adjacent pathology. The splenic vasculature demonstrated normal volume without signs of congestion or thrombosis. No sonographic evidence of acute or chronic inflammatory, neoplastic, or infarctual changes was noted.

Liver

The **liver** images submitted revealed subjectively normal liver size, contour, and structure. Parenchymal echogenicity was naturally coarse and hypoechoic to the spleen. Vascular and biliary tracts were of normal volume with no evidence of congestion. The gallbladder presented acceptably thin walls with primarily anechoic content. The cystic and common bile ducts were normal. No pathological hepatic lymphadenopathy was evident. No overt structural evidence of inflammatory, infiltrative or regenerative pathology was evident.



PATIENT

Gastrointestinal

Archie Gruss

The **gastrointestinal tract** revealed a minimal amount of ingesta in the stomach with mild, thickening throughout the gastrointestinal tract with some early areas of loss of mural detail in the small intestine. There was no pathology was large enough to aspirate. The mesenteric lymph node was reactive and measured 1.5 x 0.75 cm.

SPECIES

Feline

Pancreas

BREED

Siamese

The base and limbs of the **pancreas** were observed to be largely isoechoic to surrounding omental fat. Some parenchymal remodeling, however, with mild deviation from curvilinear normalcy was observed. Pancreatic duct and capsular irregularities were present consistent with age related changes. If pain upon imaging (+ Murphy sign) was present or if the patient is focally painful in subxiphoid palpation then low-grade smoldering chronic pancreatitis should be suspected.

SEX

Neutered male

ULTRASONOGRAPHIC FINDINGS

AGE

9 years

Diffuse intestinal thickening with minor, mesenteric reactive lymph node.

INTERPRETED BY

Eric Lindquist, DMV
DABVP, Cert. IVUSS

INTERPRETATION OF THE FINDINGS & FURTHER RECOMMENDATIONS

Full thickness biopsies of the lymph node biopsies would be ideal to assess for inflammatory bowel versus emerging lymphoma. Dry form FIP is a mild potential. Prognosis is guarded. If full thickness biopsies are not an option the following protocol may prove effective.

IMAGING PERFORMED BY

Eric Lindquist, DMV
DABVP, Cert. IVUSS

Part or all of this protocol may be considered based on your clinical impression of the patient:

HOSPITAL NAME

Basking Ridge AH

Recommend pain management when anorexic with **Buprenorphine** (0.01-0.02 mg/kg IM or SC), clinical trial of **Zithromax** (50 mg sid/cat x 10 days, 3 weeks if bartonella +), **Prednisolone** (0.5-2 mg/kg tapering over 1 week to minimal effective dose), and **B12 injections** if weight loss (Cyanobalamine 250 mcg sub-q once-weekly x six weeks, then every other week for six weeks and then once-monthly, long-term if necessary), **novel-protein or hydrolyzed diet** (*Hydrolyzed diets have been shown to be more effective in dietary intolerance case management compared to hypoallergenic diets*) or the **magical Purina DM** (changing protein source is crucial and may need rotation every 6 months if clinical signs recur) Diet trials is a whatever works phenomenon. If vomiting becomes a persistent issue then endoscopy would be warranted and/or recheck sonogram to assess more emerging disease. One diet does not work for all patients so different trials may be necessary or protein source rotation every 6 months as new sensitivities develop.

REFERRING VET

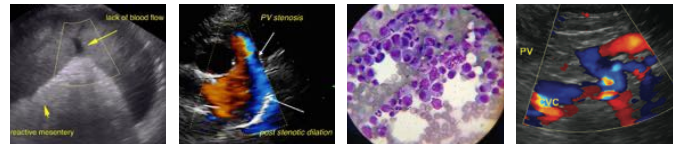
Dr. Rotella

INVOICE

46718

DATE

8/23/23



PATIENT

Archie Gruss

SPECIES

Feline

BREED

Siamese

SEX

Neutered male

AGE

9 years

INTERPRETED BY

Eric Lindquist, DMV, DABVP, Cert. IVUSS

IMAGING PERFORMED BY

Eric Lindquist, DMV, DABVP, Cert. IVUSS

HOSPITAL NAME

Basking Ridge AH

REFERRING VET

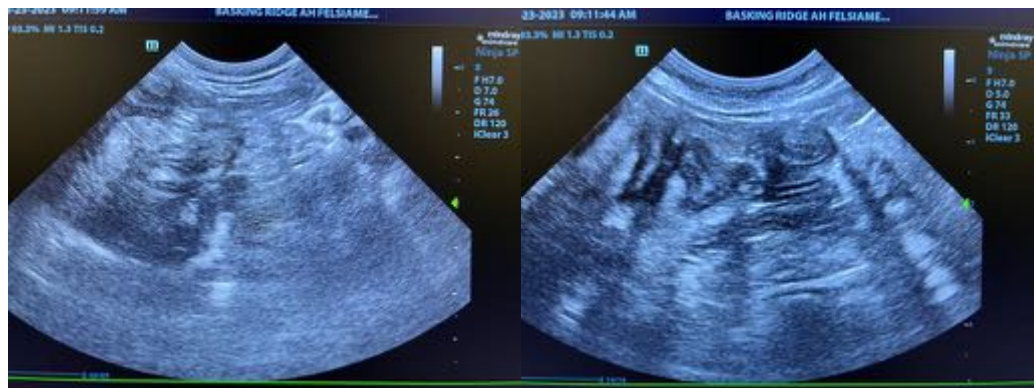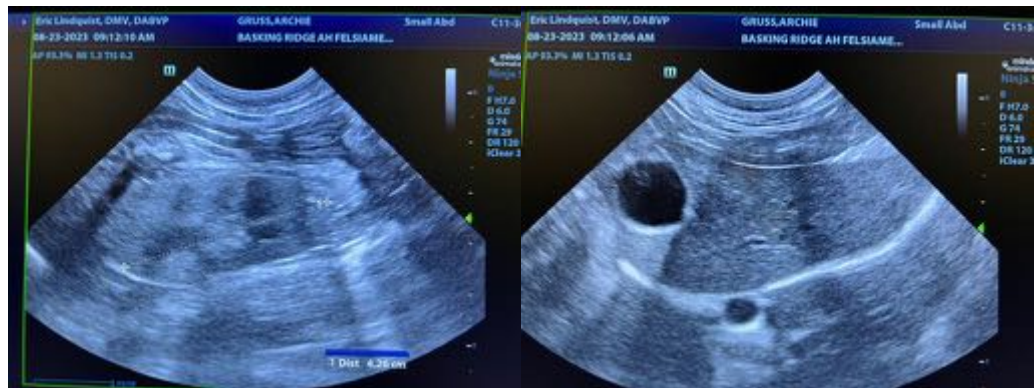
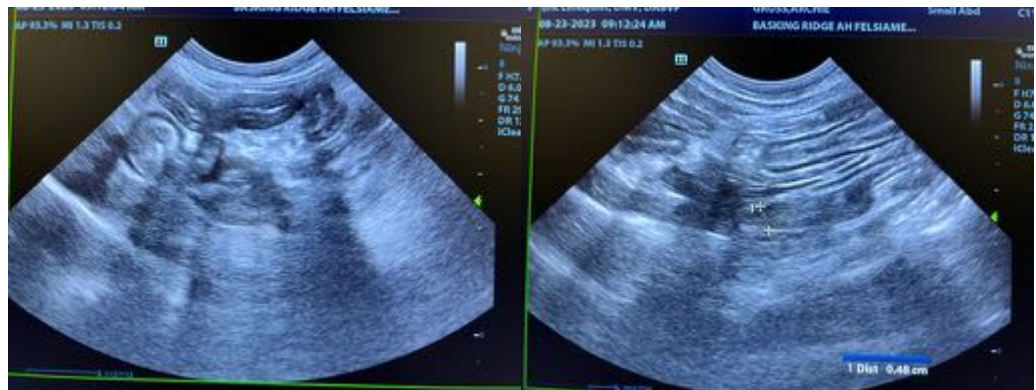
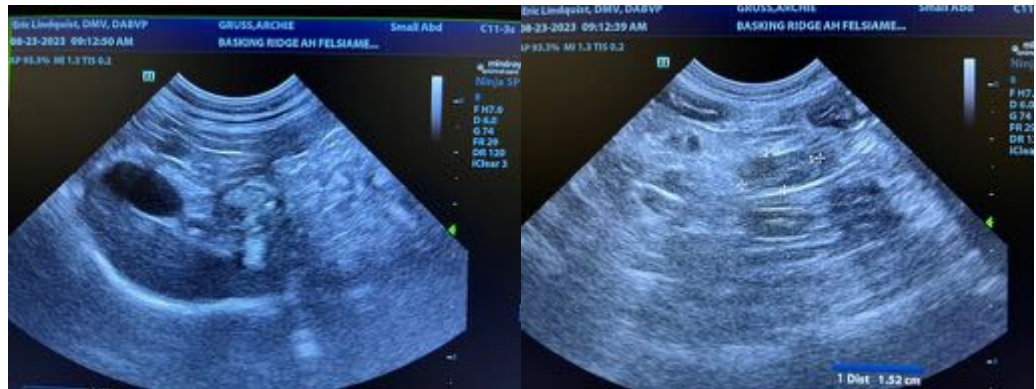
Dr. Rotella

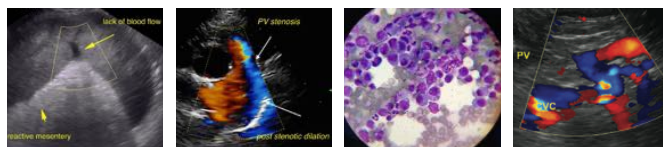
INVOICE

46718

DATE

8/23/23





PATIENT

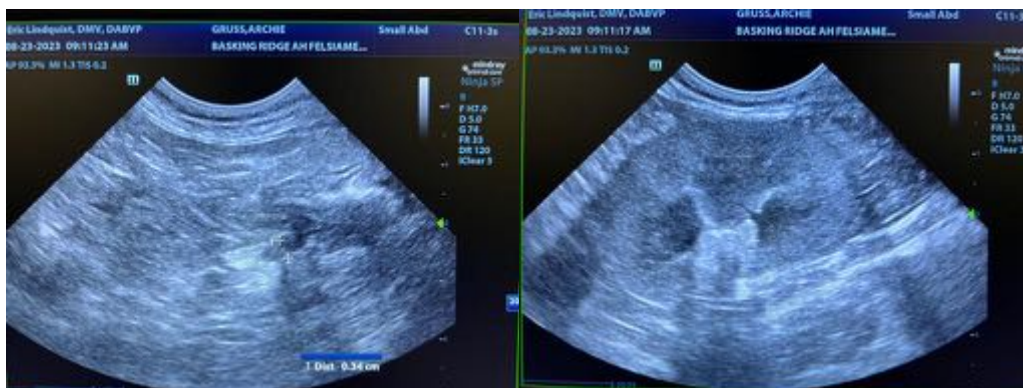
Archie Gruss

SPECIES

Feline

BREED

Siamese



SEX

Neutered male

The information and recommendations provided are based on the images presented by the referring veterinarian/sonographer. No evaluation can be communicated regarding pathology that was not visible in the image/video clips provided.

AGE

9 years

Thank you for this referral. If the clinical or image interpretation does not parallel your findings or if I can be of any further assistance please contact me.

INTERPRETED BY

Eric Lindquist, DMV
DABVP, Cert. IVUSS

Eric Lindquist, DMV, DABVP, Cert. IVUSS, CEO of SonoPath.com
Info@SonoPath.com

IMAGING PERFORMED BY

Eric Lindquist, DMV
DABVP, Cert. IVUSS

HOSPITAL NAME

Basking Ridge AH

REFERRING VET

Dr. Rotella

INVOICE

46718

DATE

8/23/23