

PATIENT

Heidi Frommeyer

SPECIES

Feline

BREED

Domestic Shorthair

SEX

Spayed female

AGE

14 years

WEIGHT

8.12 lbs

PRESENTING CLINICAL SIGNS

History: Persistent mild liver enzyme elevations + continued weight loss. Hx low grade HM 1/6 - tricuspid disease. Hx GI disease suspected on previous US 2/21/22 IBD vs Pancreatitis. Hx mod dental disease. Occasional vomiting.

Abnormal PE/Chem/CBC/UA Results: ALT 164, ALP 64, Mono 1079, proBNP 24 UA: 1+ protein, pH 6.5 SG: 1.048

ULTRASONOGRAPHIC EXAMINATION OF THE HEART

The echocardiogram in this patient demonstrated normal **left atrial** size based on 3 separate LA measurements. The cranial and caudal **mitral** valve leaflets presented normal linear structure and kinetics. The **left ventricle** presented normal thicknesses with linear contour and was not dilated nor restricted. The **myocardium** presented normal echogenicity without subjective evidence of significant fibrotic or ischemic disease. **Contractility** of the ventricular walls was adequate and in normal range for this patient evidenced by the fractional shortening measurement and subjective evaluation of the different regions and angles of the myocardium. The **left ventricular outflow** tract demonstrated normal laminar flow and subjective structural integrity. The **right atrium** and auricle revealed normal size, structure and content. No evidence of masses was noted or chamber overload. Trivial **tricuspid** insufficiency was noted, similar to the prior sonogram. The **right ventricle** was of normal size (1/3 diameter of LV), chordae structure, myocardial echogenicity and thickness. **Pulmonic** tract assessment revealed normal valve structure, laminar flow, and diameter (approx. 1:1 pa/ao ratio). No visible **pericardial** or free pleura fluid was noted or extra cardiac pathology in the visible planes. The cranial **mediastinum and pericardial regions** were free of masses in the visible window.

INTERPRETED BY

Eric Lindquist, DMV
DABVP, Cert. IVUSS

IMAGING PERFORMED BY

Jessica Miller, RDMS

HOSPITAL NAME

Long Valley AH

REFERRING VET

Dr. Welch

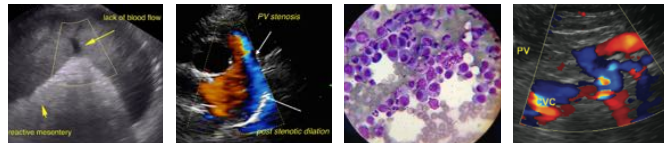
INVOICE

46691

DATE

8/21/23

FELINE CARDIAC PARAMETERS	BODY WEIGHT	HR (BPM)	IVSd (cm)	LVIDd (cm)	LVWd (cm)	FS (%)	EF (%)
NORMAL PARAMETER	-----	150-240	0.3-0.6	1.0-2.1	0.25-0.6	35-67	80-100
PATIENT	8.12 lbs	238	0.37	1.14	0.3	72	97
FELINE CARDIAC PARAMETERS	LA/AO (Boon)	LA/AO HEART BASE (Sisson)	LA 2D 4-chamber long axis AS to FW (Sisson) (cm)	LVOT VEL. (m/s)	RVOT VEL. (m/s)	IVRT (m)	
NORMAL PARAMETER	<1.5	0.88-1.79	0.7-1.7	<1.6	<1.3	40-60	
PATIENT	1.16	1.3	1.2 max	1.44	1.18	NM	
Adapted from June Boon, Veterinary Echocardiography, 1998 Sisson D et al. JVIM 1991; 5: 232, Jacobs et al. Am J Vet Res 1985; 46:1705							



PATIENT

ULTRASONOGRAPHIC EXAMINATION OF THE ABDOMEN

Heidi Frommeyer

Urinary System

SPECIES

The **urinary bladder**, trigone, and pelvic urethra presented normal thicknesses and normal tone. The pelvic urethra was imaged 2.0 cm beyond the cystourethral junction and appeared normal. The ureters were not visible which is normal. No uroliths or sediment were visualized and anechoic urine was present. No evidence of inflammatory or neoplastic changes was noted. Ureteral papillae were normal.

Feline

BREED

Domestic Shorthair

SEX

Spayed female

The **kidneys** revealed largely normal size and structure, corticomedullary definition and ratio (cortex 1/3 of medulla) were essentially maintained with some age-related loss of curvilinear patterns regarding the capsule and C/M junction. The cortices presented largely uniform texture with some increased echogenicity expected for his age patient. Medullary structure differed distinctly from that of the cortex and no evidence of pelvic dilation was present. The right kidney measured 3.52 cm. The left kidney measured 3.5 cm with pinpoint mineralization.

AGE

14 years

Adrenal Glands

WEIGHT

8.12 lbs

Both **adrenal glands** were visualized and recognized as having normal shape, size, position and echogenicity for this breed. The phrenic vasculature, glandular echogenicity and detail were unremarkable. Capsule, cortex, and medullary definition were normal for this age patient. The left adrenal gland measured 0.48 cm.

INTERPRETED BY

Spleen

Eric Lindquist, DMV
DABVP, Cert. IVUSS

The **spleen** presented a smooth homogeneous parenchyma hyperechoic to liver and renal cortical parenchyma. The capsule was smooth without noticeable expansion or deviation from within the spleen or adjacent pathology. The splenic vasculature demonstrated normal volume without signs of congestion or thrombosis. No sonographic evidence of acute or chronic inflammatory, neoplastic, or infarctual changes was noted.

IMAGING PERFORMED BY

Jessica Miller, RDMS

HOSPITAL NAME

Long Valley AH

Liver

The **liver** revealed mixed, hypoechoic, mildly disruptive nodule that measured 1.3 x 0.9 cm in the left cranial liver. Multiple nodular changes were noted in the liver. The gallbladder and common bile duct were unremarkable.

REFERRING VET

Dr. Welch

Gastrointestinal

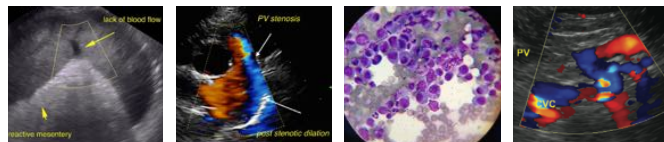
INVOICE

46691

The **gastrointestinal tract** revealed minor variable thickening and echogenic submucosal changes most consistent with low grade end result of chronic GI disease such as IBD and may be related to malassimilation of nutrients if any weight loss is present. No obvious neoplastic patterns were noted and luminal content as unremarkable.

DATE

8/21/23



PATIENT

Pancreas

Heidi Frommeyer

The **pancreas** revealed coarse architecture with heterogenous parenchymal changes with remodeling.

SPECIES

Feline

ULTRASONOGRAPHIC FINDINGS

Normal echocardiogram with minor tricuspid insufficiency, yet not clinically significant.

BREED

Domestic Shorthair

Chronic GI and pancreatic changes with hepatic nodules. Nodular hyperplasia versus round cell neoplasia or carcinoma is all possible.

SEX

Spayed female

INTERPRETATION OF THE FINDINGS & FURTHER RECOMMENDATIONS

FNA of the liver nodule is warranted. Maldigestion panel, three view chest radiographs and full CNS examination is recommended to examine for occult disease that could be responsible for the weight loss. Evaluation for competitive eating environments should also be considered.

AGE

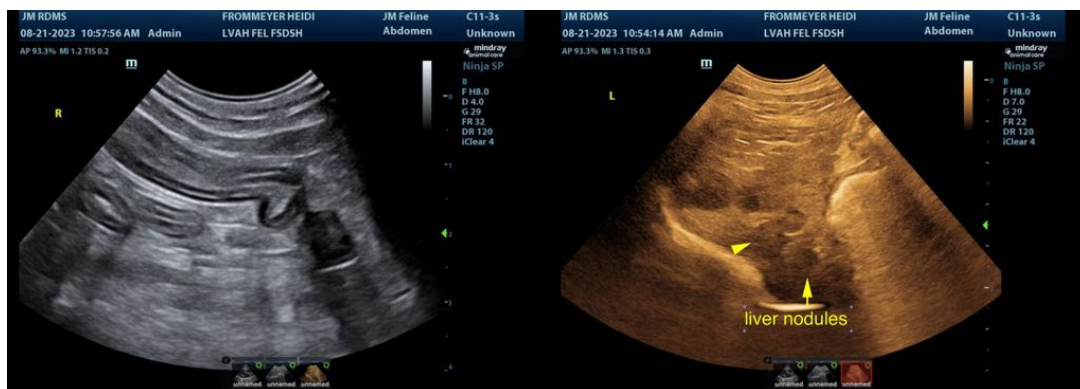14 years

WEIGHT

8.12 lbs

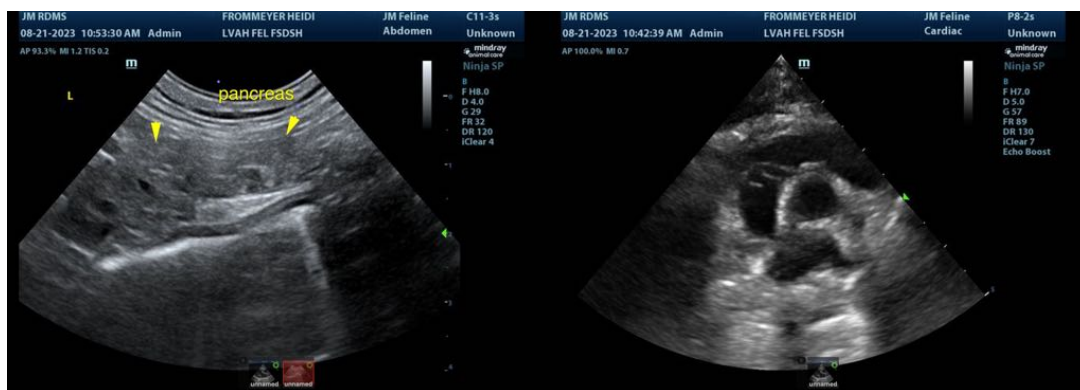INTERPRETED BY

Eric Lindquist, DMV
DABVP, Cert. IVUSS



IMAGING PERFORMED BY

Jessica Miller, RDMS



HOSPITAL NAME

Long Valley AH

REFERRING VET

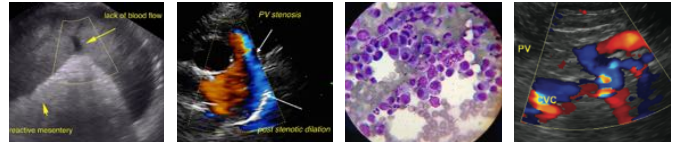
Dr. Welch

INVOICE

46691

DATE

8/21/23



PATIENT

Heidi Frommeyer

SPECIES

Feline

BREED

Domestic Shorthair

SEX

Spayed female

AGE

14 years

WEIGHT

8.12 lbs

INTERPRETED BY

Eric Lindquist, DMV
DABVP, Cert. IVUSS

IMAGING PERFORMED BY

Jessica Miller, RDMS

HOSPITAL NAME

Long Valley AH

REFERRING VET

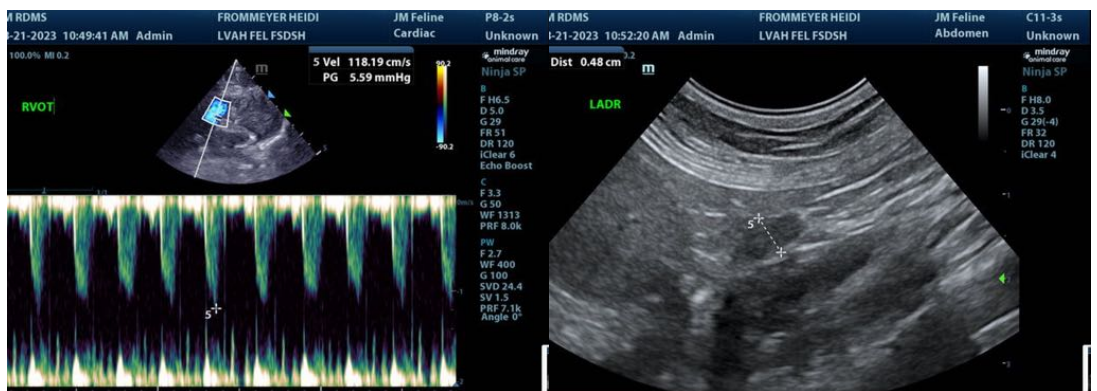
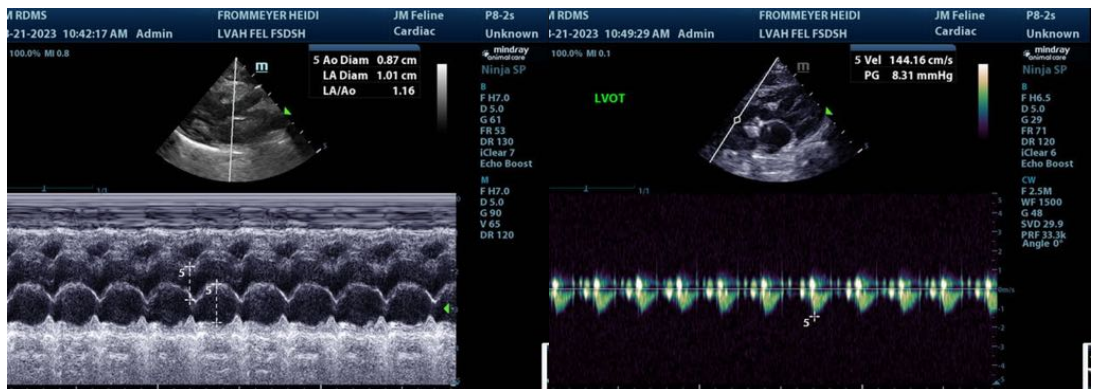
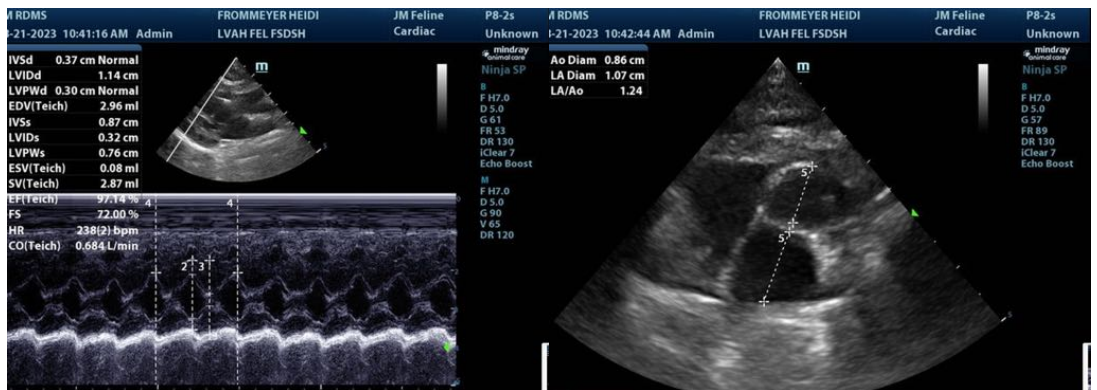
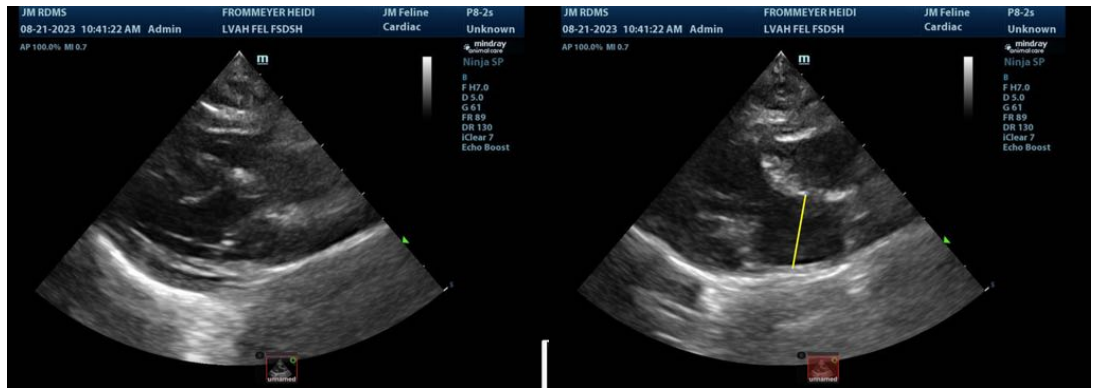Dr. Welch

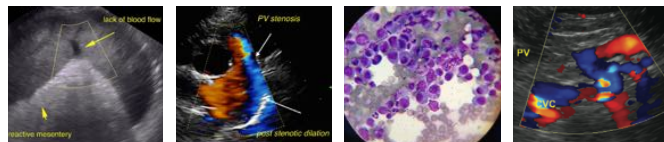
INVOICE

46691

DATE

8/21/23





PATIENT

Heidi Frommeyer

SPECIES

Feline

BREED

Domestic Shorthair

SEX

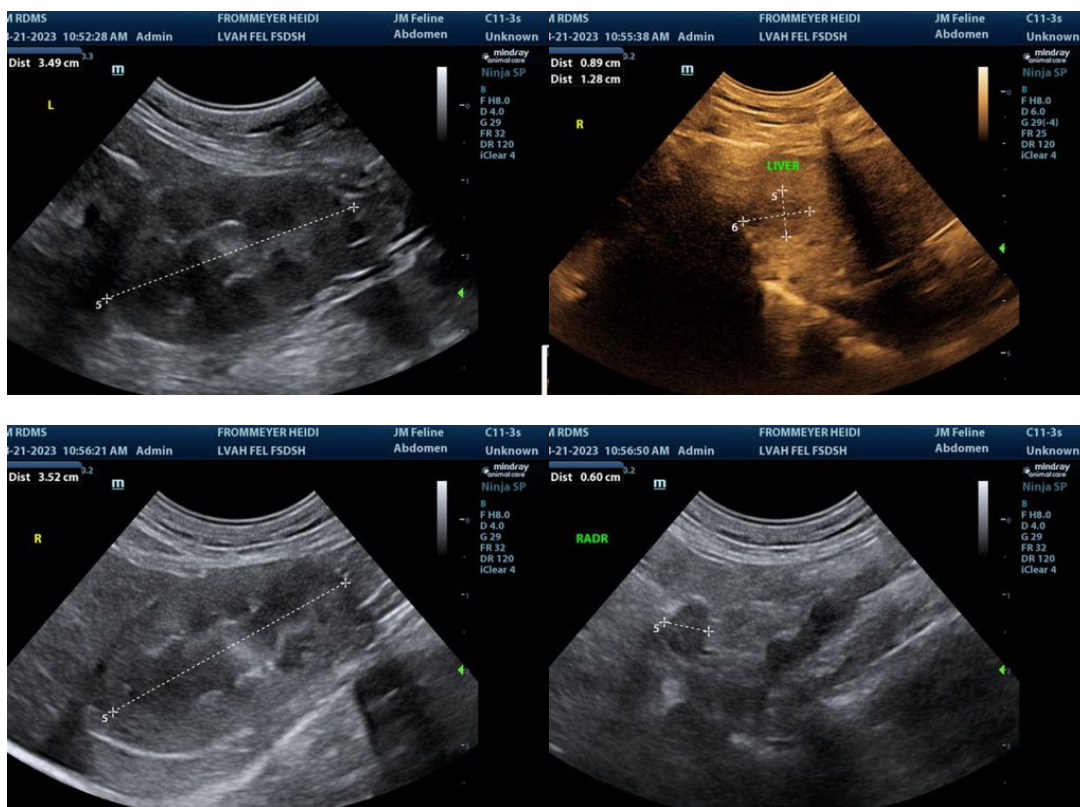
Spayed female

AGE

14 years

WEIGHT

8.12 lbs



INTERPRETED BY

Eric Lindquist, DMV
DABVP, Cert. IVUSS

IMAGING PERFORMED BY

Jessica Miller, RDMS

HOSPITAL NAME

Long Valley AH

REFERRING VET

Dr. Welch

INVOICE

46691

DATE

8/21/23

The information and recommendations provided are based on the images presented by the referring veterinarian/sonographer. No evaluation can be communicated regarding pathology that was not visible in the image/video clips provided.

Thank you for this referral. If the clinical or image interpretation does not parallel your findings or if I can be of any further assistance please contact me.

Eric Lindquist, DMV, DABVP, Cert. IVUSS, CEO of SonoPath.com
Info@SonoPath.com