



PATIENT

Lizzy VanSchaick

PRESENTING CLINICAL SIGNS

History: Hypothyroid, atypical Addison's, weight loss, lethargy Current medication = Red, soloxine.
Abnormal PE/Chem/CBC/UA Results: AlkPhos = 750, GGTP = 26, Triglycerides = 1026

SPECIES

Canine

ULTRASONOGRAPHIC EXAMINATION OF THE ABDOMEN

Urinary System

BREED

Great Pyrenees

The **urinary bladder**, trigone, and pelvic urethra presented normal thicknesses and normal tone. The ureters were not visible which is normal. No uroliths or sediment were visualized and anechoic urine was present. No evidence of inflammatory or neoplastic changes was noted. Ureteral papillae were normal.

SEX

Spayed female

The **kidneys** revealed normal size and structure, corticomedullary definition and ratio for this age. The cortices presented largely uniform texture with normal echogenic relationship to liver and spleen. Medullary structure differed distinctly from the cortex and no evidence of pelvic dilation was present. The capsules were acceptably uniform without significant irregularities. The right kidney measured 6.98 cm. The left kidney measured 6.86 cm.

AGE

9 years

WEIGHT

69.5 lbs

Adrenal Glands

The left adrenal gland was flattened, isoechoic and subnormal in size measuring 2.18 x 0.3 cm. The right adrenal gland measured 2.0 x 0.4 cm.

INTERPRETED BY

Eric Lindquist, DMV
DABVP, Cert. IVUSS

Spleen

The **spleen** presented a smooth homogeneous parenchyma hyperechoic to liver and renal cortical parenchyma. The capsule was smooth without noticeable expansion or deviation from within the spleen or adjacent pathology. The splenic vasculature demonstrated normal volume without signs of congestion or thrombosis. No sonographic evidence of acute or chronic inflammatory, neoplastic, or infarctual changes was noted.

IMAGING PERFORMED BY

Dr. Leal

HOSPITAL NAME

Blairstown AH

Liver

The **liver** was uniformly swollen with minor, excessive gallbladder debris and over distension with dependent and suspended bile without evidence of overt mucocele formation. However, excessive sludge was present. Slight gallbladder wall thickening was noted. The liver presented coarse architecture with mildly increased portal markings and subtle, mixed echogenic changes. This is consistent with vacuolar hepatopathy and some level of remodeling and history of inflammatory component. There was no overt suspicion of neoplasia.

REFERRING VET

Dr. Lovell

INVOICE

46673

Gastrointestinal

There was some residual chyme and gas was noted in the **stomach**, yet not pathological. This is consistent with end post prandial presentation. Transit of chyme into the small intestine was normal.

DATE

8/17/23



PATIENT

Lizzy VanSchaick

Curvilinear patterns were maintained throughout the GI tract. No evidence of pathology. Small and large intestine demonstrated normal luminal chyme and stool consistency respectively. No obstructive or overt infiltrative disease was noted. No associated abnormal lymphatic activity was noted.

SPECIES

Canine

Pancreas

The base and limbs of the **pancreas** were observed to be largely isoechoic to surrounding omental fat. Pancreatic duct and capsular contour were acceptably normal and parenchyma respected normal curvilinear patterns. No overt evidence of active inflammatory or neoplastic disease was noted.

BREED

Great Pyrenees

ULTRASONOGRAPHIC FINDINGS

SEX

Spayed female

Flattened adrenal glands.

Benign hepatopathy with minor gallbladder thickening.

AGE

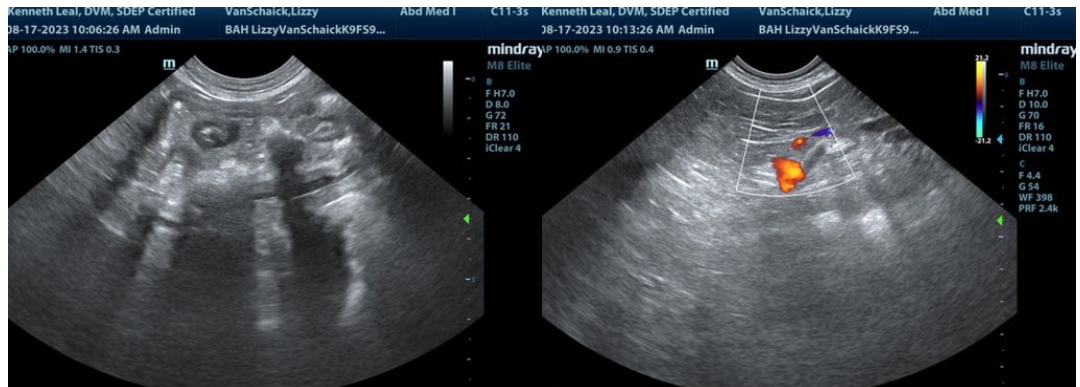
9 years

INTERPRETATION OF THE FINDINGS & FURTHER RECOMMENDATIONS

There was no evidence of visceral pathology. The cause of weight loss was not evident. Maldigestion panel, three view chest radiographs and full CNS examination is recommended to examine for occult disease that could be responsible for the weight loss. Evaluation for competitive eating environments should also be considered.

INTERPRETED BY

Eric Lindquist, DMV
DABVP, Cert. IVUSS

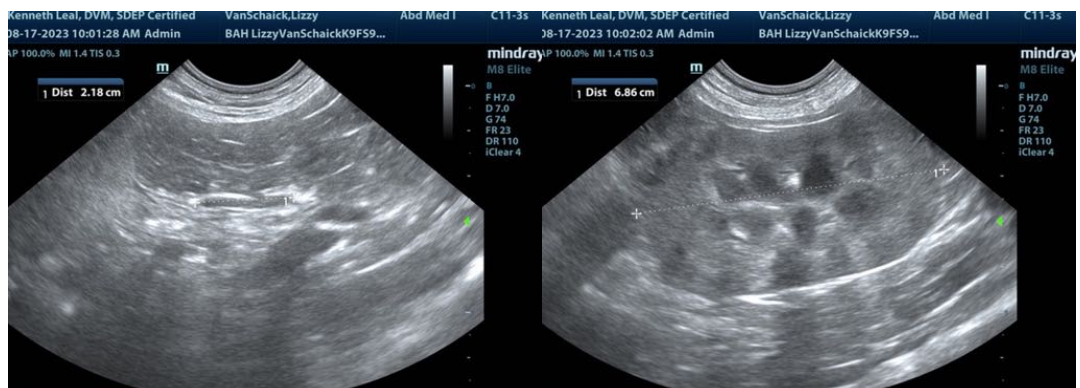

IMAGING PERFORMED BY

Dr. Leal

HOSPITAL NAME

Blairstown AH



REFERRING VET

Dr. Lovell

INVOICE

46673

DATE

8/17/23



PATIENT

Lizzy VanSchaick

SPECIES

Canine

BREED

Great Pyrenees

SEX

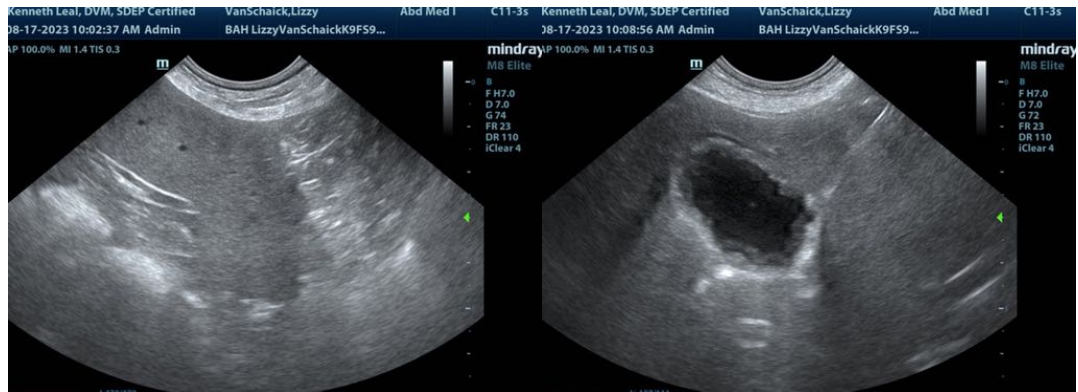
Spayed female

AGE

9 years

WEIGHT

69.5 lbs



SEX

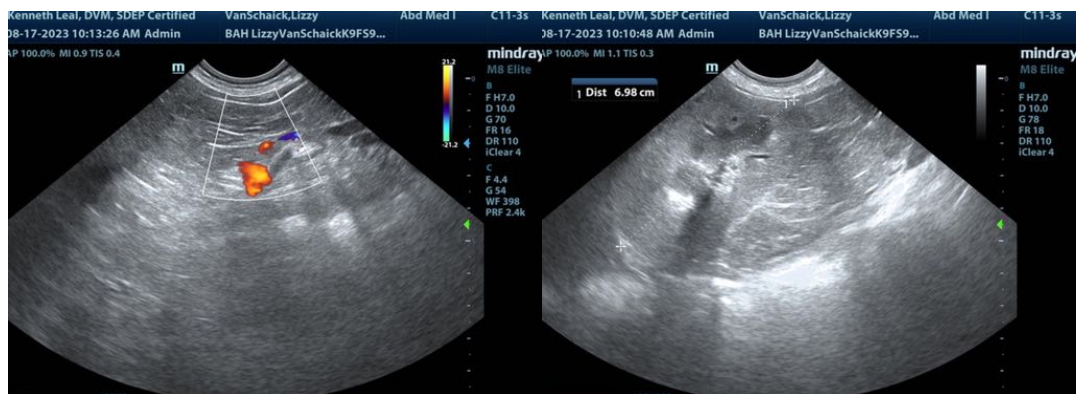
Spayed female

AGE

9 years

WEIGHT

69.5 lbs



INTERPRETED BY

Eric Lindquist, DMV
DABVP, Cert. IVUSS

IMAGING PERFORMED BY

Dr. Leal

HOSPITAL NAME

Blairstown AH

REFERRING VET

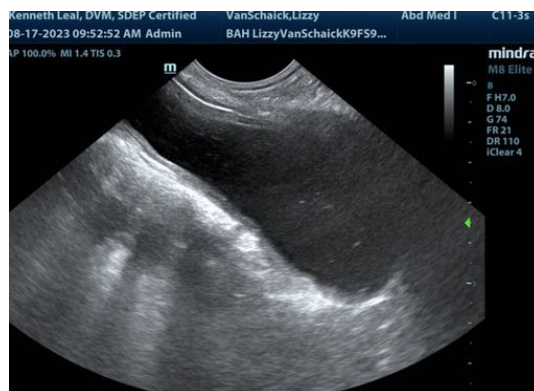Dr. Lovell

INVOICE

46673

DATE

8/17/23



The information and recommendations provided are based on the images presented by the referring veterinarian/sonographer. No evaluation can be communicated regarding pathology that was not visible in the image/video clips provided.

Thank you for this referral. If the clinical or image interpretation does not parallel your findings or if I can be of any further assistance please contact me.

Eric Lindquist, DMV, DABVP, Cert. IVUSS, CEO of SonoPath.com
info@SonoPath.com