



PATIENT

Sammi Nikolopovlous

SPECIES

Canine

BREED

German Shepherd

SEX

Neutered male

AGE

4 years

WEIGHT

82 lbs

INTERPRETED BY

Eric Lindquist, DMV
DABVP, Cert. IVUSS

IMAGING PERFORMED BY

Shari Reffi, CVT

HOSPITAL NAME

Basking Ridge AH

REFERRING VET

Dr. Rotella

INVOICE

32366

DATE

8/17/22

PRESENTING CLINICAL SIGNS

History: Started 8/13. P came home from boarding, decreased appetite and multiple episodes of vomiting. Diarrhea. O thinks unlikely to be FB. Current meds: Metronidazole, Omeprazole, one Cerenia inj.

Abnormal PE/Chem/CBC/UA Results: WNL

ULTRASONOGRAPHIC EXAMINATION OF THE ABDOMEN

Urinary System

The **urinary bladder**, trigone, and pelvic urethra presented normal thicknesses and normal tone. The ureters were not visible which is normal. No uroliths or sediment were visualized and anechoic urine was present. No evidence of inflammatory or neoplastic changes was noted. Ureteral papillae were normal.

The residual prostate was uniform and measured 1.55 cm.

The **kidneys** revealed normal size and structure, corticomedullary definition and ratio for this age. The cortices presented largely uniform texture with normal echogenic relationship to liver and spleen. Medullary structure differed distinctly from the cortex and no evidence of pelvic dilation was present. The capsules were acceptably uniform without significant irregularities. The right kidney measured 6.91 cm. The left kidney measured 7.94 cm.

Adrenal Glands

Both **adrenal glands** were visualized and recognized as having normal shape, size, position and echogenicity for this breed. The phrenic vasculature, glandular echogenicity and detail were unremarkable. Capsule, cortex, and medullary definition were normal for this age patient. The right adrenal gland measured 2.52 x 0.55 cm at the cranial pole and 0.67 cm at the caudal pole. The left adrenal gland measured 2.08 x 0.55 cm at the caudal pole and 0.54 cm at the cranial pole.

Spleen

The **spleen** in this patient was mildly enlarged with uniform parenchyma and was folded upon itself caudally. This is a positional variant and is not pathological. There was no evidence of significant disease.

Liver

The **liver** images submitted revealed subjectively normal liver size, contour, and structure. Parenchymal echogenicity was naturally coarse and hypoechoic to the spleen. Vascular and biliary tracts were of normal volume with no evidence of congestion. The gallbladder presented acceptably thin walls with primarily anechoic content. The cystic and common bile ducts were normal. No pathological hepatic lymphadenopathy was evident. No overt structural evidence of inflammatory, infiltrative or regenerative pathology was evident.



PATIENT

Gastrointestinal

Sammi Nikolopovlous

The **stomach** was empty with mild mucosal hypertrophy and slight luminal fluid. There was no evidence of foreign bodies. The small intestine was unremarkable, yet some intestinal spasming was present. Soft stool was noted in the colon.

SPECIES

Canine

Pancreas

BREED

German Shepherd

The base and limbs of the **pancreas** were observed to be largely isoechoic to surrounding omental fat. Pancreatic duct and capsular contour were acceptably normal and parenchyma respected normal curvilinear patterns. No overt evidence of active inflammatory or neoplastic disease was noted.

SEX

Neutered male

ULTRASONOGRAPHIC FINDINGS

Gastroenteritis pattern.

AGE

4 years

INTERPRETATION OF THE FINDINGS & FURTHER RECOMMENDATIONS

Dietary indiscretion, food intolerance, structurally significant inflammatory bowel or occult parasitism and occult Addison's are all potentials.

WEIGHT

82 lbs

INTERPRETED BY

Eric Lindquist, DMV
DABVP, Cert. IVUSS

IMAGING PERFORMED BY

Shari Reffi, CVT

HOSPITAL NAME

Basking Ridge AH

REFERRING VET

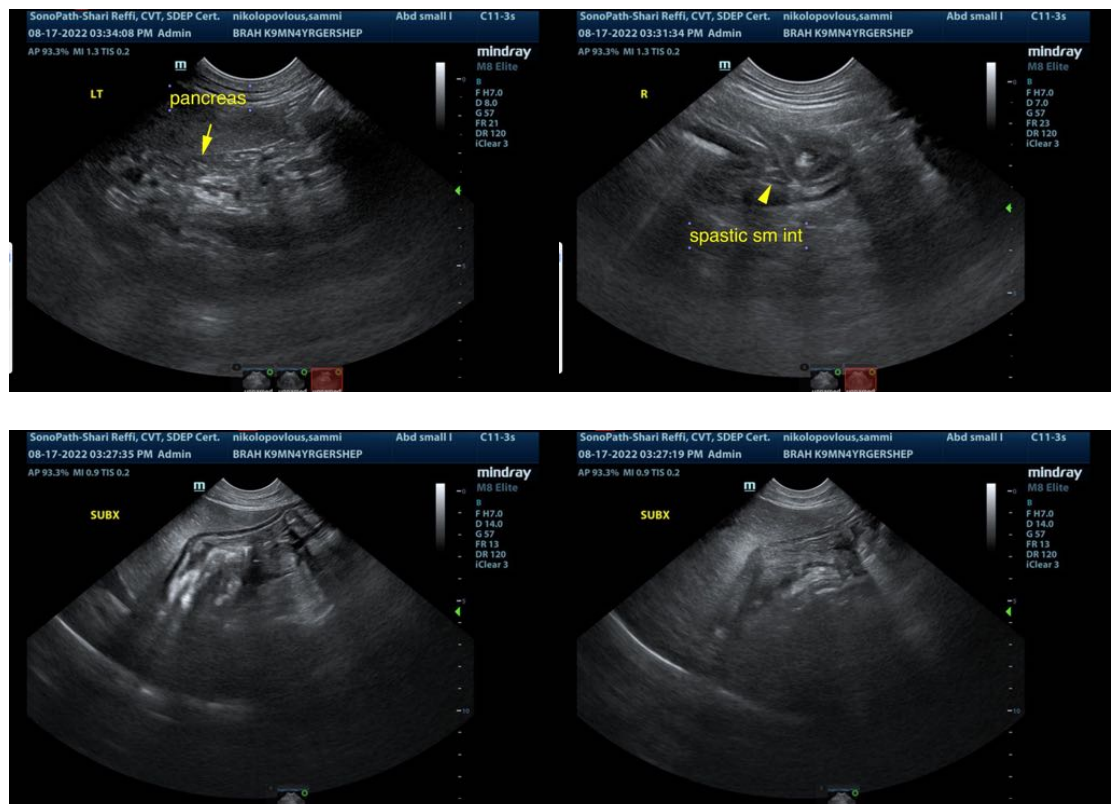
Dr. Rotella

INVOICE

32366

DATE

8/17/22





PATIENT

Sammi Nikolopovlous

SPECIES

Canine

BREED

German Shepherd

SEX

Neutered male

AGE

4 years

WEIGHT

82 lbs

INTERPRETED BY

Eric Lindquist, DMV
DABVP, Cert. IVUSS

IMAGING PERFORMED BY

Shari Reffi, CVT

HOSPITAL NAME

Basking Ridge AH

REFERRING VET

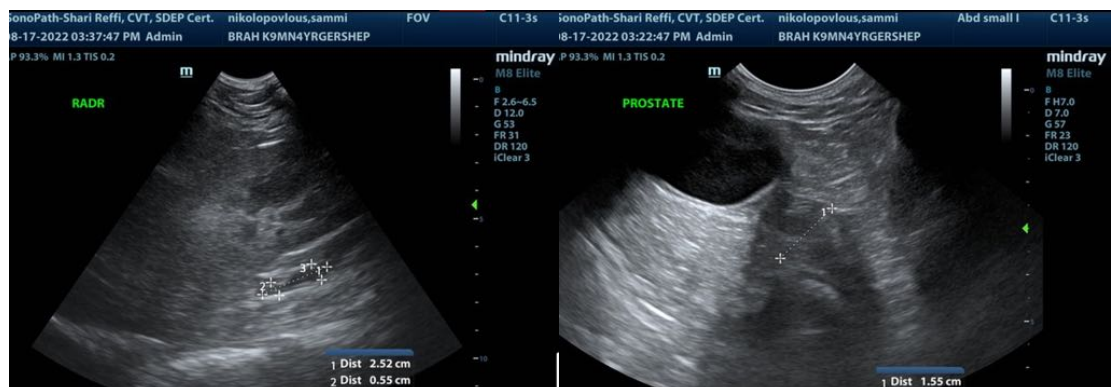
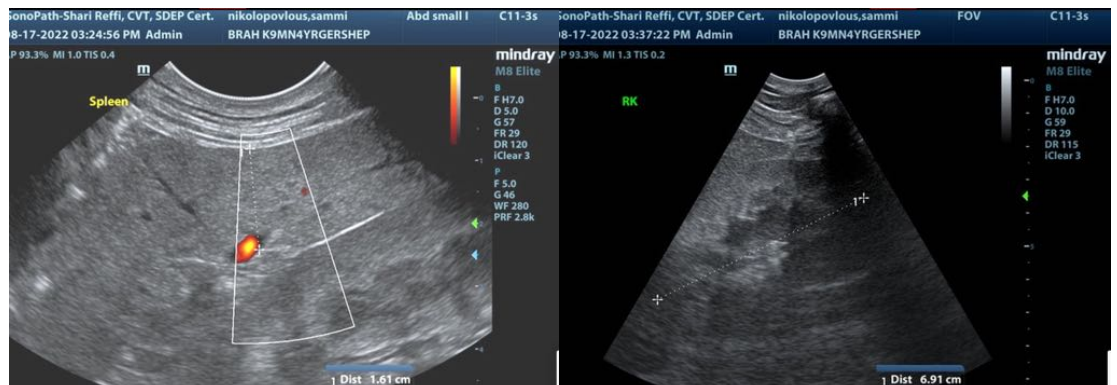
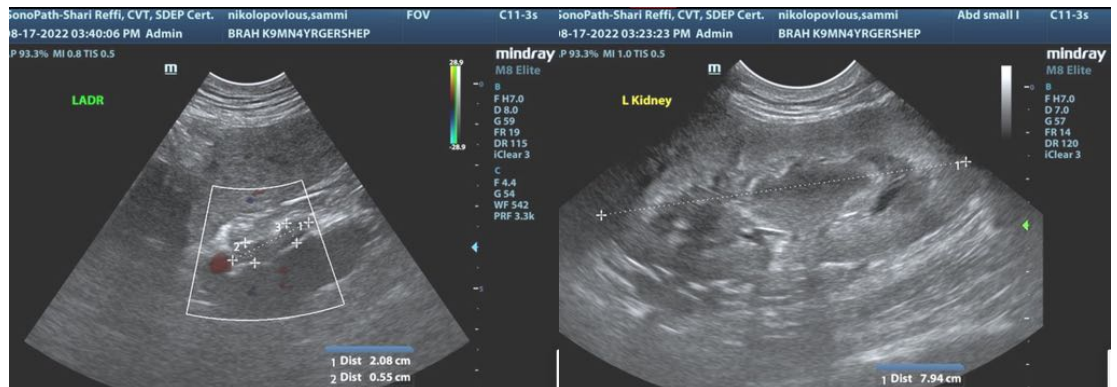
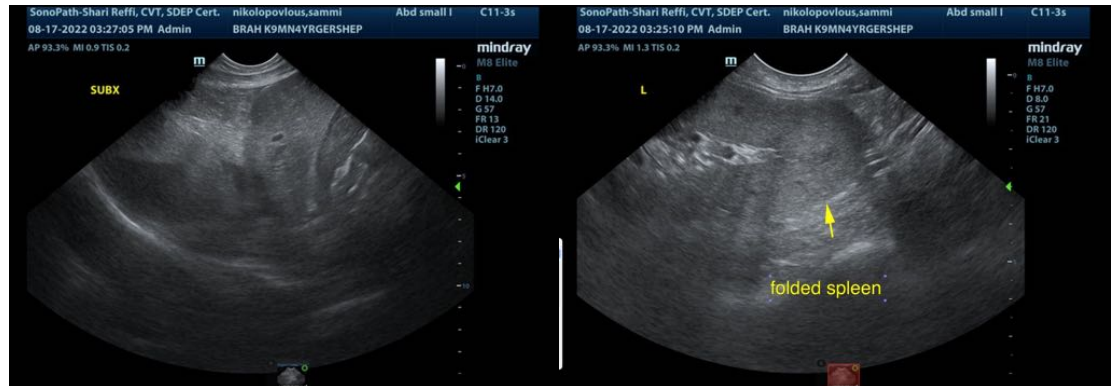
Dr. Rotella

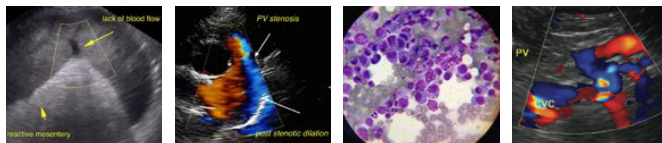
INVOICE

32366

DATE

8/17/22





PATIENT

Sammi Nikolopovlous

The information and recommendations provided are based on the images presented by the referring veterinarian/sonographer. No evaluation can be communicated regarding pathology that was not visible in the image/video clips provided.

SPECIES

Canine

Thank you for this referral. If the clinical or image interpretation does not parallel your findings or if I can be of any further assistance please contact me.

BREED

German Shepherd

Eric Lindquist, DMV, DABVP, Cert. IVUSS, CEO of SonoPath.com
Info@SonoPath.com

SEX

Neutered male

AGE

4 years

WEIGHT

82 lbs

INTERPRETED BY

Eric Lindquist, DMV
DABVP, Cert. IVUSS

**IMAGING
PERFORMED BY**

Shari Reffi, CVT

HOSPITAL NAME

Basking Ridge AH

REFERRING VET

Dr. Rotella

INVOICE

32366

DATE

8/17/22