



**PATIENT PRESENTING CLINICAL SIGNS**

Blitz Christian History: increased respiratory effort, IBD; 4/6 murmur. on prednisone 1 mg bid, Denamarin, proviable, gabapentin. ALKP 1346

**SPECIES**

Canine

**BREED**

Maltese

**SEX**

Neutered male

**AGE**

15 years

**WEIGHT**

8 lbs

**INTERPRETED BY**

Eric Lindquist, DMV  
DABVP, Cert. IVUSS

**IMAGING PERFORMED BY**

Diane McFadden, RVT

**HOSPITAL NAME**

Newton VH

**REFERRING VET**

Dr. Hannah

**INVOICE**

32311

**DATE**

8/11/22

**ULTRASONOGRAPHIC EXAMINATION OF THE ABDOMEN**

**Urinary System**

The **urinary bladder**, trigone, and pelvic urethra presented normal thicknesses and normal tone. The ureters were not visible which is normal. No uroliths or sediment were visualized and anechoic urine was present. No evidence of inflammatory or neoplastic changes was noted. Ureteral papillae were normal.

The **kidneys** revealed largely normal size and structure, corticomedullary definition and ratio (cortex 1/3 of medulla) were essentially maintained with some age-related loss of curvilinear patterns regarding the capsule and C/M junction. The cortices presented largely uniform texture with some increased echogenicity expected for his age patient. Medullary structure differed distinctly from that of the cortex and no evidence of pelvic dilation was present. Minor mineralization was noted in the kidneys. Cortical infarcts were noted with minor cortical collapse of the caudal pole of the left kidney. The right kidney measured 4.3 cm. The left kidney measured 3.14 cm.

**Adrenal Glands**

Both **adrenal glands** were visualized and recognized as having normal shape, size, position and echogenicity for this breed. The phrenic vasculature, glandular echogenicity and detail were unremarkable. Capsule, cortex, and medullary definition were normal for this age patient. The left adrenal gland measured 1.54 x 0.47 cm at the caudal pole and 0.46 cm at the cranial pole. The right adrenal gland measured 1.58 x 1.0 cm at the cranial pole at the cranial pole and 0.75 cm at the caudal pole.

**Spleen**

The **spleen** presented a smooth homogeneous parenchyma hyperechoic to liver and renal cortical parenchyma. The capsule was smooth without noticeable expansion or deviation from within the spleen or adjacent pathology. The splenic vasculature demonstrated normal volume without signs of congestion or thrombosis. No sonographic evidence of acute or chronic inflammatory, neoplastic, or infarctual changes was noted.

**Liver**

The **liver** images from right and left intercostal as well as subcostal views revealed subjectively normal liver size, contour, and structure. Some age-related parenchymal remodeling was noted but likely not clinically significant at this time. Vascular and biliary tracts were of normal volume and no evidence of congestion was noted. The gallbladder presented some dependent debris with essentially normal contour. The cystic and common bile ducts were normal. No overt evidence of active inflammatory, infiltrative or regenerative pathology was noted but should be paired with current or past LE elevations regarding any clinical significance to this presentation. The hepatic lymph nodes were unremarkable.



**PATIENT**

**Gastrointestinal**

Blitz Christian

Minor **pyloric** hypertrophy was noted. No neoplastic criteria is present. The small intestine and colon were unremarkable. The curvilinear patterns were maintained.

**SPECIES**

Canine

**Pancreas**

**BREED**

Maltese

The base and limbs of the **pancreas** were observed to be largely isoechoic to surrounding omental fat. Pancreatic duct and capsular contour were acceptably normal and parenchyma respected normal curvilinear patterns. No overt evidence of active inflammatory or neoplastic disease was noted.

**SEX**

Neutered male

**ULTRASONOGRAPHIC EXAMINATION OF THE HEART**

**AGE**

15 years

**WEIGHT**

8 lbs

The echocardiogram in this patient demonstrated normal **left atrial** size based on 3 different LA measurement methods. Complete filling of the left atrium was noted on color flow assessment of the mitral valve. Chamber volumes and echogenicity were normal. The cranial and caudal **mitral** valve leaflets presented vegetative thickening consistent with endocardiosis. Prolapse of the anterior mitral valve leaflet was noted, yet there was no volume overload. Doppler indicated measurable insufficiency. The **left ventricle** presented thicknesses with linear contour and was not dilated nor restricted. The **myocardium** presented normal echogenicity without subjective evidence of significant fibrotic or ischemic disease. **Contractility** of the ventricular walls was adequate and in normal range for this patient evidenced by the fractional shortening measurement and subjective evaluation of the different regions of the myocardium. Minor **aortic** insufficiency was also noted. The **right atrium** and auricle revealed normal size, structure and content. No evidence of masses was noted or chamber overload. **Tricuspid** valvular assessment demonstrated adequate linear morphology. The **right ventricle** was of normal size (1/3 diameter of LV), chordae structure, myocardial echogenicity and thickness. **Pulmonic** tract assessment revealed normal valve structure, laminar flow, and diameter (approx. 1:1 pa/ao ratio). No visible **pericardial** or free pleura fluid was noted. No echographically detectable evidence of infiltrative disease was visible. The cranial **mediastinum and pericardial regions** were free of masses in the visible window.

**INTERPRETED BY**

Eric Lindquist, DMV  
DABVP, Cert. IVUSS

**IMAGING PERFORMED BY**

Diane McFadden, RVT

**HOSPITAL NAME**

Newton VH

**REFERRING VET**

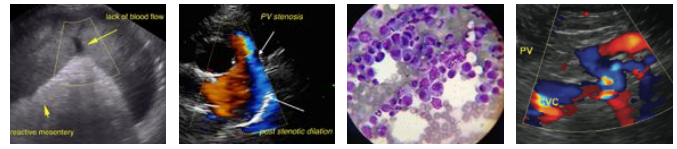
Dr. Hannah

**INVOICE**

32311

**DATE**

8/11/22


**PATIENT**

Blitz Christian

**SPECIES**

Canine

**BREED**

Maltese

**SEX**

Neutered male

**AGE**

15 years

**WEIGHT**

8 lbs

**INTERPRETED BY**

 Eric Lindquist, DMV  
 DABVP, Cert. IVUSS

**IMAGING PERFORMED BY**

Diane McFadden, RVT

**HOSPITAL NAME**

Newton VH

**REFERRING VET**

Dr. Hannah

**INVOICE**

32311

**DATE**

8/11/22

<b>CANINE CARDIAC PARAMETERS</b>	<b>MR VMAX</b> (m/s)	<b>TR VMAX</b> (m/s)	<b>LA/AO</b> (Boon method)	<b>LA/AO</b> (Heart Base; Swe)	<b>FS</b> (%)	<b>EF</b> (%)	<b>EPSS</b> (cm)
<b>NORMAL PARAMETER</b>	4.5-5.5	<2.7	1.3	<1.6	28-40	40-100	<0.6
<b>PATIENT</b>	5.26		1.2	1.22	41	74	0.2
<b>CANINE CARDIAC PARAMETERS</b>	<b>HR</b> (BPM)	<b>AV VMAX</b> (m/s)	<b>PV MAX</b> (m/s)	<b>BODY WEIGHT</b>	<b>LA</b> 2D short axis Base view (cm)	<b>LVIDd</b> Avg; 2D and m-mode short axis (cm)	<b>LVIDs</b> Avg; 2D and m-mode short axis (cm)
<b>NORMAL PARAMETER</b>	50-100	0.7-1.7	0.7-1.6	BELOW	BELOW	BELOW	BELOW
<b>PATIENT</b>	153		0.8	8 lbs	2.36	2.36	

**ULTRASONOGRAPHIC FINDINGS**

Stage B1 valvular disease with mitral valve prolapse, compensated.

Concurrent aortic insufficiency.

Age related abdominal changes.

**INTERPRETATION OF THE FINDINGS & FURTHER RECOMMENDATIONS**

No therapy is recommended at this time. The respiratory effort is non-cardiogenic in this patient. Blood pressure measurements are indicated. Assessment for primary respiratory disease or pain related respiratory effort is recommended.

The heart is stable without clinical disease. No overt contraindication for anesthesia of brief to moderate duration. I suggest Torbutrol premed, Propofol induction, Isoflo maintenance or similar protocol if anesthesia is desired. Blood pressure recommended if not already performed and target white coat negative systolic pressure of < 160 mmHg. If higher than this ACE-inhibitor is suggested to reach this level. Recheck echocardiogram is recommended in 6 months, earlier if murmur grade increases or clinical signs initiate.



**PATIENT**

Blitz Christian

**SPECIES**

Canine

**BREED**

Maltese

**SEX**

Neutered male

**AGE**

15 years

**WEIGHT**

8 lbs

**INTERPRETED BY**

Eric Lindquist, DMV  
DABVP, Cert. IVUSS

**IMAGING PERFORMED BY**

Diane McFadden, RVT

**HOSPITAL NAME**

Newton VH

**REFERRING VET**

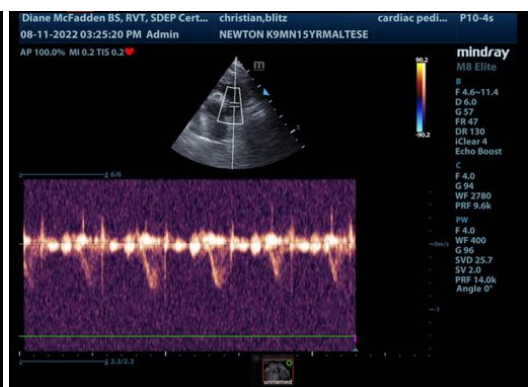
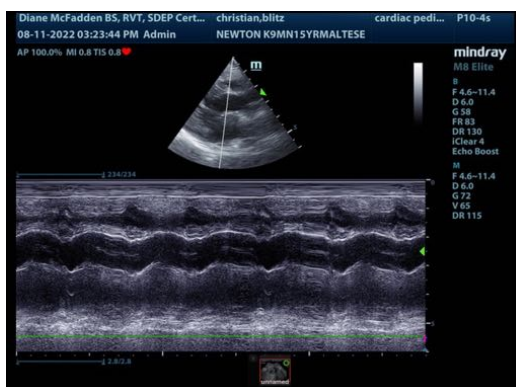
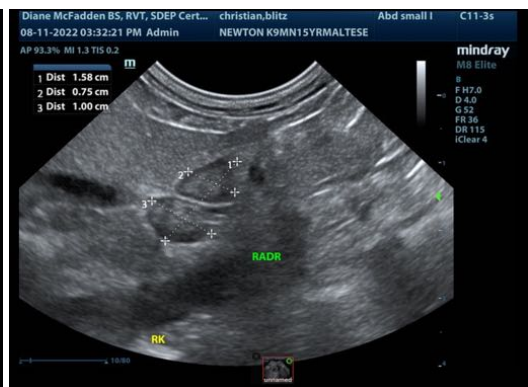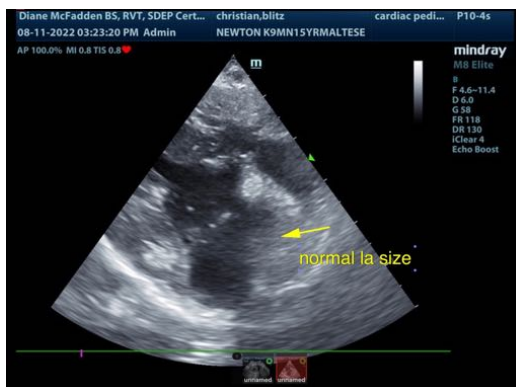
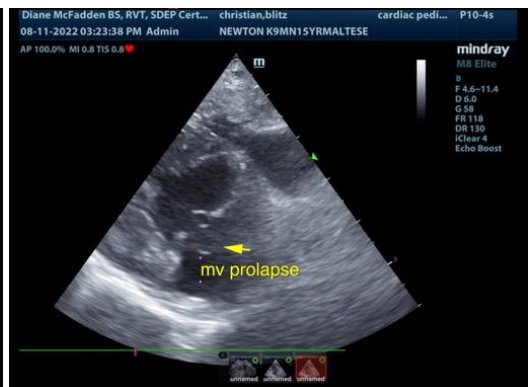
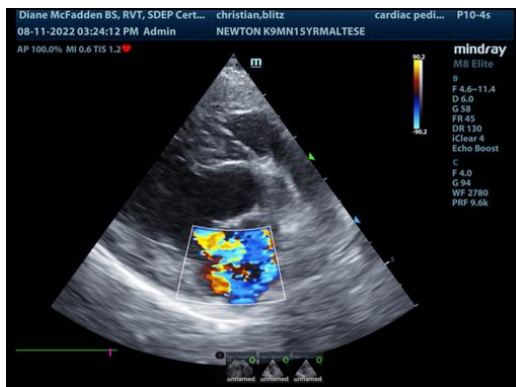
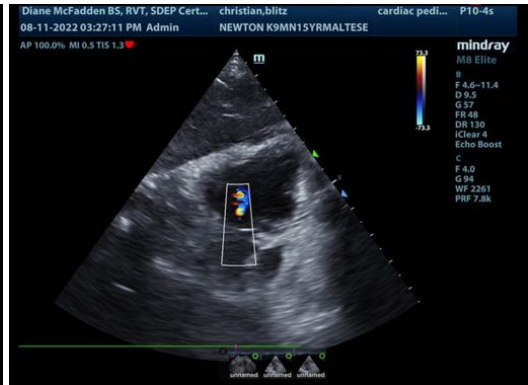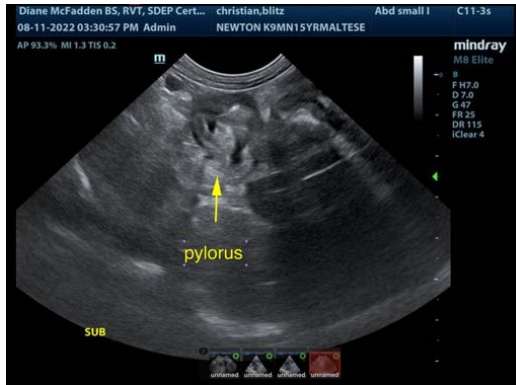
Dr. Hannah

**INVOICE**

32311

**DATE**

8/11/22





**PATIENT**

Blitz Christian

**SPECIES**

Canine

**BREED**

Maltese

**SEX**

Neutered male

**AGE**

15 years

**WEIGHT**

8 lbs

**INTERPRETED BY**

Eric Lindquist, DMV  
DABVP, Cert. IVUS

**IMAGING PERFORMED BY**

Diane McFadden, RVT

**HOSPITAL NAME**

Newton VH

**REFERRING VET**

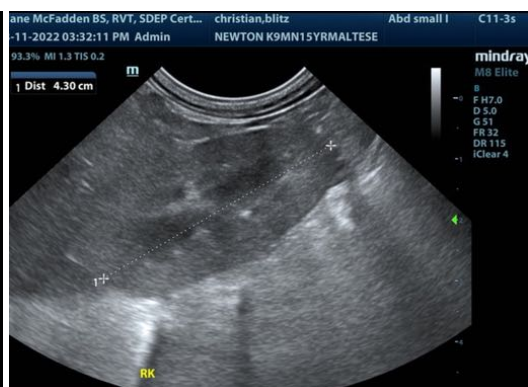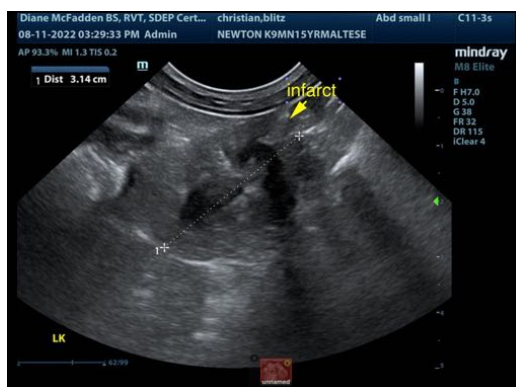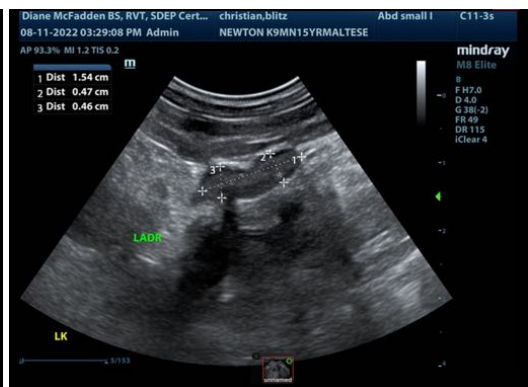
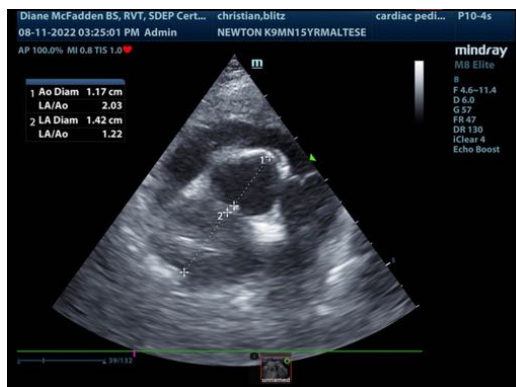
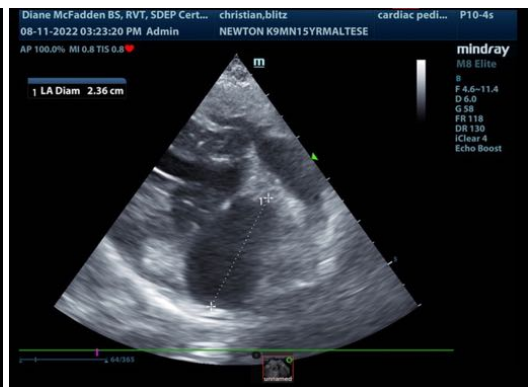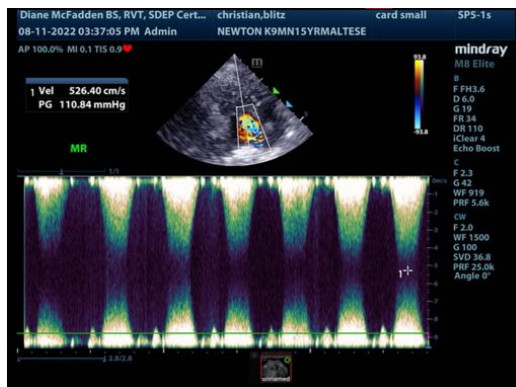
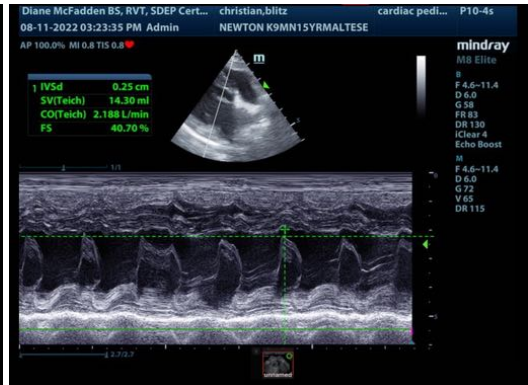
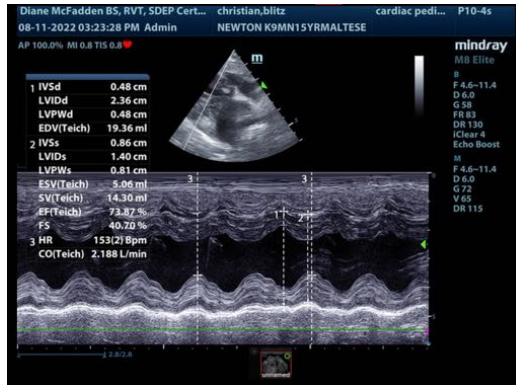
Dr. Hannah

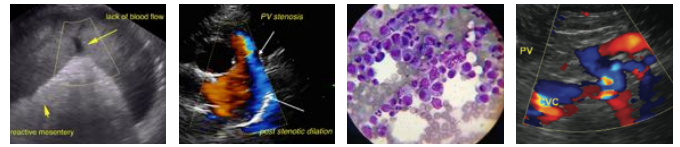
**INVOICE**

32311

**DATE**

8/11/22





**PATIENT**

Blitz Christian

The information and recommendations provided are based on the images presented by the referring veterinarian/sonographer. No evaluation can be communicated regarding pathology that was not visible in the image/video clips provided.

**SPECIES**

Canine

Thank you for this referral. If the clinical or image interpretation does not parallel your findings or if I can be of any further assistance please contact me.

**BREED**

Maltese

**Eric Lindquist**, DMV, DABVP, Cert. IVUSS, CEO of SonoPath.com  
Info@SonoPath.com

**SEX**

Neutered male

**AGE**

15 years

**WEIGHT**

8 lbs

**INTERPRETED BY**

Eric Lindquist, DMV  
DABVP, Cert. IVUSS

**IMAGING  
PERFORMED BY**

Diane McFadden, RVT

**HOSPITAL NAME**

Newton VH

**REFERRING VET**

Dr. Hannah

**INVOICE**

32311

**DATE**

8/11/22