

PATIENT

Marley Nafziger

SPECIES

Canine

BREED

Labrador Retriever

SEX

Spayed female

AGE

11 years

WEIGHT

81 lbs

INTERPRETED BY

Eric Lindquist, DMV
DABVP, Cert. IVUSS

IMAGING PERFORMED BY

Diane McFadden, RVT

HOSPITAL NAME

Blairstown AH

REFERRING VET

Dr. Clegg

INVOICE

46553

DATE

8/10/23

PRESENTING CLINICAL SIGNS

History: splenectomy 12/2022. elevated ALT/ALKP for 8 months. on Denamarin
Abnormal PE/Chem/CBC/UA Results: ALT 164, ALKP 634, Lyme positive

ULTRASONOGRAPHIC EXAMINATION OF THE ABDOMEN

Urinary System

The **urinary bladder**, trigone, and pelvic urethra presented normal thicknesses and normal tone. The ureters were not visible which is normal. No uroliths or sediment were visualized and anechoic urine was present. No evidence of inflammatory or neoplastic changes was noted. Ureteral papillae were normal.

The **kidneys** revealed largely normal size and structure, corticomedullary definition and ratio (cortex 1/3 of medulla) were essentially maintained with some age-related loss of curvilinear patterns regarding the capsule and C/M junction. The cortices presented largely uniform texture with some increased echogenicity expected for his age patient. Medullary structure differed distinctly from that of the cortex and no evidence of pelvic dilation was present. The left kidney measured 7.07 cm. The right kidney measured 7.5 cm.

Adrenal Glands

The left **adrenal gland** was uniform and enlarged measuring 3.5 x 1.09 cm at the caudal pole and 1.16 cm at the cranial pole. The right adrenal gland was mildly enlarged and measured 2.5 x 1.88 cm at the cranial pole and 1.06 cm at the caudal pole.

Spleen

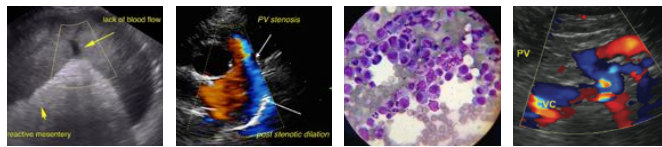
The **spleen** was not visualized as it was previously removed. The splenic fossa was unremarkable with no return of prior pathology.

Liver

The **liver** images from right and left intercostal as well as subcostal views revealed subjectively normal liver size, contour, and structure. Some age-related parenchymal remodeling was noted but likely not clinically significant at this time. Vascular and biliary tracts were of normal volume and no evidence of congestion was noted. The gallbladder presented some dependent debris with essentially normal contour. The cystic and common bile ducts were normal. No overt evidence of active inflammatory, infiltrative or regenerative pathology was noted but should be paired with current or past LE elevations regarding any clinical significance to this presentation. The hepatic lymph nodes were unremarkable.

Gastrointestinal

Examination of the **gastrointestinal tract** revealed a stomach and intestine free of stasis, of normal wall thickness, acceptable curvilinear mural detail, and peristaltic activity. Small and large intestine



PATIENT

Marley Nafziger

demonstrated normal luminal chyme and stool consistency respectively. No obstructive or overt infiltrative disease was noted. No associated abnormal lymphatic activity was noted.

SPECIES

Canine

Pancreas

The base and limbs of the **pancreas** were observed to be largely isoechoic to surrounding omental fat. Pancreatic duct and capsular contour were acceptably normal and parenchyma respected normal curvilinear patterns. No overt evidence of active inflammatory or neoplastic disease was noted.

BREED

Labrador Retriever

ULTRASONOGRAPHIC FINDINGS

SEX

Spayed female

Bilateral adrenal hypertrophy.

INTERPRETATION OF THE FINDINGS & FURTHER RECOMMENDATIONS

AGE

11 years

If the patient appears Cushingoid then emerging PDH may be an issue. If the urine specific gravity is less than 1.020 then work-up for Cushing's is indicated. Blood pressure measurements are warranted given the adrenal enlargement. There is no other evidence of pathology.

WEIGHT

81 lbs

Efficient & Accurate Cushing's Work up-Lindquist

Notes regarding Cushing's Clinical Presentations:

Nearly all Cushing's dogs have SAP elevations and true PU/PD (USG < 1.025) and most are polyphagic.

Cushing's dogs are > 6 years and usually > 9 years old, usually have poor skin coats, body scores > 3/5, and are usually sedentary animals.

Its important to remember that Cushing's dogs usually look and play the part and other diseases cause false + stress related cortisol spikes. On rare occasion a Cushing's dog will not follow the rules but this is truly an exception.

Potential Cushing's patient workups can be costly and frustrating if not definitive and, in my experience, the non-definitive patient usually has something else going on that may be contributing to some of the clinical signs a Cushing's dog will have, especially SAP elevations or PU/PD. Based on this prelude of information I came up with the following algorithm in the spirit of diagnostic efficiency. The following suggested protocol is based on current available literature on Cushing's disease and extensive clinical-sonographic experience evaluation + Cushing's and False + LDDST & ACTH stim. cases in order to maximize the efficiency of a Cushing's workup in practice.

INTERPRETED BY

Eric Lindquist, DMV
DABVP, Cert. IVUSS

Screen first, workup second

1) **UA:** Repeatable (2-3 urine samples) Urine specific gravity & urine cortisol/creatinine ratio (UCCR): If **repeatable USG < 10.20 and + UCCR** move to next step 2.

Note: UA is inexpensive and easy to obtain and if UA criteria is not met for Cushing's then resources can be spent into other more pertinent diagnostics or left on hold until the UA criteria is met in emerging Cushing's cases.

IMAGING PERFORMED BY

Diane McFadden, RVT

HOSPITAL NAME

Blairstown AH

REFERRING VET

Dr. Clegg

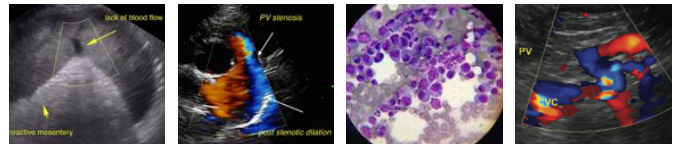
INVOICE

46553

DATE

8/10/23

2) **Sonogram:** Does the patient **have concurrent disease** clinically or sonographically as non-Cushing's illness will influence the potential false + LDDST or even ACTH stim. The sonogram gives a global perspective of the internal health of the patient to be considered in the Cushing's workup as an assessment of concurrent disease. Is there a concurrent neoplastic process, UTI pancreatitis,



PATIENT

Marley Nafziger

SPECIES

Canine

BREED

Labrador Retriever

SEX

Spayed female

AGE

11 years

WEIGHT

81 lbs

INTERPRETED BY

Eric Lindquist, DMV
DABVP, Cert. IVUSS

IMAGING PERFORMED BY

Diane McFadden, RVT

HOSPITAL NAME

Blairstown AH

REFERRING VET

Dr. Clegg

INVOICE

46553

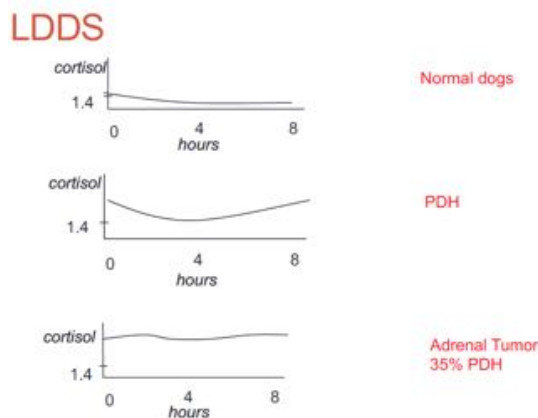
DATE

8/10/23

mucocele....? Are the adrenals enlarged (Cushing's-PDH, stress, age related or breed variant), or atrophied (iatrogenic Cushing's or adrenal burnout), have asymmetric enlargement (Adrenal tumor, hyperplasia, adenoma, age related variant), or is there vascular invasion (Invasive pheo with false + UA criteria or adenocarcinoma or phrenic thrombosis)? The sonogram answers these questions proactively.

Address & treat concurrent disease first before performing Cushing's testing or testing will be artificially altered increasing false negatives and positives.

3) **LDDST** (0.01 D-Sodium phosphate mg/kg IV **with precise dosing******) (Better screening test but plagued with false + but considered more specific than ACTH stim) Use if there is potential early Cushing's or if adrenal asymmetry present on sonogram suspecting tumor. Use LDDST in cats at a higher dose (0.1 mg/kg IV). **Interpretation LDDST:** Look at 8-hour post first: If > 1.4 = Cushing's. Then look at 4-hour: if > 1.4 or > 50% baseline = Cushing's. 4-hour do then 8-hour spike most consistent with PDH. Flat line high constant curve without dip more consistent with tumor but can be PDH. See attached graph.



Courtesy: Rebecca Berg DACVIM, DECVIM

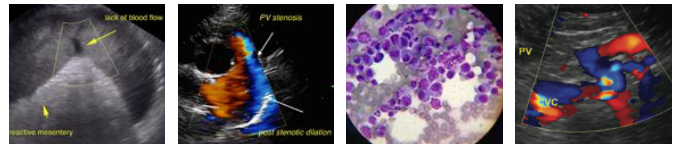
4) **ACTH stim.** (Better confirming test but can have false +) Use if the patient "looks" Cushingoid or if bilateral adrenal enlargement is present, or high normal width on sonogram, or if iatrogenic Cushing's suspected (Cortisone Tx in past). ACTH stim is better for diagnosis of Addisons, Iatrogenic Cushing's, and Cushing's therapy monitoring but problematic with initial Cushing's diagnosis. First dx LDDST is suggested.

5) If **diabetic** then run both LDDST & ACTH stim but stabilize as much as possible first.

5) Run a **serial blood pressure** in a BP friendly non "white coat effect" atmosphere. Run at least 3 at different times over a few hours or when eating as the patient tends to be calm when eating or give Torbutrol when entering the facility. Cushing's hypertension is usually 150-180 systolic range while pheochromocytoma range is more often > 180 systolic.

6) **Perform CT** of the pituitary to identify macro adenoma expansion if any lethargy or dullness or other central clinical CNS signs are minimally present. CT for adrenal may be more thorough for adrenalectomy surgical planning if ultrasound views of the CVC were problematic.

7) **Adrenectomy** for adrenal mass is prescribed then it is essential to stabilize the patient first regarding secondary disease such as organ dysfunction, hypertension, diabetes mellitus, hypernatremia, thromboembolic risk urinary and other infection in order to minimize potential for operative and



PATIENT

Marley Nafziger

postoperative complications as they are common in adrenalectomy. Trilostane stabilization therapy for Cushing's would be the first approach then address surgery and hypertension should be managed ideally < 160 systolic with ace inhibitors, phenoxybenzamine, or amlodipine.

SPECIES

Canine

Suggested reading:

BREED

Labrador Retriever

Behrend EN, Kooistra HS, Nelson R, et al. Diagnosis of Spontaneous Canine Hyperadrenocorticism: 2012 ACVIM Consensus Statement (Small Animal). J Vet Intern Med 2013;27:1292-1304.

SEX

Spayed female

AGE

11 years

WEIGHT

81 lbs

INTERPRETED BY

Eric Lindquist, DMV
DABVP, Cert. IVUSS

IMAGING PERFORMED BY

Diane McFadden, RVT

HOSPITAL NAME

Blairstown AH

REFERRING VET

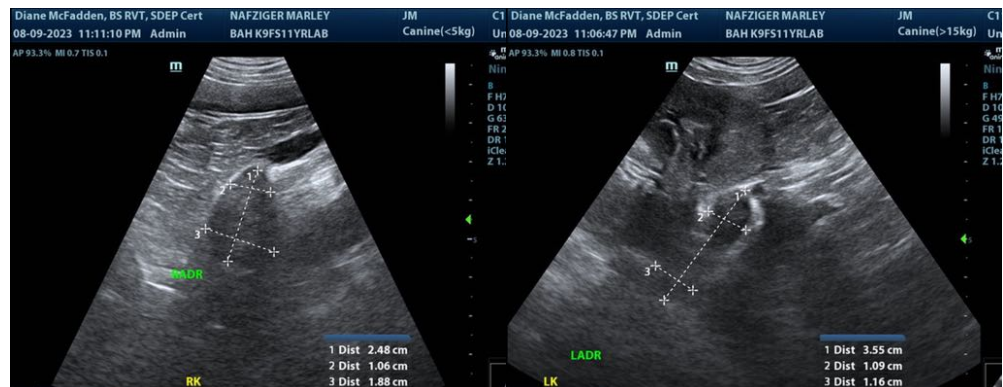
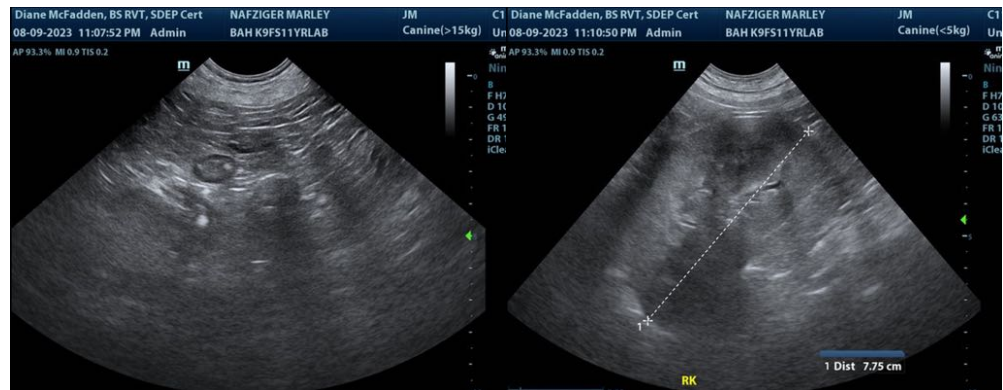
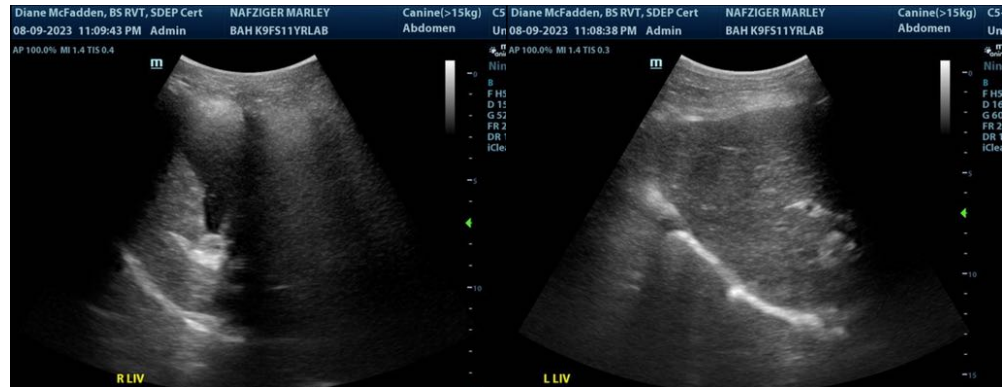Dr. Clegg

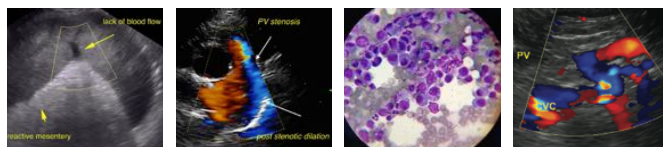
INVOICE

46553

DATE

8/10/23





PATIENT

Marley Nafziger

SPECIES

Canine

BREED

Labrador Retriever

SEX

Spayed female

AGE

11 years

WEIGHT

81 lbs

INTERPRETED BY

Eric Lindquist, DMV
DABVP, Cert. IVUSS

IMAGING PERFORMED BY

Diane McFadden, RVT

HOSPITAL NAME

Blairstown AH

REFERRING VET

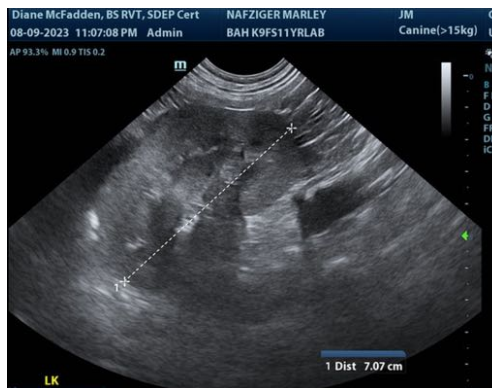Dr. Clegg

INVOICE

46553

DATE

8/10/23



The information and recommendations provided are based on the images presented by the referring veterinarian/sonographer. No evaluation can be communicated regarding pathology that was not visible in the image/video clips provided.

Thank you for this referral. If the clinical or image interpretation does not parallel your findings or if I can be of any further assistance please contact me.

Eric Lindquist, DMV, DABVP, Cert. IVUSS, CEO of SonoPath.com
Info@SonoPath.com