



PATIENT

Captain Frankovic

PRESENTING CLINICAL SIGNS

History: Hx of MVD-last echo 8/2022 (attached); Also hx of seizures/epilepsy. Grade IV/VI heart murmur. Current meds: Phenobarbital; Levetracetam; Gabapentin recently for digit fracture.

SPECIES

Canine

ULTRASONOGRAPHIC EXAMINATION OF THE HEART

The echocardiogram in this patient revealed persistent, mitral, tricuspid and aortic insufficiency. The contractility and volumes appeared normal. All four chambers were unremarkable. Mitral insufficiency presented an eccentric jet with mild to moderate filling of the left atrium. There was no pericardial or pleural disease and no evidence of masses.

BREED

Dachshund Mix

SEX

Neutered male

AGE

10 years

WEIGHT

25 lbs

INTERPRETED BY

Eric Lindquist, DMV
DABVP, Cert. IVUSS

CANINE CARDIAC PARAMETERS	MR VMAX (m/s)	TR VMAX (m/s)	LA/AO (Boon method)	LA/AO (Heart Base;)	FS (%)	EF (%)	EPSS (cm)
NORMAL PARAMETER	4.5-5.5	<2.7	1.3	Up to 1.6	28-40	40-100	<0.6
PATIENT	5.04	2.5	1.0	1.2	54	86	NM
CANINE CARDIAC PARAMETERS	HR (BPM)	AV VMAX (m/s)	PV MAX (m/s)	BODY WEIGHT	LA 2D short axis Base view (cm)	LVIDd Avg; 2D and m- mode short axis (cm)	LVIDs Avg; 2D and m- mode short axis (cm)
NORMAL PARAMETER	50-100	0.7-1.7	0.7-1.6	BELOW	BELOW	BELOW	BELOW
PATIENT	191	1.36	0.89	25 lbs	3.0	2.88	

**IMAGING
PERFORMED BY**

Shari Reffi CVT

ULTRASONOGRAPHIC FINDINGS

Persistent, stage B1 valvular disease.

HOSPITAL NAME

Long Valley AH

INTERPRETATION OF THE FINDINGS & FURTHER RECOMMENDATIONS

No therapy is recommended at this time.

REFERRING VET

Dr. Welch

The heart is stable without clinical disease. No overt contraindication for anesthesia of brief to moderate duration. I suggest Torbutrol premed, Propofol induction, Isoflo maintenance or similar protocol if anesthesia is desired. Blood pressure recommended if not already performed and target white coat negative systolic pressure of < 160 mmHg. If higher than this ACE-inhibitor is suggested to reach this level. Recheck echocardiogram is recommended in 6 months, earlier if murmur grade increases or clinical signs initiate.

INVOICE

46549

DATE

8/10/23



PATIENT

Captain Frankovic

SPECIES

Canine

BREED

Dachshund Mix

SEX

Neutered male

AGE

10 years

WEIGHT

25 lbs

INTERPRETED BY

Eric Lindquist, DMV
DABVP, Cert. IVUSS

IMAGING PERFORMED BY

Shari Reffi CVT

HOSPITAL NAME

Long Valley AH

REFERRING VET

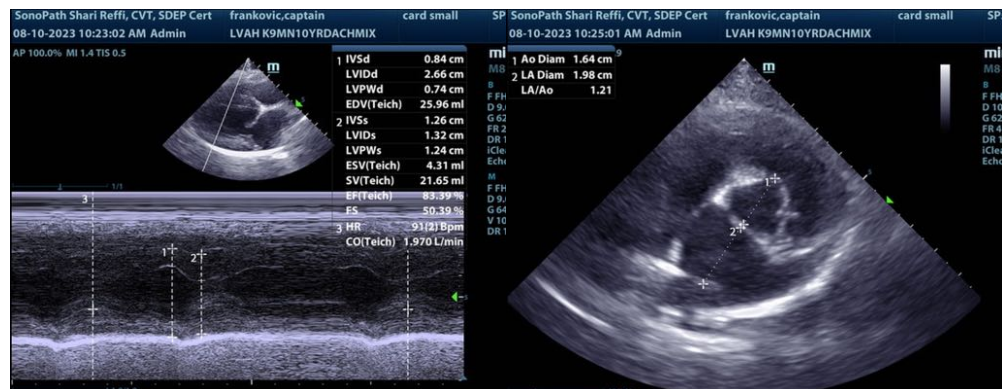
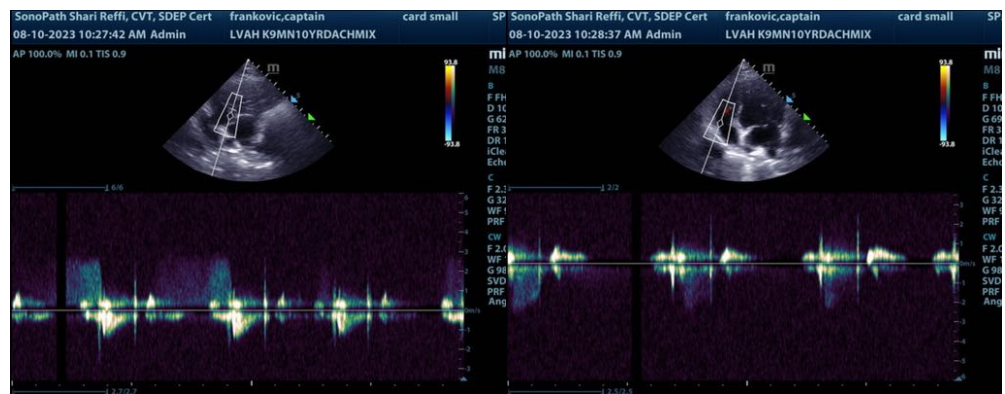
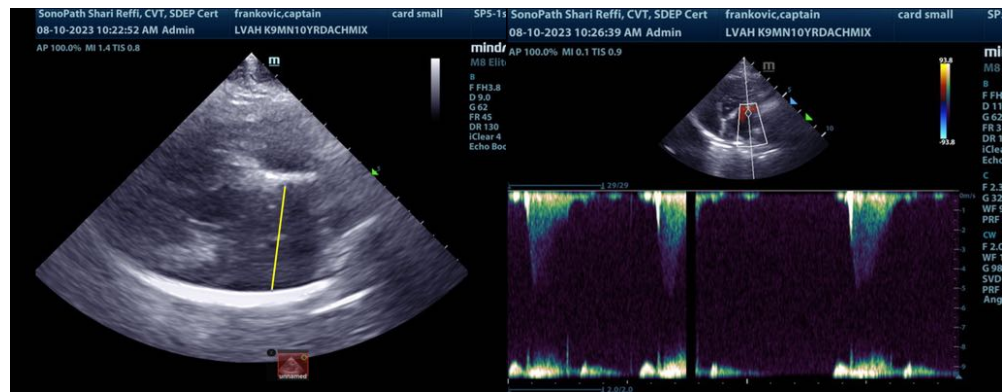
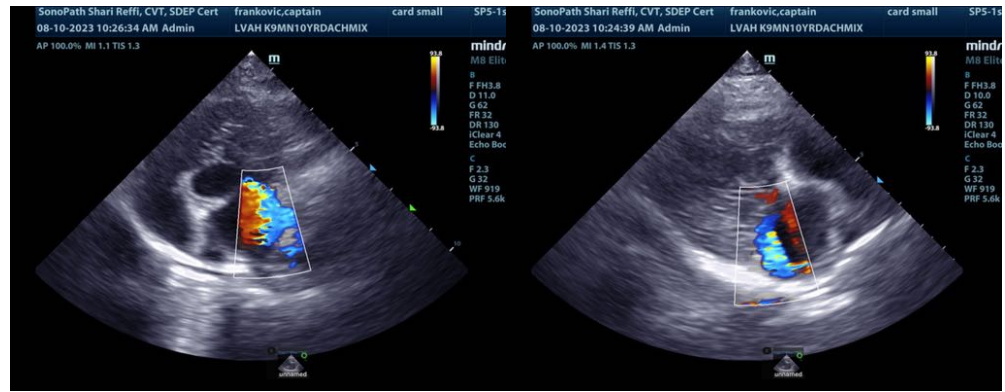
Dr. Welch

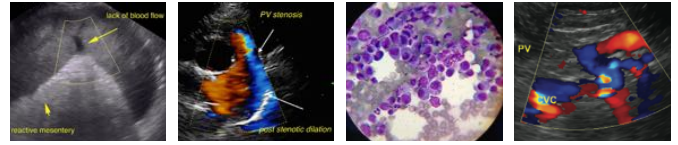
INVOICE

46549

DATE

8/10/23





PATIENT

Captain Frankovic

SPECIES

Canine

BREED

Dachshund Mix

SEX

Neutered male

AGE

10 years

WEIGHT

25 lbs

INTERPRETED BY

Eric Lindquist, DMV
DABVP, Cert. IVUSS

IMAGING PERFORMED BY

Shari Reffi CVT

HOSPITAL NAME

Long Valley AH

REFERRING VET

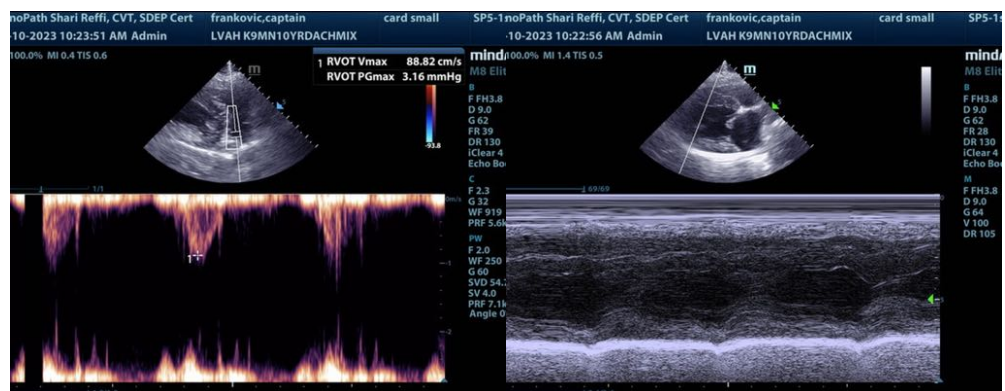
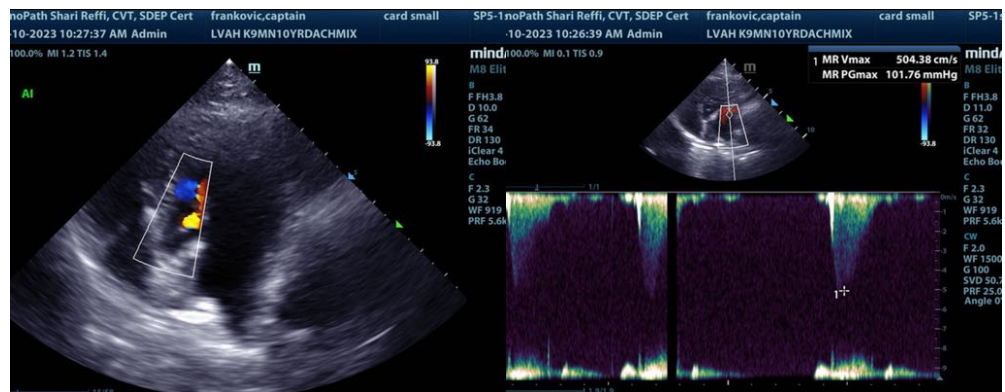
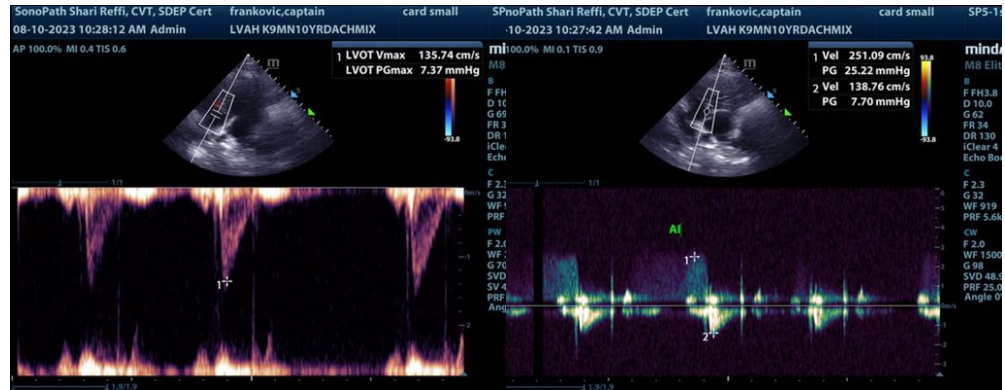
Dr. Welch

INVOICE

46549

DATE

8/10/23



The information and recommendations provided are based on the images presented by the referring veterinarian/sonographer. No evaluation can be communicated regarding pathology that was not visible in the image/video clips provided.

Thank you for this referral. If the clinical or image interpretation does not parallel your findings or if I can be of any further assistance please contact me.

Eric Lindquist, DMV, DABVP, Cert. IVUSS, CEO of SonoPath.com
info@SonoPath.com