

PATIENT PRESENTING CLINICAL SIGNS

Ben Scotti History: Heart murmur grade IV/VI systolic. No current meds.

SPECIES ULTRASONOGRAPHIC EXAMINATION OF THE HEART

Canine

BREED

Chihuahua

SEX

Neutered male

AGE

10 years

WEIGHT

12.5 lbs

The echocardiogram in this patient demonstrated enlarged **left atrial** size based on 3 different LA measurement methods. Chamber volumes and echogenicity were normal. The cranial and caudal **mitral** valve leaflets presented vegetative thickening consistent with endocardiosis. Prolapse of the anterior mitral valve leaflet was noted. Doppler indicated measurable insufficiency. The **left ventricle** presented normal thicknesses with linear contour and was not dilated nor restricted. The **myocardium** presented normal echogenicity without subjective evidence of significant fibrotic or ischemic disease. **Contractility** of the ventricular walls was adequate and in normal range for this patient evidenced by the fractional shortening measurement and subjective evaluation of the different regions of the myocardium. The **left ventricular outflow** tract demonstrated normal laminar flow and subjective structural integrity. The **right atrium** and auricle revealed normal size, structure and content. No evidence of masses was noted or chamber overload. **Tricuspid** valvular assessment demonstrated adequate linear morphology. The **right ventricle** was of normal size (1/3 diameter of LV), chordae structure, myocardial echogenicity and thickness. **Pulmonic** tract assessment revealed normal valve structure, laminar flow, and diameter (approx. 1:1 pa/ao ratio). No visible **pericardial** or free pleura fluid was noted. No echographically detectable evidence of infiltrative disease was visible. The cranial **mediastinum and pericardial regions** were free of masses in the visible window. Occasional arrhythmia was noted.

INTERPRETED BY

Eric Lindquist, DMV
DABVP, Cert. IVUSS

IMAGING PERFORMED BY

Jessica Miller, RDMS

HOSPITAL NAME

Riverdale Integrative
VC

REFERRING VET

Dr. Kuo

CANINE CARDIAC PARAMETERS	MR VMAX (m/s)	TR VMAX (m/s)	LA/AO (Boon method)	LA/AO (Heart Base;)	FS (%)	EF (%)	EPSS (cm)
NORMAL PARAMETER	4.5-5.5	<2.7	1.3	Up to 1.6	28-40	40-100	<0.6
PATIENT	5.45	-	1.1	1.18	43	76	0.1
CANINE CARDIAC PARAMETERS	HR (BPM)	AV VMAX (m/s)	PV MAX (m/s)	BODY WEIGHT	LA 2D short axis Base view (cm)	LVIDd Avg; 2D and m- mode short axis (cm)	LVIDs Avg; 2D and m-mode short axis (cm)
NORMAL PARAMETER	50-100	0.7-1.7	0.7-1.6	BELOW	BELOW	BELOW	BELOW
PATIENT	159	1.05		12.5 lbs	2.75 max	2.32	

INVOICE

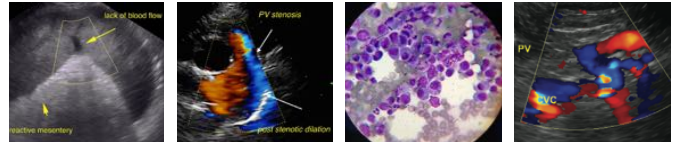
76353

DATE

8/1/23

ULTRASONOGRAPHIC FINDINGS

Stage B1 valvular disease with mitral valve prolapse, contained volumes and adequate contractility at this time. However, there is some arrhythmogenic activity.



PATIENT

Ben Scotti

INTERPRETATION OF THE FINDINGS & FURTHER RECOMMENDATIONS

EKG and blood pressure measurements are indicated. Given the prolapse attention should be paid towards increasing murmur grade as well as potential initiation of clinical signs if further degenerative changes occur in the mitral valve. However, there was no volume overload at this time that would justify therapy.

SPECIES

Canine

The heart is stable without clinical disease. No overt contraindication for anesthesia of brief to moderate duration. I suggest Torbutrol premed, Propofol induction, Isoflor maintenance or similar protocol if anesthesia is desired. Blood pressure recommended if not already performed and target white coat negative systolic pressure of < 160 mmHg. If higher than this ACE-inhibitor is suggested to reach this level. Recheck echocardiogram is recommended in 6 months, earlier if murmur grade increases or clinical signs initiate.

BREED

Chihuahua

SEX

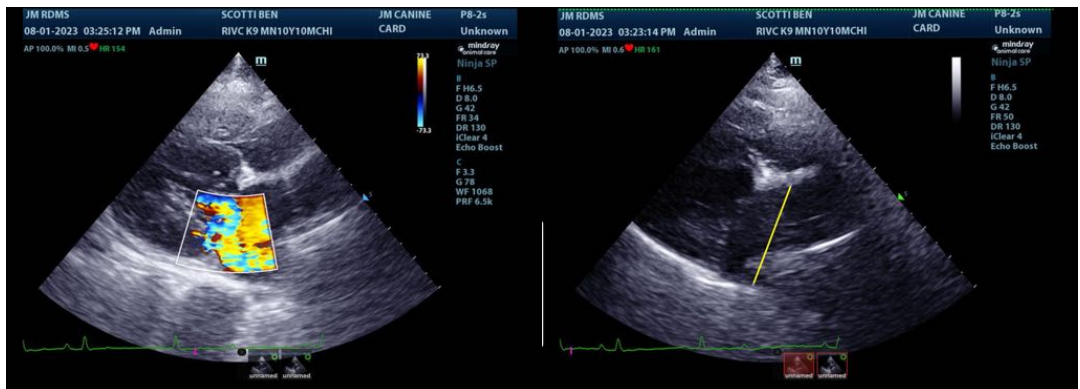
Neutered male

AGE

10 years

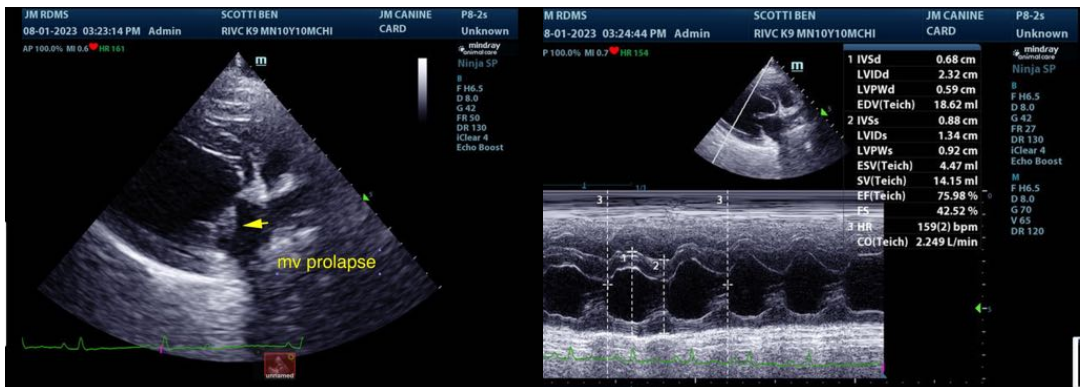
WEIGHT

12.5 lbs



INTERPRETED BY

Eric Lindquist, DMV
DABVP, Cert. IVUSS



IMAGING PERFORMED BY

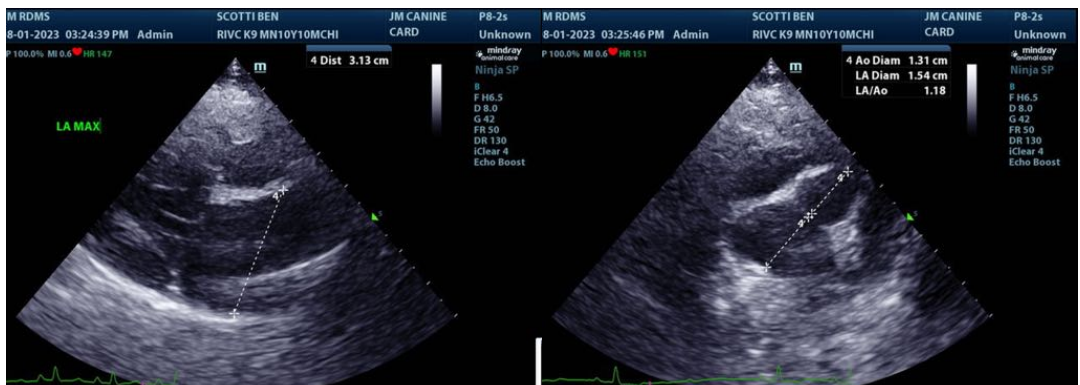Jessica Miller, RDMS

HOSPITAL NAME

Riverdale Integrative
VC

REFERRING VET

Dr. Kuo

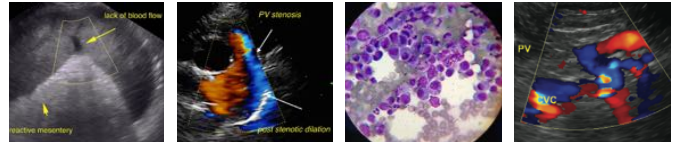


INVOICE

76353

DATE

8/1/23



PATIENT

Ben Scotti

SPECIES

Canine

BREED

Chihuahua

SEX

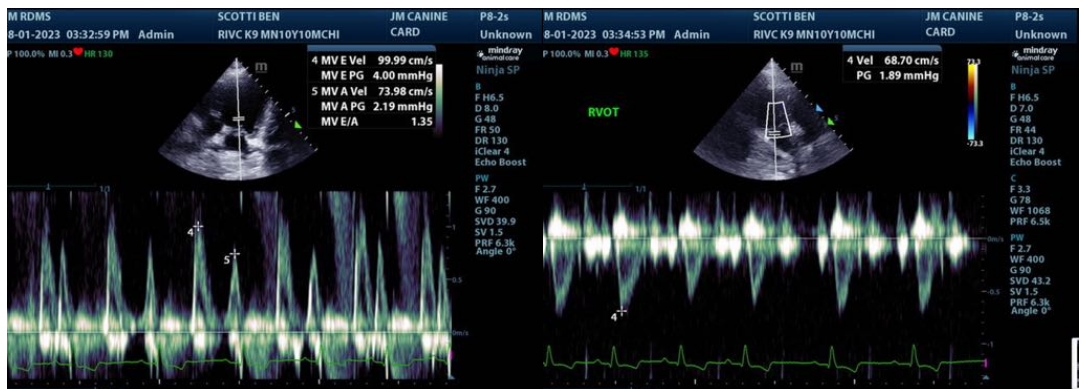
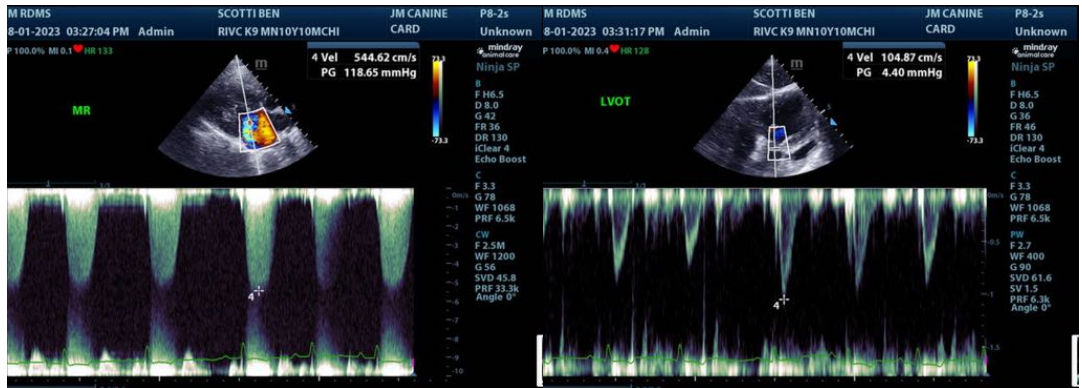
Neutered male

AGE

10 years

WEIGHT

12.5 lbs



INTERPRETED BY

Eric Lindquist, DMV
DABVP, Cert. IVUSS

IMAGING PERFORMED BY

Jessica Miller, RDMS

HOSPITAL NAME

Riverdale Integrative
VC

REFERRING VET

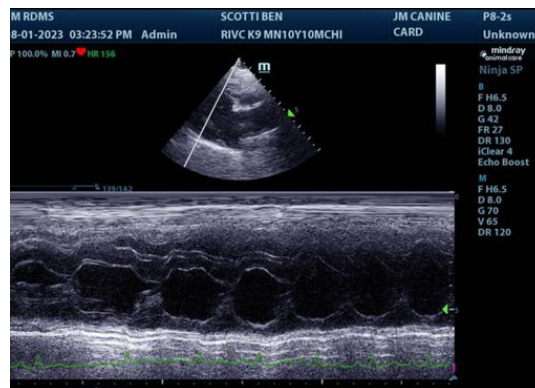
Dr. Kuo

INVOICE

76353

DATE

8/1/23



The information and recommendations provided are based on the images presented by the referring veterinarian/sonographer. No evaluation can be communicated regarding pathology that was not visible in the image/video clips provided.

Thank you for this referral. If the clinical or image interpretation does not parallel your findings or if I can be of any further assistance please contact me.

Eric Lindquist, DMV, DABVP, Cert. IVUSS, CEO of SonoPath.com
Info@SonoPath.com