


PATIENT PRESENTING CLINICAL SIGNS

Sheldon Bowlby History: Stage B2 MVD-follow up echo. Current Meds: Vetmedin

SPECIES ULTRASONOGRAPHIC EXAMINATION OF THE HEART

Canine

The echocardiogram in this patient presented persistent mitral and tricuspid insufficiency, currently compensated regarding current volumes. Complete filling of the left atrium was noted on color flow assessment of the mitral valve. Occasional arrhythmia was noted in this patient. The pericardial and pleural spaces were unremarkable.

BREED

 King Charles Cavalier
 Spaniel

SEX

Neutered male

AGE

8 years

WEIGHT

18 lbs

INTERPRETED BY

 Eric Lindquist, DMV
 DABVP, Cert. IVUSS

CANINE CARDIAC PARAMETERS	MR VMAX (m/s)	TR VMAX (m/s)	LA/AO (Boon method)	LA/AO (Heart Base;)	FS (%)	EF (%)	EPSS (cm)
NORMAL PARAMETER	4.5-5.5	<2.7	1.3	<1.6	28-40	40-100	<0.6
PATIENT	5.5	2.5	NM	1.1	40	85	0.49
CANINE CARDIAC PARAMETERS	HR (BPM)	AV VMAX (m/s)	PV MAX (m/s)	BODY WEIGHT	LA 2D short axis Base view (cm)	LVIDd Avg; 2D and m- mode short axis (cm)	LVIDs Avg; 2D and m-mode short axis (cm)
NORMAL PARAMETER	50-100	0.7-1.7	0.7-1.6	BELOW	BELOW	BELOW	BELOW
PATIENT	70	1.4	0.65	18 lbs	3.7 max	3.1	

IMAGING PERFORMED BY

Shari Reffi CVT

HOSPITAL NAME

VCA Blairstown AH

REFERRING VET

Dr. Lovell

INVOICE

75980

DATE

7/7/23

ULTRASONOGRAPHIC FINDINGS

Compensated mitral and tricuspid disease on current medication with arrhythmia.

INTERPRETATION OF THE FINDINGS & FURTHER RECOMMENDATIONS

I recommend continuation of the current protocol. However, EKG or Holter monitor would be warranted to assess if arrhythmogenic disease needs to be addressed medically.



PATIENT

Sheldon Bowlby

SPECIES

Canine

BREED

King Charles Cavalier
Spaniel

SEX

Neutered male

AGE

8 years

WEIGHT

18 lbs

INTERPRETED BY

Eric Lindquist, DMV
DABVP, Cert. IVUSS

**IMAGING
PERFORMED BY**

Shari Reffi CVT

HOSPITAL NAME

VCA Blairstown AH

REFERRING VET

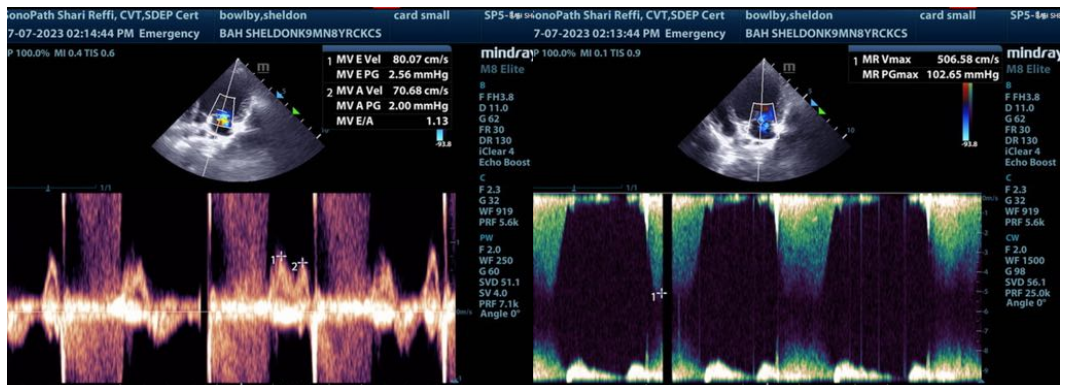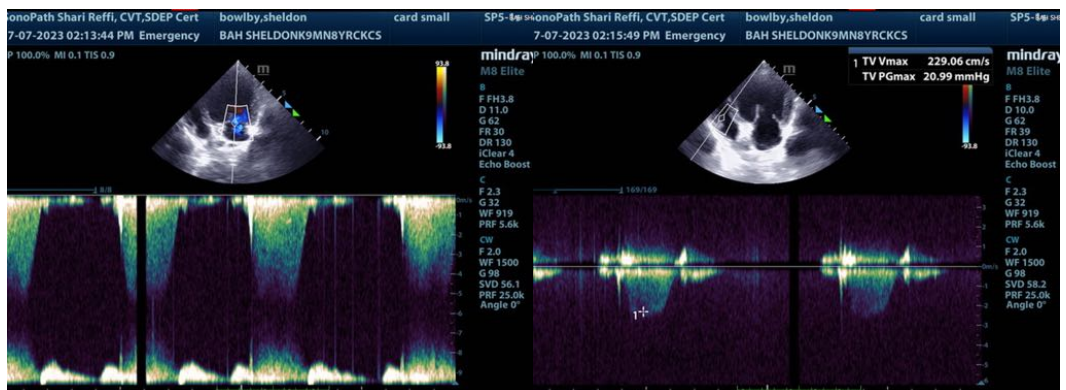
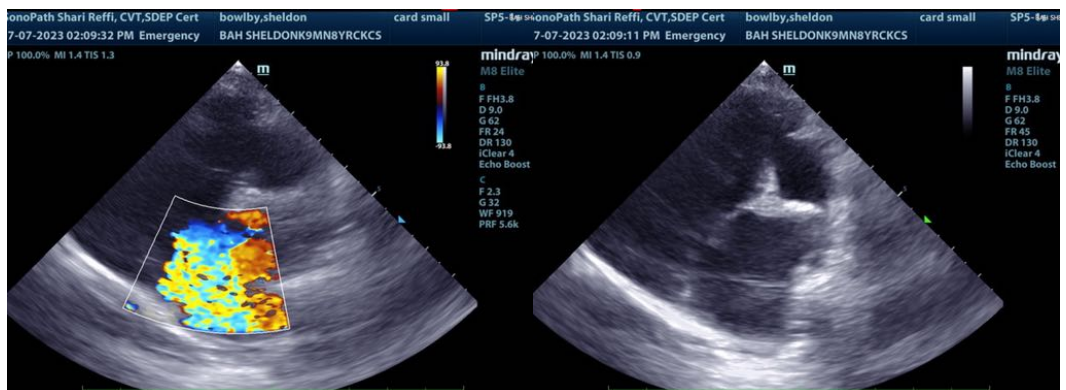
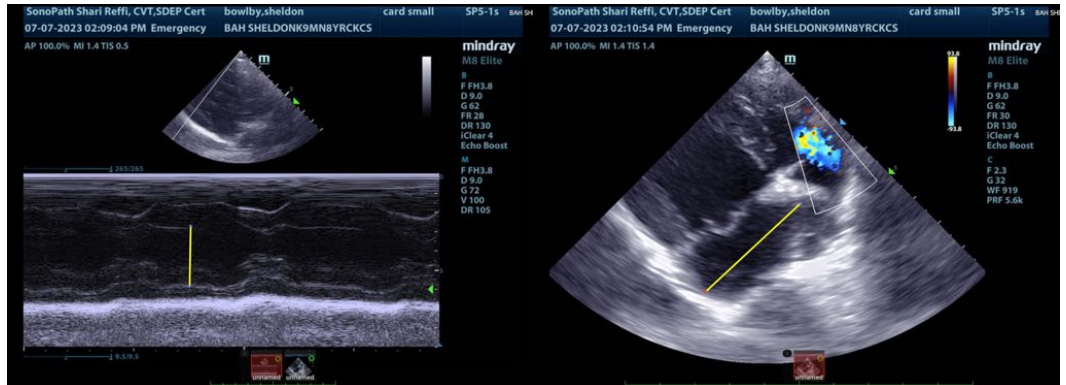
Dr. Lovell

INVOICE

75980

DATE

7/7/23





PATIENT

Sheldon Bowlby

SPECIES

Canine

BREED

King Charles Cavalier
Spaniel

SEX

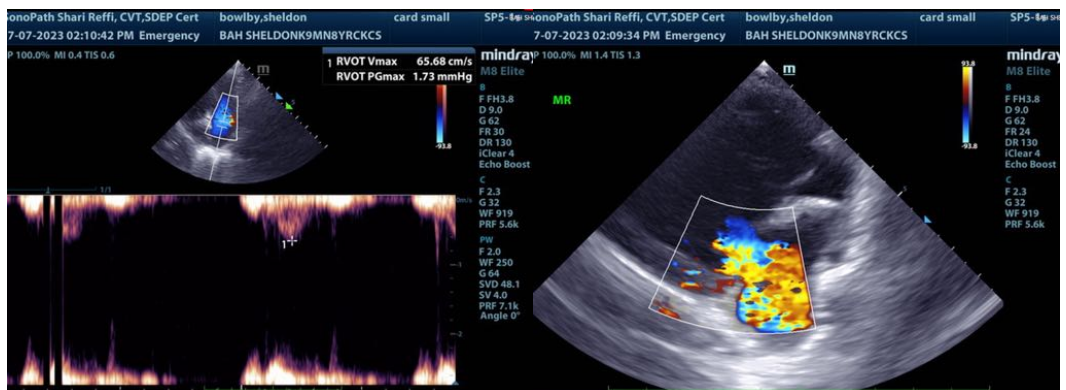
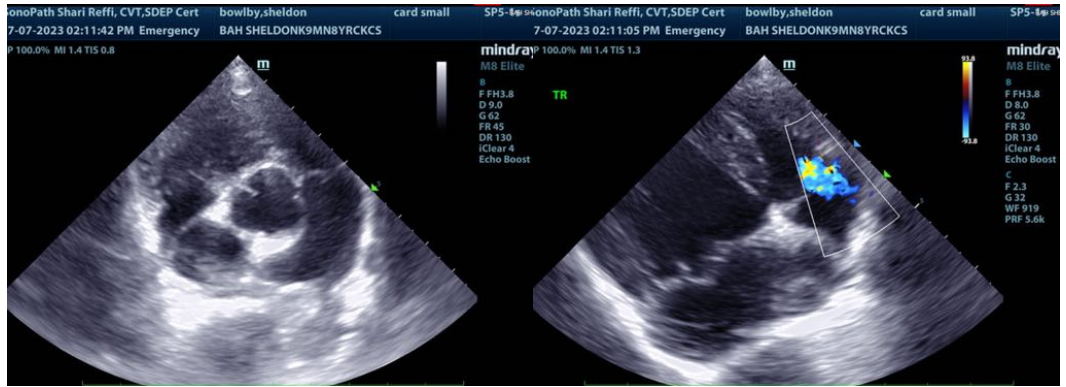
Neutered male

AGE

8 years

WEIGHT

18 lbs



INTERPRETED BY

Eric Lindquist, DMV
DABVP, Cert. IVUSS

IMAGING PERFORMED BY

Shari Reffi CVT

HOSPITAL NAME

VCA Blairstown AH

REFERRING VET

Dr. Lovell

INVOICE

75980

DATE

7/7/23

The information and recommendations provided are based on the images presented by the referring veterinarian/sonographer. No evaluation can be communicated regarding pathology that was not visible in the image/video clips provided.

Thank you for this referral. If the clinical or image interpretation does not parallel your findings or if I can be of any further assistance please contact me.

Eric Lindquist, DMV, DABVP, Cert. IVUSS, CEO of SonoPath.com
info@SonoPath.com