


PATIENT

Howard Bowlby

PRESENTING CLINICAL SIGNS

History: Stage B1 MVD-follow up echo. PPHx small PDA has resolved.

SPECIES

Canine

ULTRASONOGRAPHIC EXAMINATION OF THE HEART

The echocardiogram in this patient revealed normal volumes. Mitral and tricuspid insufficiency was noted. Contractility appeared adequate with moderate filling of the left atrium noted. The deep pulmonary artery revealed a tiny, very subtle, holosystolic jet. This is consistent with a very small PDA, yet this has been variable on prior echocardiogram; however, the lesion is exceedingly small and the hemodynamic significance is minor. There was no significant pulmonic insufficiency noted.

BREED

King Charles Cavalier

SEX

Male

CANINE CARDIAC PARAMETERS	MR VMAX (m/s)	TR VMAX (m/s)	LA/AO (Boon method)	LA/AO (Heart Base;)	FS (%)	EF (%)	EPSS (cm)
NORMAL PARAMETER	4.5-5.5	<2.7	1.3	<1.6	28-40	40-100	<0.6
PATIENT	6.0		1.2	1.5			NM
CANINE CARDIAC PARAMETERS	HR (BPM)	AV VMAX (m/s)	PV MAX (m/s)	BODY WEIGHT (kg)	LA 2D short axis Base view (cm)	LVIDd Avg; 2D and m- mode short axis (cm)	LVIDs Avg; 2D and m-mode short axis (cm)
NORMAL PARAMETER	50-100	0.7-1.7	0.7-1.6	BELOW	BELOW	BELOW	BELOW
PATIENT		1.4	1.0	24 lbs	2.4		

AGE

6 years

WEIGHT

24 lbs

INTERPRETED BY

 Eric Lindquist, DMV
 DABVP, Cert. IVUS

**IMAGING
PERFORMED BY**

Shari Reffi CVT

HOSPITAL NAME

 Sonopath Imaging
 Center

REFERRING VET

Dr. Lovell

ULTRASONOGRAPHIC FINDINGS

Very small, persistent PDA.

Mitral and tricuspid insufficiency.

INVOICE

75981

DATE

7/7/23

INTERPRETATION OF THE FINDINGS & FURTHER RECOMMENDATIONS

This is not hemodynamically significant at this time. There was no evidence of volume overload. Cardiology referral can be considered for potential intervention, yet the heart appears well compensated at this time. Blood pressure measurements are recommended.



PATIENT

Howard Bowlby

SPECIES

Canine

BREED

King Charles Cavalier

SEX

Male

AGE

6 years

WEIGHT

24 lbs

INTERPRETED BY

Eric Lindquist, DMV
DABVP, Cert. IVUS

IMAGING PERFORMED BY

Shari Reffi CVT

HOSPITAL NAME

Sonopath Imaging
Center

REFERRING VET

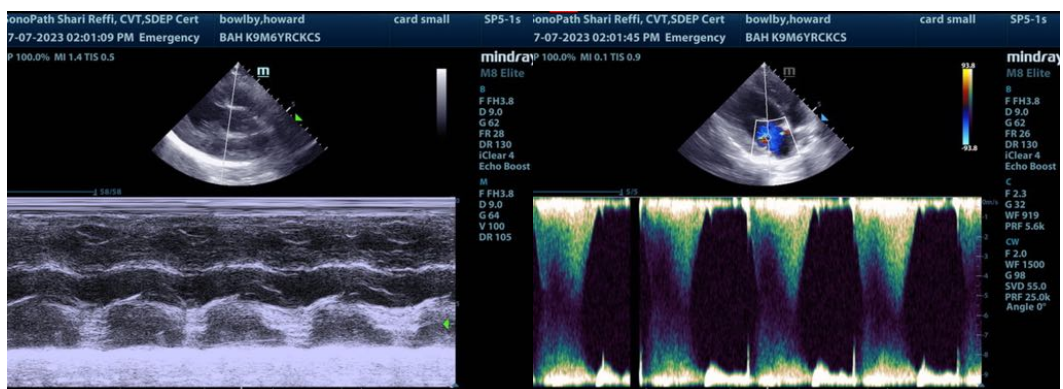
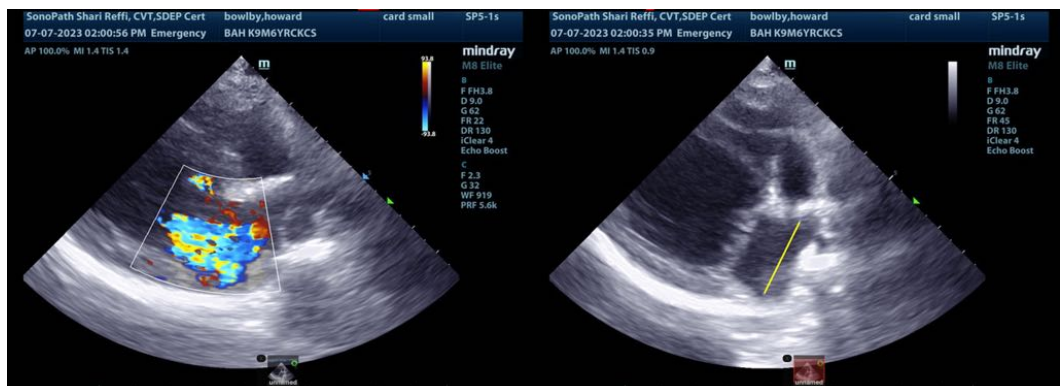
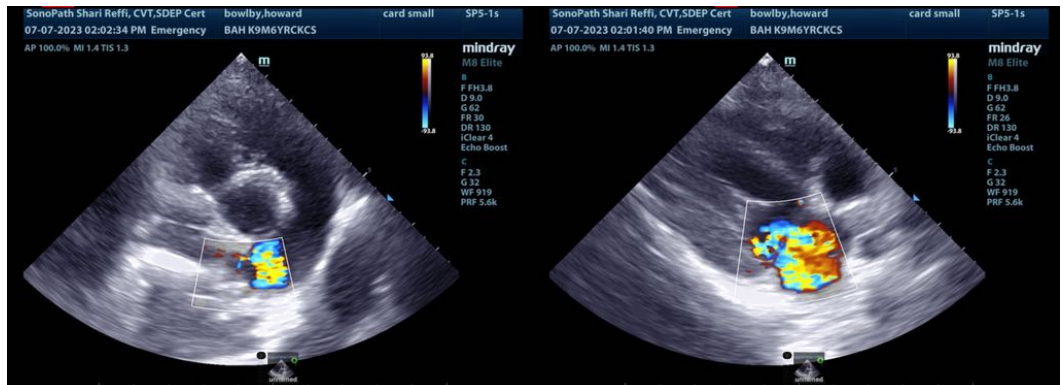
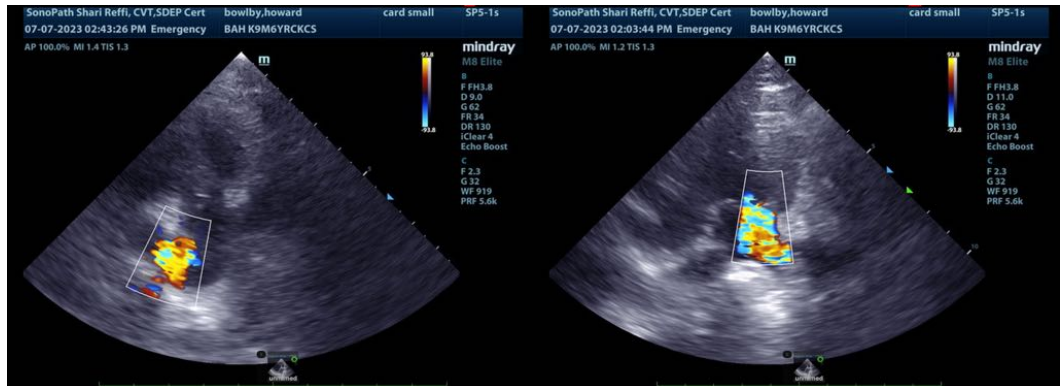
Dr. Lovell

INVOICE

75981

DATE

7/7/23





PATIENT

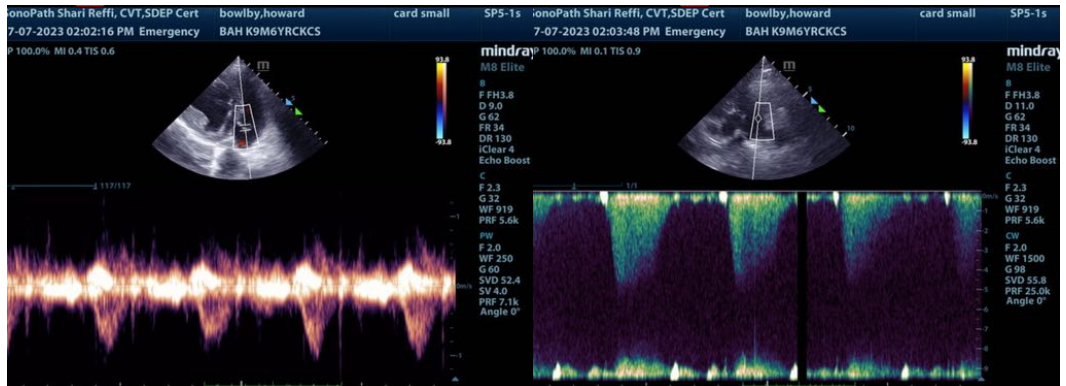
Howard Bowlby

SPECIES

Canine

BREED

King Charles Cavalier



SEX

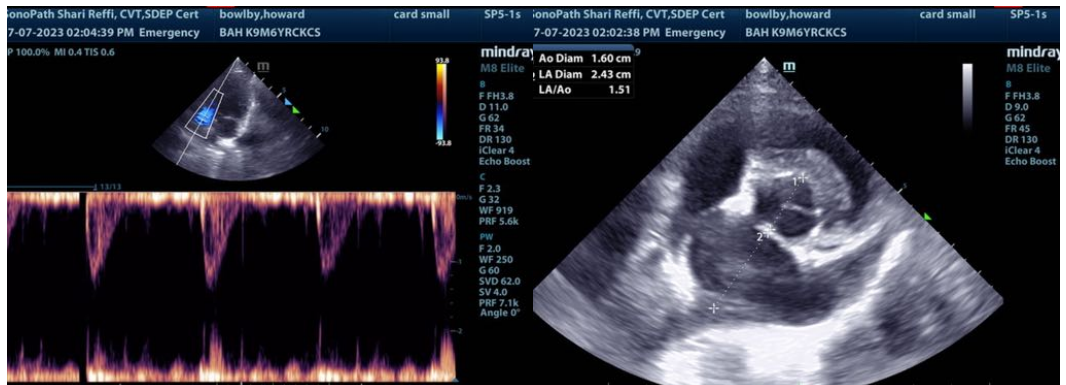
Male

AGE

6 years

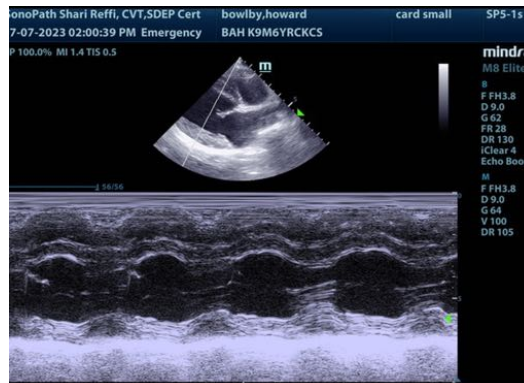
WEIGHT

24 lbs



INTERPRETED BY

Eric Lindquist, DMV
DABVP, Cert. IVUSS



IMAGING PERFORMED BY

Shari Reffi CVT

HOSPITAL NAME

Sonopath Imaging Center

REFERRING VET

Dr. Lovell

INVOICE

75981

DATE

7/7/23

The information and recommendations provided are based on the images presented by the referring veterinarian/sonographer. No evaluation can be communicated regarding pathology that was not visible in the image/video clips provided.

Thank you for this referral. If the clinical or image interpretation does not parallel your findings or if I can be of any further assistance please contact me.

Eric Lindquist, DMV, DABVP, Cert. IVUSS, CEO of SonoPath.com
info@SonoPath.com