



PATIENT

Chewy Cano

PRESENTING CLINICAL SIGNS

History: decreased appetite, vomiting, urinary accidents Painful in abdomen, mass mid abdomen on rad.

SPECIES

Canine

ULTRASONOGRAPHIC EXAMINATION OF THE ABDOMEN

Urinary System

BREED

Terrier Mix

The **urinary bladder**, trigone, and pelvic urethra presented normal thicknesses and normal tone. The ureters were not visible which is normal. No uroliths or sediment were visualized and anechoic urine was present. No evidence of inflammatory or neoplastic changes was noted. Ureteral papillae were normal.

SEX

Neutered male

The residual prostate measured 0.7 cm.

AGE

11 years

The **kidneys** revealed normal size and structure, corticomedullary definition and ratio for this age. The cortices presented largely uniform texture with normal echogenic relationship to liver and spleen. Medullary structure differed distinctly from the cortex and no evidence of pelvic dilation was present. The capsules were acceptably uniform without significant irregularities. The left kidney measured 5.7 cm. The right kidney measured 5.6 cm.

WEIGHT

33 lbs

Adrenal Glands

Both **adrenal glands** were visualized and recognized as having normal shape, size, position and echogenicity for this breed. The phrenic vasculature, glandular echogenicity and detail were unremarkable. Capsule, cortex, and medullary definition were normal for this age patient. The left adrenal gland measured 2.27 x 0.44 cm at the cranial pole and 0.51 cm at the caudal pole. The right adrenal gland measured 2.18 x 0.45 cm.

INTERPRETED BY

Eric Lindquist, DMV
DABVP, Cert. IVUSS

IMAGING PERFORMED BY

Dr. Ken Leal

Spleen

The **spleen** in this patient was mildly enlarged with uniform parenchyma and was folded upon itself at the cranial pole. This is a positional variant and is not pathological. There was no evidence of significant disease.

HOSPITAL NAME

All Creatures Great
and Small

Liver

The **liver** images submitted revealed subjectively normal liver size, contour, and structure. Parenchymal echogenicity was naturally coarse and hypoechoic to the spleen. Vascular and biliary tracts were of normal volume with no evidence of congestion. The gallbladder presented acceptably thin walls with primarily anechoic content. The cystic and common bile ducts were normal. No pathological hepatic lymphadenopathy was evident. No overt structural evidence of inflammatory, infiltrative or regenerative pathology was evident.

REFERRING VET

Dr. Ashmore

INVOICE

76311

DATE

7/31/23



PATIENT

Chewy Cano

SPECIES

Canine

BREED

Terrier Mix

SEX

Neutered male

AGE

11 years

WEIGHT

33 lbs

INTERPRETED BY

Eric Lindquist, DMV
DABVP, Cert. IVUSS

IMAGING PERFORMED BY

Dr. Ken Leal

HOSPITAL NAME

All Creatures Great
and Small

REFERRING VET

Dr. Ashmore

INVOICE

76311

DATE

7/31/23

Gastrointestinal

The **gastrointestinal tract** revealed a mildly thickened gastric wall. There was some echogenic remodeling noted with hyperechoic mucosal inclusion noted. This is suspicious for ulcerative disease. The small intestines and colon were unremarkable.

Pancreas

The base and limbs of the **pancreas** were observed to be largely isoechoic to surrounding omental fat. Pancreatic duct and capsular contour were acceptably normal and parenchyma respected normal curvilinear patterns. No overt evidence of active inflammatory or neoplastic disease was noted.

ULTRASONOGRAPHIC FINDINGS

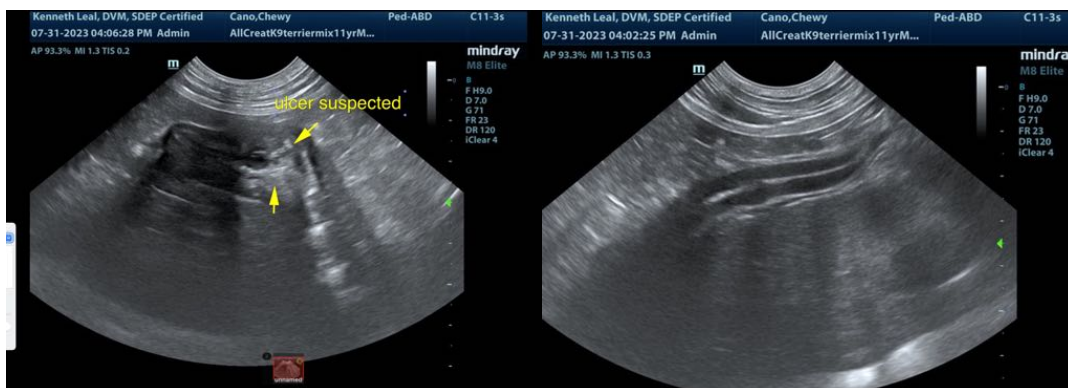
Suspect ulcerative gastritis.

INTERPRETATION OF THE FINDINGS & FURTHER RECOMMENDATIONS

GI protectant protocol is warranted. No overt masses were noted. However, the spleen was folded upon itself and created a mass effect, which is a benign variant.

Helicobacter/Gastritis protocol

A clinical trial of **Zithromax (Dogs: 5-10 mg/kg p.o. q24h. May increase dosing interval to q48h after 3-5 days of treatment)**, **Metronidazole (10-20 mg/kg p.o. b.i.d.)**, **Pepcid (0.5-1 mg/kg s.i.d.)** and **Sucralfate (0.5-2 g/dog PO)** or **Omeprazole (1 mg/kg p.o. s.i.d.)** over the next 3 weeks along with a **novel-protein or hydrolyzed diet** with slurry feeding b.i.d./t.i.d. over the next 2-4 days and then increase to canned diet bid. Dry food should be avoided over the next 4 weeks. A recheck sonogram to assess GI improvement or progression would be ideal in 10 days.





PATIENT

Chewy Cano

SPECIES

Canine

BREED

Terrier Mix

SEX

Neutered male

AGE

11 years

WEIGHT

33 lbs

INTERPRETED BY

Eric Lindquist, DMV
DABVP, Cert. IVUSS

IMAGING PERFORMED BY

Dr. Ken Leal

HOSPITAL NAME

All Creatures Great
and Small

REFERRING VET

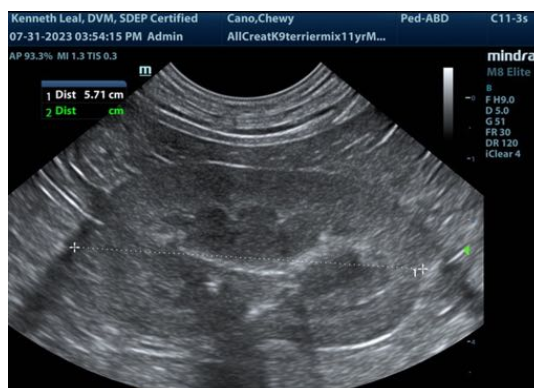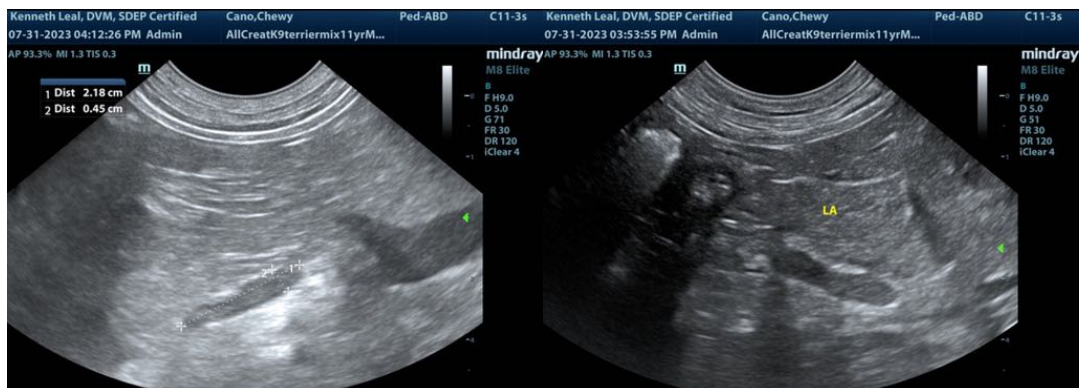
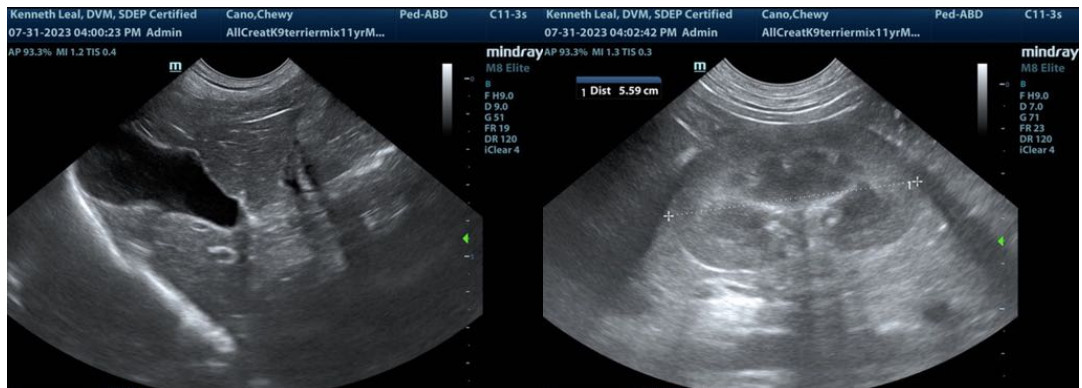
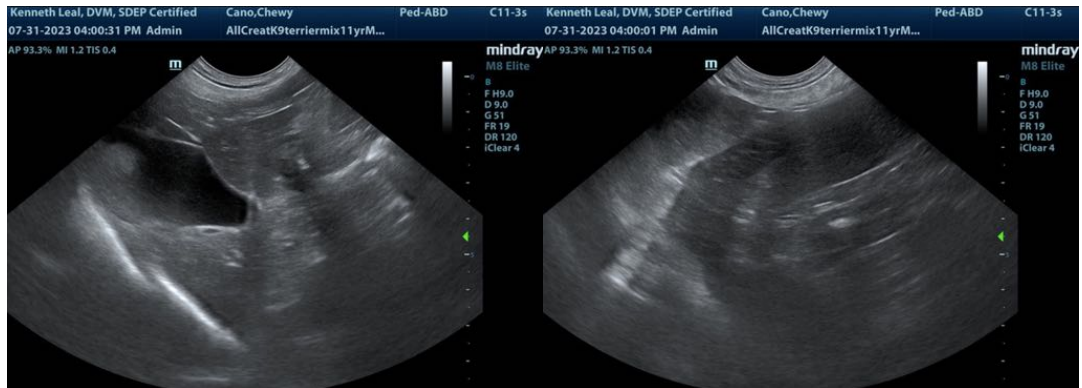
Dr. Ashmore

INVOICE

76311

DATE

7/31/23





PATIENT

Chewy Cano

The information and recommendations provided are based on the images presented by the referring veterinarian/sonographer. No evaluation can be communicated regarding pathology that was not visible in the image/video clips provided.

SPECIES

Canine

Thank you for this referral. If the clinical or image interpretation does not parallel your findings or if I can be of any further assistance please contact me.

BREED

Terrier Mix

Eric Lindquist, DMV, DABVP, Cert. IVUSS, CEO of SonoPath.com
info@SonoPath.com

SEX

Neutered male

AGE

11 years

WEIGHT

33 lbs

INTERPRETED BY

Eric Lindquist, DMV
DABVP, Cert. IVUSS

**IMAGING
PERFORMED BY**

Dr. Ken Leal

HOSPITAL NAME

All Creatures Great
and Small

REFERRING VET

Dr. Ashmore

INVOICE

76311

DATE

7/31/23