



**PATIENT**

Pepper Galderisi

**PRESENTING CLINICAL SIGNS**

History: R/O Adrenal disease. No current meds.  
Abnormal PE/Chem/CBC/UA Results: NA

**SPECIES**

Mustelidae

**ULTRASONOGRAPHIC EXAMINATION OF THE ABDOMEN**  
**Urinary System**

**BREED**

Ferret

The **urinary bladder**, trigone, and pelvic urethra presented normal thicknesses and normal tone. The ureters were not visible which is normal. No uroliths or sediment were visualized and anechoic urine was present. No evidence of inflammatory or neoplastic changes was noted. Ureteral papillae were normal.

**SEX**

Neutered male

The **kidneys** revealed normal size and structure, corticomedullary definition and ratio for this age. The cortices presented largely uniform texture with normal echogenic relationship to liver and spleen. Medullary structure differed distinctly from the cortex and no evidence of pelvic dilation was present. The capsules were acceptably uniform without significant irregularities. The right kidney measured 3.0 cm. The left kidney measured 2.75 cm.

**AGE**

1 years

**Adrenal Glands**

**WEIGHT**

Both **adrenal glands** were visualized and recognized as having normal shape, size, position and echogenicity for this breed. The phrenic vasculature, glandular echogenicity and detail were unremarkable. Capsule, cortex, and medullary definition were normal for this age patient. The left adrenal gland measured 0.4 cm.

**INTERPRETED BY**

Eric Lindquist, DMV  
DABVP, Cert. IVUSS

**Spleen**

**IMAGING PERFORMED BY**

Shari Reffi CVT

The **spleen** in this patient was mildly enlarged with uniform parenchyma and was folded upon itself with slight scalloping contour. This is a positional variant and is not pathological. There was no evidence of significant disease.

**HOSPITAL NAME**

Andover AH

**Liver**

**REFERRING VET**

Dr. Hummel

The **liver** images submitted revealed subjectively normal liver size, contour, and structure. Parenchymal echogenicity was naturally coarse and hypoechoic to the spleen. Vascular and biliary tracts were of normal volume with no evidence of congestion. The gallbladder presented acceptably thin walls with primarily anechoic content. The cystic and common bile ducts were normal. No pathological hepatic lymphadenopathy was evident. No overt structural evidence of inflammatory, infiltrative or regenerative pathology was evident.

**INVOICE**

76277

**Gastrointestinal**

**DATE**

7/11/23

There was some residual chyme and gas was noted in the **stomach**, yet not pathological. This is consistent with end post prandial presentation. Transit of chyme into the small intestine was normal. Curvilinear patterns were maintained throughout the GI tract. No evidence of pathology. Small and



**PATIENT**

Pepper Galderisi

large intestine demonstrated normal luminal chyme and stool consistency respectively. No obstructive or overt infiltrative disease was noted. No associated abnormal lymphatic activity was noted.

**SPECIES**

Mustelidae

**Pancreas**

The base and limbs of the **pancreas** were observed to be largely isoechoic to surrounding omental fat. Pancreatic duct and capsular contour were acceptably normal and parenchyma respected normal curvilinear patterns. No overt evidence of active inflammatory or neoplastic disease was noted.

**BREED**

Ferret

**Free Abdomen**

**SEX**

Neutered male

The iliac lymph nodes are reactive and measured 2.27 x 0.52 cm. The sublumbar lymph node was rounded and measured 0.66 cm.

**AGE**

1 years

**ULTRASONOGRAPHIC FINDINGS**

Normal abdomen with full stomach, most consistent with a post prandial presentation. Reactive spleen and lymph nodes, essentially normal for this species.

**WEIGHT**

**INTERPRETATION OF THE FINDINGS & FURTHER RECOMMENDATIONS**

I cannot rule out soft foreign matter. There was no evidence of pathology.

**INTERPRETED BY**

Eric Lindquist, DMV  
DABVP, Cert. IVUSS

**IMAGING PERFORMED BY**

Shari Reffi CVT

**HOSPITAL NAME**

Andover AH

**REFERRING VET**

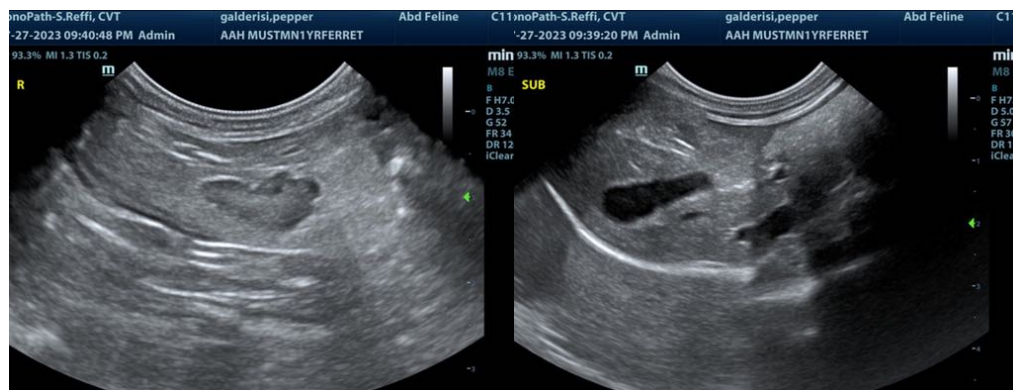
Dr. Hummel

**INVOICE**

76277

**DATE**

7/11/23





**PATIENT**

Pepper Galderisi

**SPECIES**

Mustelidae

**BREED**

Ferret

**SEX**

Neutered male

**AGE**

1 years

**WEIGHT**

**INTERPRETED BY**

Eric Lindquist, DMV  
DABVP, Cert. IVUSS

**IMAGING PERFORMED BY**

Shari Reffi CVT

**HOSPITAL NAME**

Andover AH

**REFERRING VET**

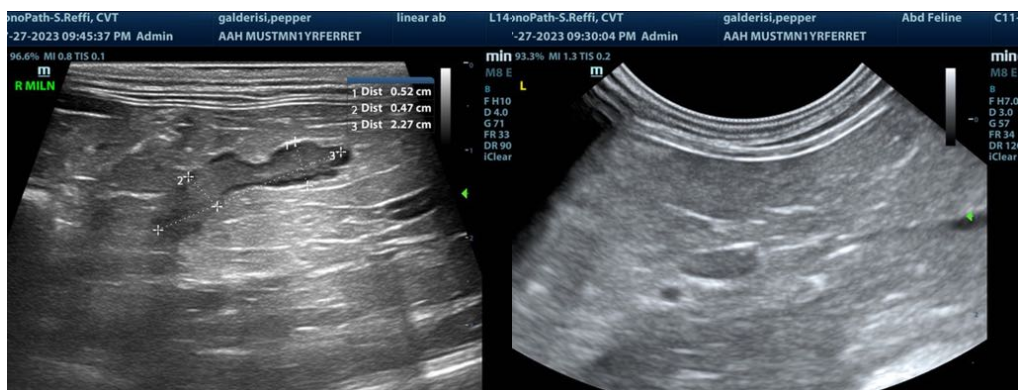
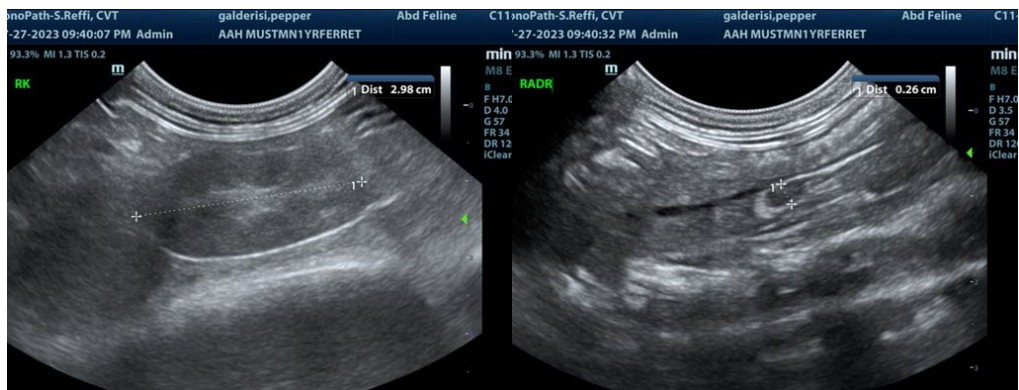
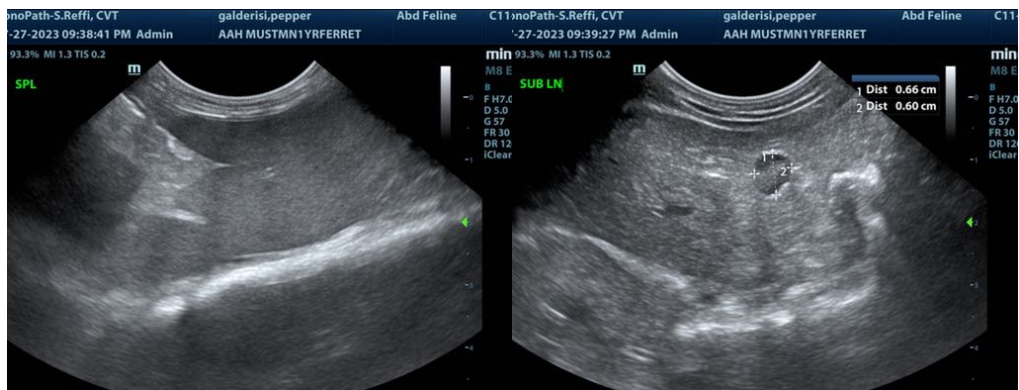
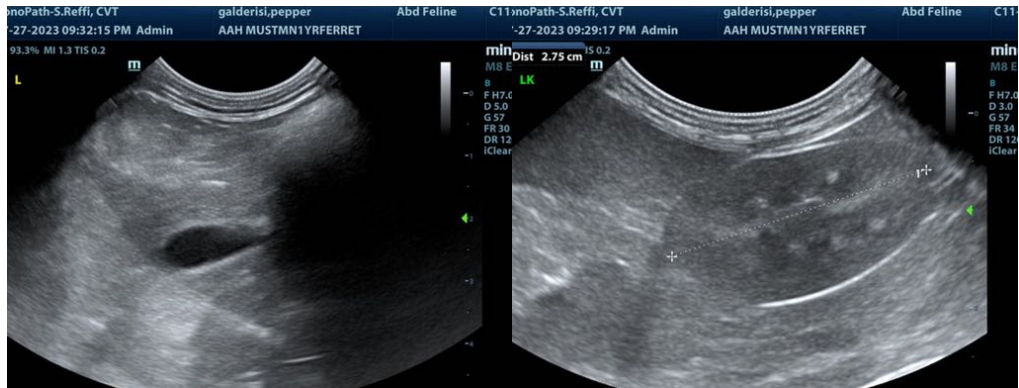
Dr. Hummel

**INVOICE**

76277

**DATE**

7/11/23





**PATIENT**

Pepper Galderisi

The information and recommendations provided are based on the images presented by the referring veterinarian/sonographer. No evaluation can be communicated regarding pathology that was not visible in the image/video clips provided.

**SPECIES**

Mustelidae

Thank you for this referral. If the clinical or image interpretation does not parallel your findings or if I can be of any further assistance please contact me.

**BREED**

Ferret

**Eric Lindquist**, DMV, DABVP, Cert. IVUSS, CEO of SonoPath.com  
info@SonoPath.com

**SEX**

Neutered male

**AGE**

1 years

**WEIGHT**

**INTERPRETED BY**

Eric Lindquist, DMV  
DABVP, Cert. IVUSS

**IMAGING  
PERFORMED BY**

Shari Reffi CVT

**HOSPITAL NAME**

Andover AH

**REFERRING VET**

Dr. Hummel

**INVOICE**

76277

**DATE**

7/11/23