

PATIENT

Fiona Maine Coon Only
Rescue

SPECIES

Feline

BREED

Domestic Longhair

SEX

Spayed female

AGE

7 years

WEIGHT

3.8 lbs

INTERPRETED BY

Eric Lindquist, DMV
DABVP, Cert. IVUSS

IMAGING PERFORMED BY

Dr. Leal

HOSPITAL NAME

Dr. T's Vet Care

REFERRING VET

Dr. Turk

INVOICE

76282

DATE

7/26/23

PRESENTING CLINICAL SIGNS

History: Cat presented severe weight loss and diarrhea. Difficult to handle. A rescue cat.
Abnormal PE/Chem/CBC/UA Results: blood shows albumin - 2.4 CPK = 1516 WBC = 17.5

ULTRASONOGRAPHIC EXAMINATION OF THE ABDOMEN

Urinary System

The **urinary bladder**, trigone, and pelvic urethra presented normal thicknesses and normal tone. The ureters were not visible which is normal. No uroliths or sediment were visualized and anechoic urine was present. No evidence of inflammatory or neoplastic changes was noted. Ureteral papillae were normal.

The **kidneys** revealed normal size and structure, corticomedullary definition and ratio for this age. The cortices presented largely uniform texture with normal echogenic relationship to liver and spleen. Medullary structure differed distinctly from the cortex and no evidence of pelvic dilation was present. The capsules were acceptably uniform without significant irregularities. The left kidney measured 3.18 cm. The right kidney measured 2.84 cm.

Adrenal Glands

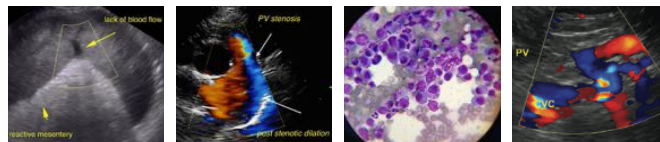
Both **adrenal glands** were visualized and recognized as having normal shape, size, position and echogenicity for this breed. The phrenic vasculature, glandular echogenicity and detail were unremarkable. Capsule, cortex, and medullary definition were normal for this age patient. The left adrenal gland measured 0.6 x 0.4 cm. The right adrenal gland measured 2.0 x 0.5 cm.

Spleen

The **spleen** presented a smooth homogeneous parenchyma hyperechoic to liver and renal cortical parenchyma. The capsule was smooth without noticeable expansion or deviation from within the spleen or adjacent pathology. The splenic vasculature demonstrated normal volume without signs of congestion or thrombosis. No sonographic evidence of acute or chronic inflammatory, neoplastic, or infarctual changes was noted.

Liver

The **liver** images submitted revealed subjectively normal liver size, contour, and structure. Parenchymal echogenicity was naturally coarse and hypoechoic to the spleen. Vascular and biliary tracts were of normal volume with no evidence of congestion. The gallbladder presented acceptably thin walls with primarily anechoic content. The cystic and common bile ducts were normal. No pathological hepatic lymphadenopathy was evident. No overt structural evidence of inflammatory, infiltrative or regenerative pathology was evident.



PATIENT

Fiona Maine Coon Only
Rescue

SPECIES

Feline

BREED

Domestic Longhair

SEX

Spayed female

AGE

7 years

WEIGHT

3.8 lbs

INTERPRETED BY

Eric Lindquist, DMV
DABVP, Cert. IVUSS

IMAGING PERFORMED BY

Dr. Leal

HOSPITAL NAME

Dr. T's Vet Care

REFERRING VET

Dr. Turk

INVOICE

76282

DATE

7/26/23

Gastrointestinal

Examination of the **gastrointestinal tract** revealed a stomach free of stasis, of normal wall thickness, acceptable curvilinear mural detail, and peristaltic activity. Minor intestinal thickening was noted. . Soft stool was noted in the colon.

Pancreas

The base and limbs of the **pancreas** were observed to be largely isoechoic to surrounding omental fat. Minor pancreatic duct dilation was noted.

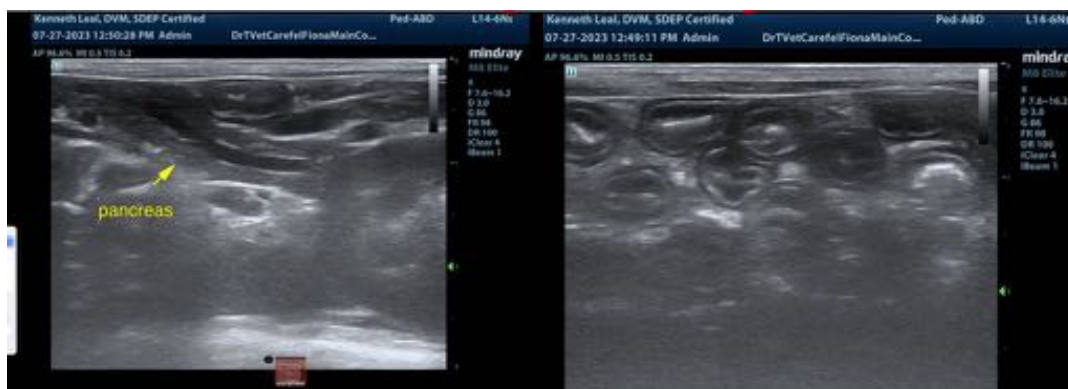
ULTRASONOGRAPHIC FINDINGS

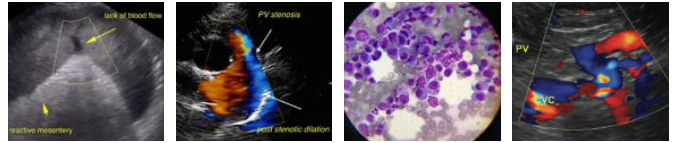
Structurally **unremarkable** abdomen.

INTERPRETATION OF THE FINDINGS & FURTHER RECOMMENDATIONS

Differentials for diarrhea include occult parasitism. Dietary indiscretion, dietary intolerance, antibiotic responsive colitis, intestinal dysbiosis and occult Addison's should all be considered as causes of diarrhea in this patient. A hydrolyzed diet trial may be in this patient's best interest +/- probiotics. 24-hour NPO and reintroduction of bland diet indicated. I recommend a baseline cortisol or ACTH stimulation test, a fresh fecal smear and fecal floatation analysis if not already performed.

Maldigestion panel, three view chest radiographs and full CNS examination is recommended to examine for occult disease that could be responsible for the weight loss. Evaluation for competitive eating environments should also be considered.





PATIENT

Fiona Maine Coon Only
Rescue

SPECIES

Feline

BREED

Domestic Longhair

SEX

Spayed female

AGE

7 years

WEIGHT

3.8 lbs

INTERPRETED BY

Eric Lindquist, DMV
DABVP, Cert. IVUS

IMAGING PERFORMED BY

Dr. Leal

HOSPITAL NAME

Dr. T's Vet Care

REFERRING VET

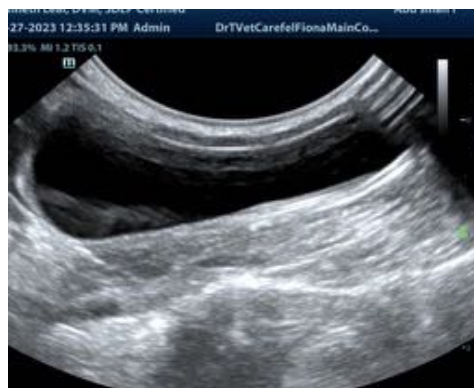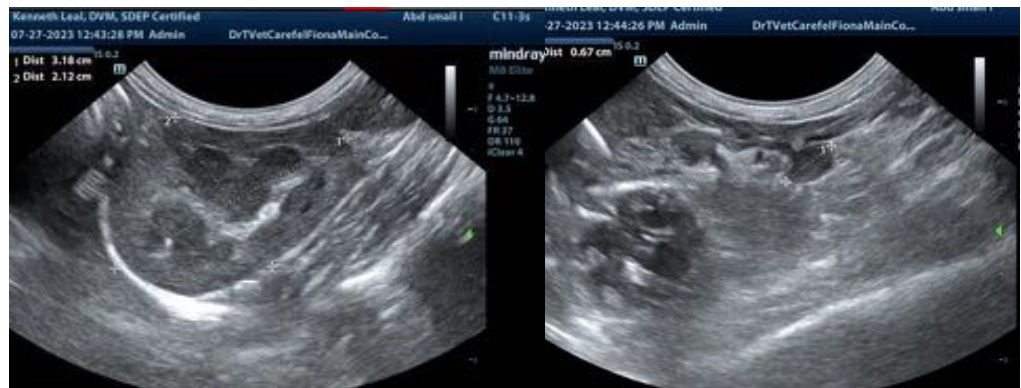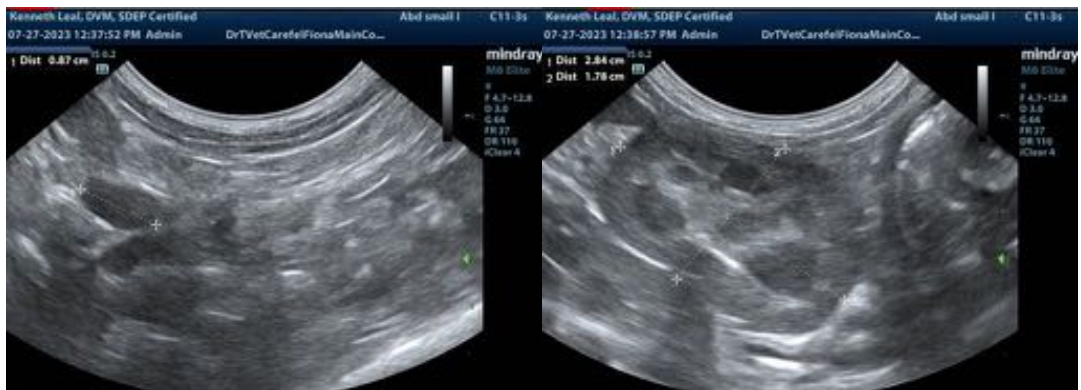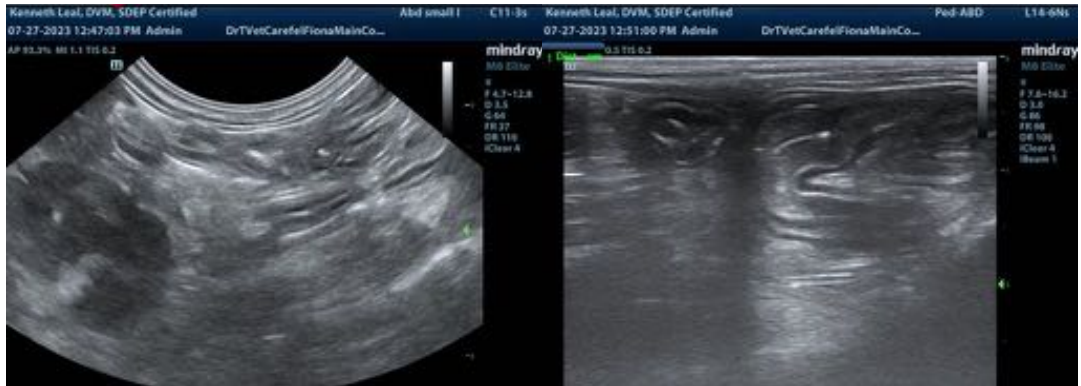Dr. Turk

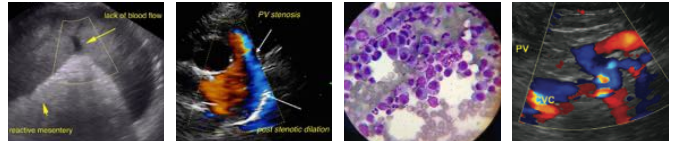
INVOICE

76282

DATE

7/26/23





PATIENT

Fiona Maine Coon Only
Rescue

The information and recommendations provided are based on the images presented by the referring veterinarian/sonographer. No evaluation can be communicated regarding pathology that was not visible in the image/video clips provided.

SPECIES

Feline

Thank you for this referral. If the clinical or image interpretation does not parallel your findings or if I can be of any further assistance please contact me.

BREED

Domestic Longhair

Eric Lindquist, DMV, DABVP, Cert. IVUSS, CEO of SonoPath.com
info@SonoPath.com

SEX

Spayed female

AGE

7 years

WEIGHT

3.8 lbs

INTERPRETED BY

Eric Lindquist, DMV
DABVP, Cert. IVUSS

**IMAGING
PERFORMED BY**

Dr. Leal

HOSPITAL NAME

Dr. T's Vet Care

REFERRING VET

Dr. Turk

INVOICE

76282

DATE

7/26/23