



PATIENT

Teddy Bear Zhang
Animal

SPECIES

Canine

BREED

Goldendoodle

SEX

Neutered male

AGE

10 years

WEIGHT

55.2 lbs

INTERPRETED BY

Eric Lindquist, DMV
DABVP, Cert. IVUSS

IMAGING PERFORMED BY

Shari Reffi CVT

HOSPITAL NAME

Animal General on
Hudson

REFERRING VET

Dr. Hudson

INVOICE

76246

DATE

7/26/23

PRESENTING CLINICAL SIGNS

History: Parathyroid mass-Parathyroidectomy on 4/2023. Current Meds: Calcitriol, Levothyroxine.

ULTRASONOGRAPHIC EXAMINATION OF THE ABDOMEN

Urinary System

The **urinary bladder**, trigone, and pelvic urethra presented normal thicknesses and normal tone. The ureters were not visible which is normal. No uroliths or sediment were visualized and anechoic urine was present. No evidence of inflammatory or neoplastic changes was noted. Ureteral papillae were normal.

The residual prostate was uniform and measured 1.08 cm.

The **kidneys** revealed largely normal size and structure, corticomedullary definition and ratio (cortex 1/3 of medulla) were essentially maintained with some age-related loss of curvilinear patterns regarding the capsule and C/M junction. The cortices presented largely uniform texture with some increased echogenicity expected for his age patient. Medullary structure differed distinctly from that of the cortex and no evidence of pelvic dilation was present. The right kidney measured 6.31 cm. The left kidney measured 6.28 cm.

Adrenal Glands

Both **adrenal glands** were visualized and recognized as having normal shape, size, position and echogenicity for this breed. The phrenic vasculature, glandular echogenicity and detail were unremarkable. Capsule, cortex, and medullary definition were normal for this age patient. The left adrenal gland measured 2.18 x 0.43 cm at the cranial pole and 0.42 cm at the caudal pole.

Spleen

The **spleen** was largely smooth with subtle heterogeneous parenchymal changes while maintaining normal echogenic relationship to the liver and kidney. These changes are consistent with normal age-related alteration. Subtle, hypoechoic, non-disruptive nodular changes were noted in the spleen. This is most consistent with hyperplasia. The capsule was smooth without noticeable impingement from within the spleen or from pathology in the adjacent abdomen. The splenic vasculature demonstrated normal volume without signs of congestion or significant contraction. No evidence of active acute or chronic inflammatory, neoplastic, or infarctual changes was noted.

Liver

The **liver** images submitted revealed subjectively normal liver size, contour, and structure. Parenchymal echogenicity was naturally coarse and hypoechoic to the spleen. Vascular and biliary tracts were of normal volume with no evidence of congestion. The gallbladder presented acceptably thin walls with primarily anechoic content. The cystic and common bile ducts were normal. No pathological hepatic lymphadenopathy was evident. No overt structural evidence of inflammatory, infiltrative or regenerative pathology was evident.



PATIENT

Teddy Bear Zhang
Animal

SPECIES

Canine

BREED

Goldendoodle

SEX

Neutered male

AGE

10 years

WEIGHT

55.2 lbs

INTERPRETED BY

Eric Lindquist, DMV
DABVP, Cert. IVUSS

IMAGING PERFORMED BY

Shari Reffi CVT

HOSPITAL NAME

Animal General on
Hudson

REFERRING VET

Dr. Hudson

INVOICE

76246

DATE

7/26/23

Gastrointestinal

Examination of the **gastrointestinal tract** revealed a stomach and intestine free of stasis, of normal wall thickness, acceptable curvilinear mural detail, and peristaltic activity. Small and large intestine demonstrated normal luminal chyme and stool consistency respectively. No obstructive or overt infiltrative disease was noted. No associated abnormal lymphatic activity was noted.

Pancreas

The base and limbs of the **pancreas** were observed to be largely isoechoic to surrounding omental fat. Pancreatic duct and capsular contour were acceptably normal and parenchyma respected normal curvilinear patterns. No overt evidence of active inflammatory or neoplastic disease was noted.

Cervical Ultrasound

A cervical scan was performed. The esophagus, trachea and regional tissues were unremarkable. There was no evidence of pathology. The left thyroid lobe was uniform yet revealed no evidence of pathology and measured 0.4 cm in width. There was no return of the prior pathology noted. The right thyroid lobe was uniform with no evidence of pathology.

Heart

Rapid view of the heart revealed no evidence of pathology.

ULTRASONOGRAPHIC FINDINGS

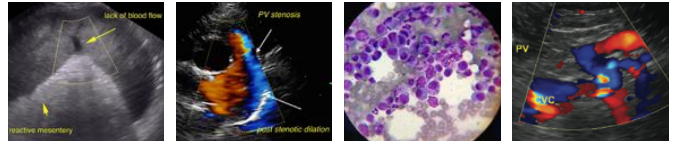
Normal cervical scan, no evidence of pathology.

Normal abdomen.

Micronodular hyperplasia splenic pattern.

INTERPRETATION OF THE FINDINGS & FURTHER RECOMMENDATIONS

If any weight loss is an issue then FNA is indicated; however, this is most consistent with hyperplasia and minor, age related changes.



PATIENT

Teddy Bear Zhang
Animal

SPECIES

Canine

BREED

Goldendoodle

SEX

Neutered male

AGE

10 years

WEIGHT

55.2 lbs

INTERPRETED BY

Eric Lindquist, DMV
DABVP, Cert. IVUSS

IMAGING PERFORMED BY

Shari Reffi CVT

HOSPITAL NAME

Animal General on
Hudson

REFERRING VET

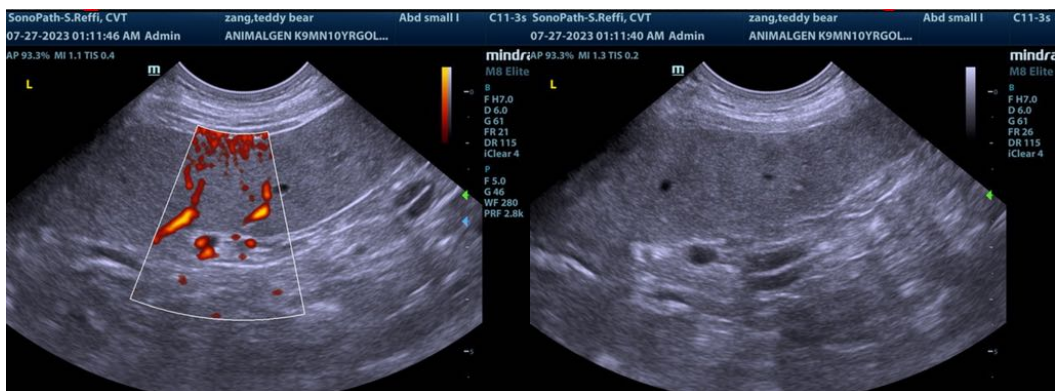
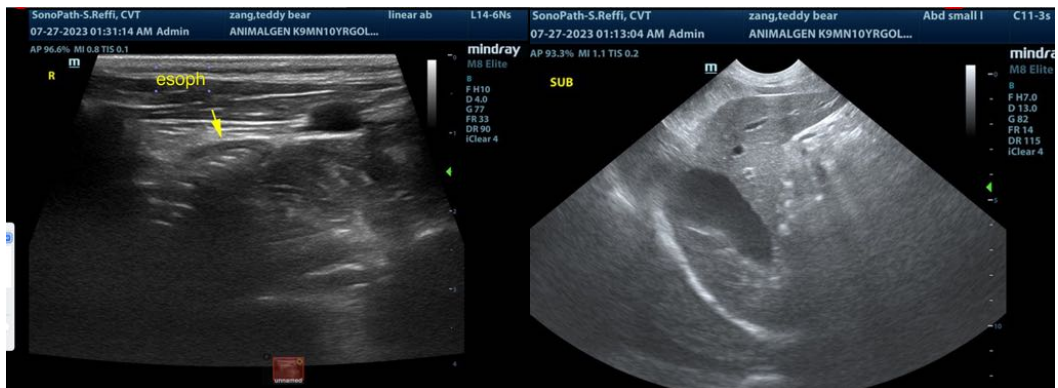
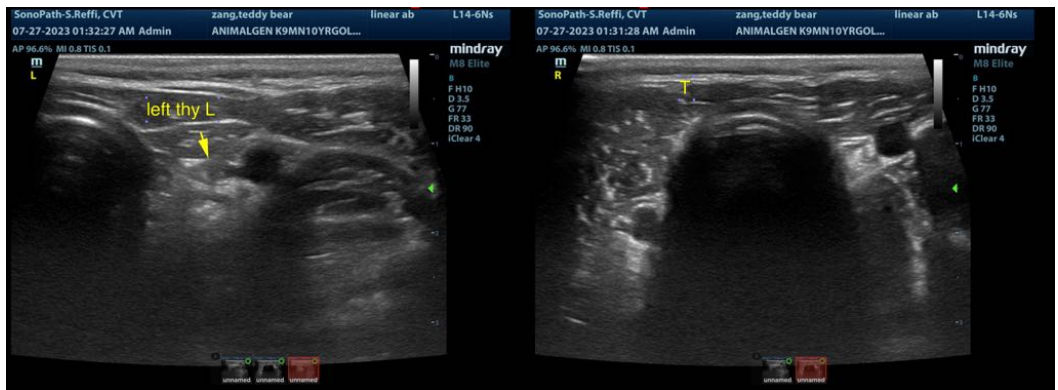
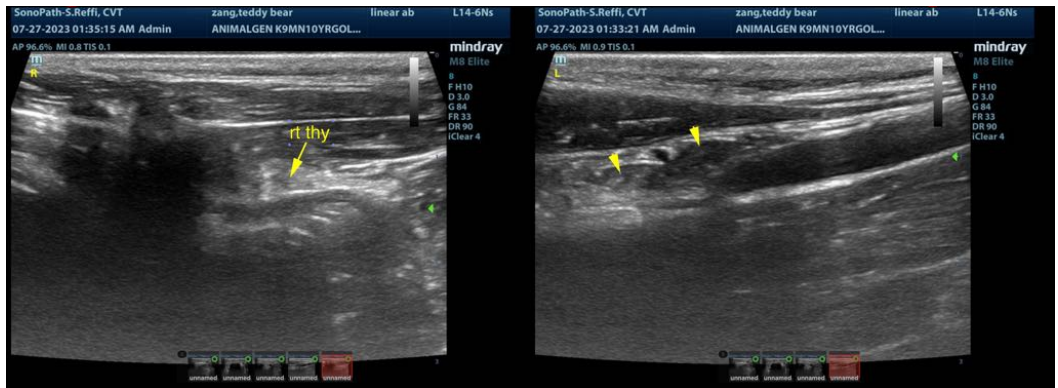
Dr. Hudson

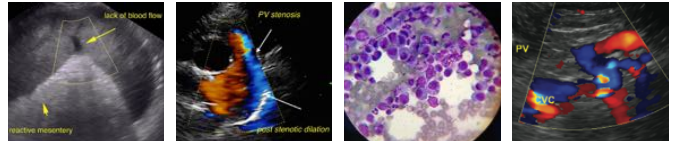
INVOICE

76246

DATE

7/26/23





PATIENT

Teddy Bear Zhang
Animal

SPECIES

Canine

BREED

Goldendoodle

SEX

Neutered male

AGE

10 years

WEIGHT

55.2 lbs

INTERPRETED BY

Eric Lindquist, DMV
DABVP, Cert. IVUSS

IMAGING PERFORMED BY

Shari Reffi CVT

HOSPITAL NAME

Animal General on
Hudson

REFERRING VET

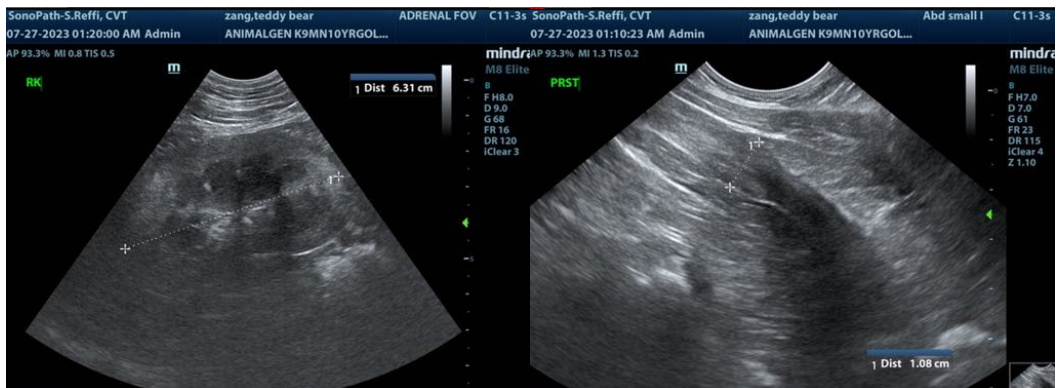
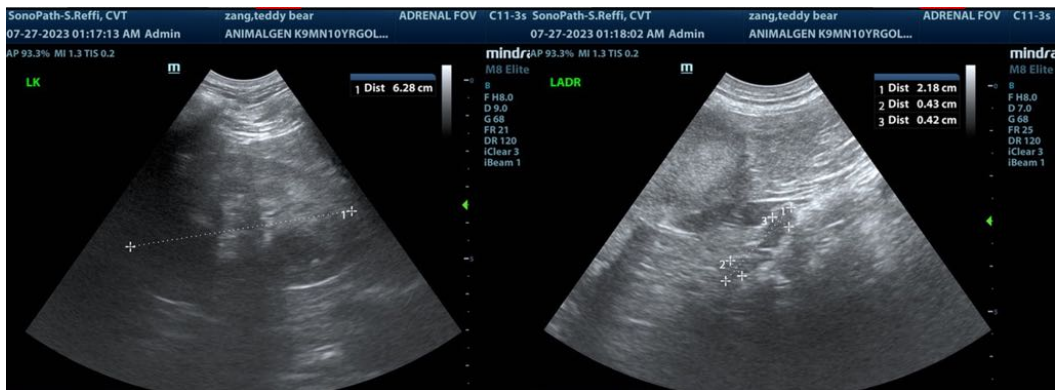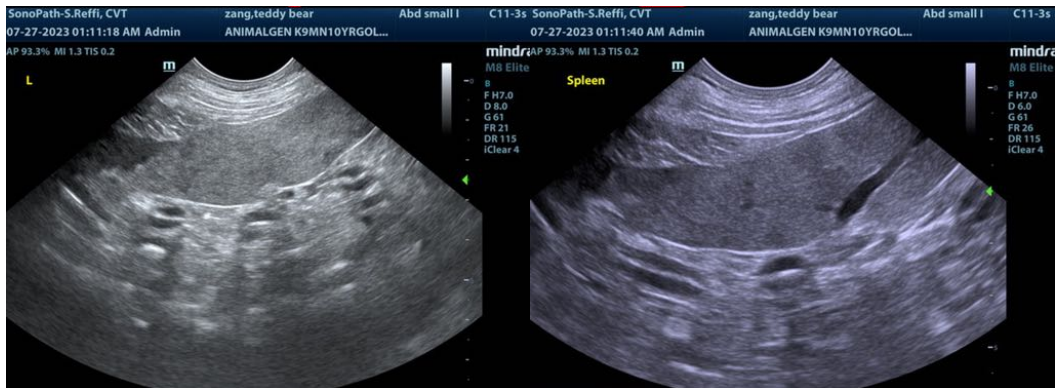
Dr. Hudson

INVOICE

76246

DATE

7/26/23



The information and recommendations provided are based on the images presented by the referring veterinarian/sonographer. No evaluation can be communicated regarding pathology that was not visible in the image/video clips provided.

Thank you for this referral. If the clinical or image interpretation does not parallel your findings or if I can be of any further assistance please contact me.

Eric Lindquist, DMV, DABVP, Cert. IVUSS, CEO of SonoPath.com
info@SonoPath.com