
**PATIENT PRESENTING CLINICAL SIGNS**

Sidekick Ferrante

History: 4/6 murmur; coughing, trouble breathing. On lasix 12.5mg x 2 bid (recent increase in dose), doxycycline 50 mg bid

**SPECIES**

Canine

**ULTRASONOGRAPHIC EXAMINATION OF THE HEART**
**BREED**

King Charles Spaniel

The echocardiogram in this patient presented with significant volume overload in all four chambers with prolapse of the anterior mitral valve leaflet. Mitral and tricuspid insufficiency was noted and considered moderate. There was pulmonary hypertension and complete filling of the right and left atrium noted on color flow Doppler of the mitral and tricuspid valves. Pulmonic and aortic insufficiency is present. Contractility was subnormal consistent with myocardial insufficiency. B lines were noted in the extracardiac space. This is consistent with pulmonary edema. Ascites was noted with hepatic vein dilation.

**SEX**

Intact male

**AGE**

11 years

**WEIGHT**

29 lbs

CANINE CARDIAC PARAMETERS	MR VMAX (m/s)	TR VMAX (m/s)	LA/AO (Boon method)	LA/AO (Heart Base; Swe)	FS (%)	EF (%)	EPSS (cm)
NORMAL PARAMETER	4.5-5.5	<2.7	1.3	<1.6	28-40	40-100	<0.6
PATIENT	5.0	3.7	NM	2.32	34	68	NM
CANINE CARDIAC PARAMETERS	HR (BPM)	AV VMAX (m/s)	PV MAX (m/s)	BODY WEIGHT	LA (2D short axis Base view) (cm)	LVIDd (Avg; 2D and m-mode short axis) (cm)	LVIDs (Avg; 2D and m-mode short axis) (cm)
NORMAL PARAMETER	50-100	0.7-1.7	0.7-1.6	BELOW	BELOW	BELOW	BELOW
PATIENT	141	1.0	2.8	29 lbs	4.63 max	4.23	

**INTERPRETED BY**

Eric Lindquist, DMV DABVP, Cert. IVUSS

**IMAGING PERFORMED BY**

Diane McFadden, RVT

**HOSPITAL NAME**

Lake Hopatcong

**REFERRING VET**

Dr. Navarro

**ULTRASONOGRAPHIC FINDINGS**

Left and right sided heart failure.

Stage C1 to D1 valvular disease.

**INVOICE**

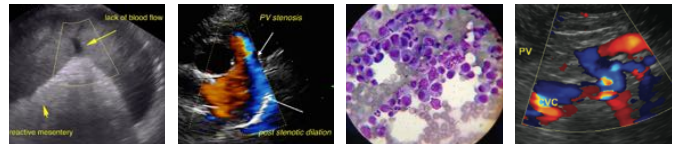
31712

**DATE**

7/5/22

**INTERPRETATION OF THE FINDINGS & FURTHER RECOMMENDATIONS**

I recommend Quadro therapy in this patient. I recommend to continue Lasix at 2-4 mg/kg b.i.d., ace inhibitor at 0.5 mg/kg s.i.d. progressing to b.i.d., Pimobendan at 0.3 mg/kg b.i.d. and Spironolactone at 1-2 mg/kg b.i.d. I recommend reassessing the blood pressure measurements. Target sleeping respiratory rate is less than 25-30/minute. Chest radiographs, BUN, creatinine and urine specific gravity is recommended in 5-7 days. Guarded prognosis. A recheck echocardiogram is recommended in 2 weeks. This patient is at risk for sudden death.



**PATIENT**

Sidekick Ferrante

**SPECIES**

Canine

**BREED**

King Charles Spaniel

**SEX**

Intact male

**AGE**

11 years

**WEIGHT**

29 lbs

**INTERPRETED BY**

Eric Lindquist, DMV  
DABVP, Cert. IVUSS

**IMAGING PERFORMED BY**

Diane McFadden, RVT

**HOSPITAL NAME**

Lake Hopatcong

**REFERRING VET**

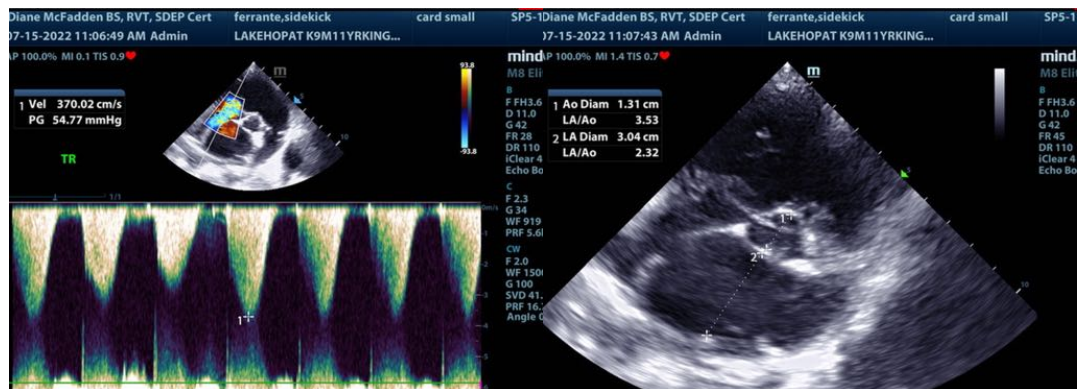
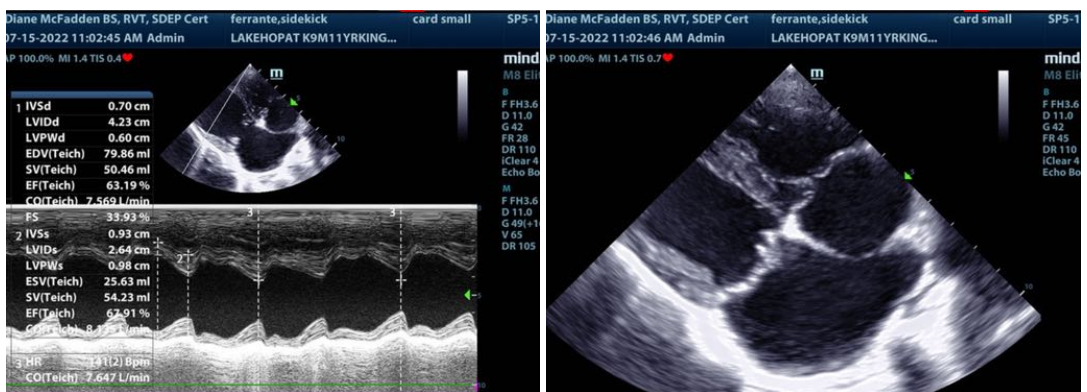
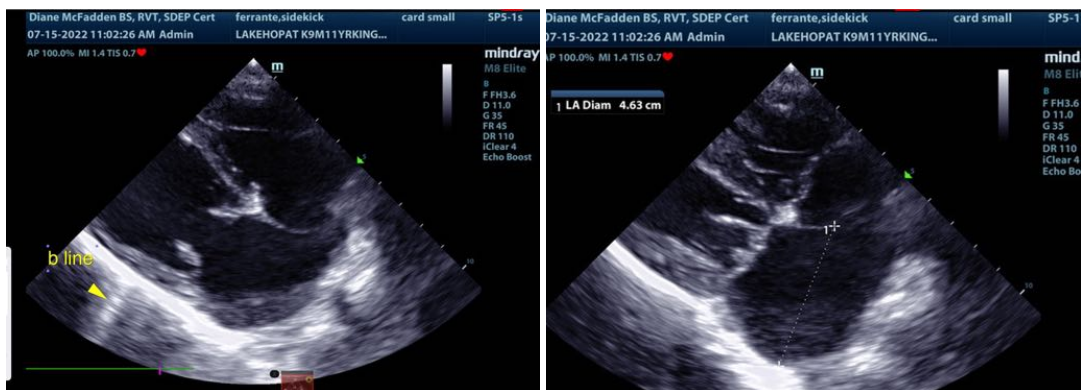
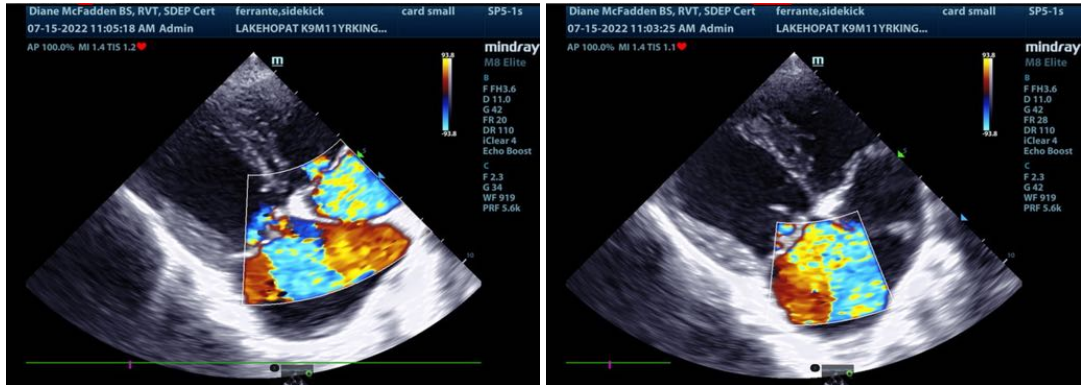
Dr. Navarro

**INVOICE**

31712

**DATE**

7/5/22





**PATIENT**

Sidekick Ferrante

**SPECIES**

Canine

**BREED**

King Charles Spaniel

**SEX**

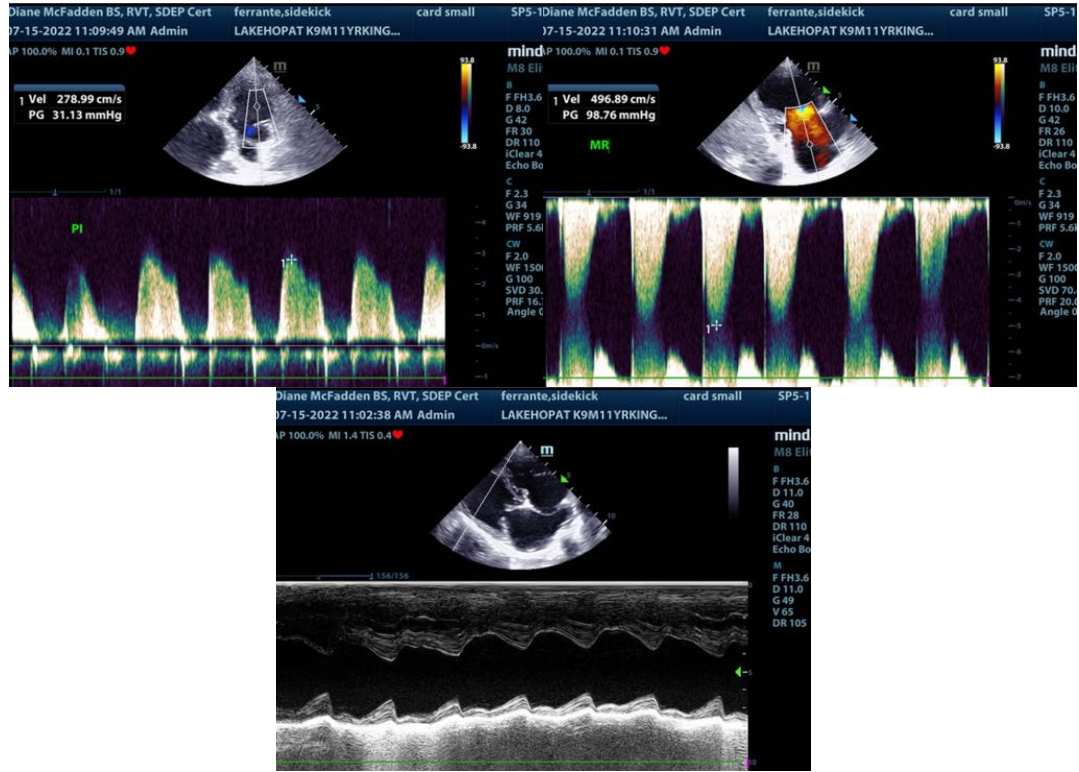
Intact male

**AGE**

11 years

**WEIGHT**

29 lbs



**INTERPRETED BY**

Eric Lindquist, DMV  
DABVP, Cert. IVUSS

The information and recommendations provided are based on the images presented by the referring veterinarian/sonographer. No evaluation can be communicated regarding pathology that was not visible in the image/video clips provided.

**IMAGING PERFORMED BY**

Diane McFadden, RVT

Thank you for this referral. If the clinical or image interpretation does not parallel your findings or if I can be of any further assistance please contact me.

**HOSPITAL NAME**

Lake Hopatcong

**Eric Lindquist, DMV, DABVP, Cert. IVUSS, CEO of SonoPath.com**  
Info@SonoPath.com

**REFERRING VET**

Dr. Navarro

**INVOICE**

31712

**DATE**

7/5/22